

LATERAL TARSALE STRIP TECHNIQUE IN CORRECTION OF EYELID ECTROPION AND ENTROPION

Vydláková J., Tesař J., Krátký V., Šín M., Němec P.

Military University Hospital Prague, Department of Ophthalmology of 1st Faculty of Medicine of the Charles University and the Military University Hospital Prague

The authors of the study declare that no conflict of interests exists in the compilation, theme and subsequent publication of this professional communication, and that it is not supported by any pharmaceuticals company. The study has not been submitted to any other journal or printed elsewhere, with the exception of congress abstracts and recommended procedures.

Received: 3 October 2020

Accepted: 18 January 2021

Available on-line: 1 May 2021



MUDr. Jana Vydláková
Oční klinika 1. LF UK a ÚVN Praha
U Vojenské nemocnice 1200
169 02 Praha 6
E-mail: vydlakova.jana@uvn.cz

SUMMARY

Background: Ectropion and entropion are eyelid malpositions associated with many unpleasant symptoms. One of many surgical methods that can correct these problems is called the lateral tarsal strip. In this paper, we evaluate the postoperative results and quality of this technique. We also looked at the complications associated with this surgical method.

Methods: The study took place from April 2018 to April 2020 at the Military University Hospital in Prague. The operation was performed by two surgeons. The study included 43 eyes of 33 patients (17 women and 16 men), average age was 79 years. Before the operation, 23 eyes had an ectropion and 20 eyes had an entropion, 35 of 43 were cases of involutional origin. The study does not include patients who underwent other surgical techniques.

Results: There were no intraoperative or postoperative complications in the entropion surgery group. Proper correction was achieved, and bothersome symptoms disappeared in 91,3 % of cases. Correct position of eyelid was not achieved in two cases. For patients with ectropion, surgical correction was successful in 95 % of cases. The ectropion persisted after surgery only for one patient.

Conclusion: The lateral tarsal strip technique is safe, reliable and highly effective surgical technique. Correction of eyelid malposition was achieved in more than 90 % of cases. Vast majority of patients were satisfied and reported relief from preoperative symptoms.

Key words: ectropion, entropion, involutional, cicatricial, lateral tarsal strip

Čes. a slov. Oftal., 77, 2021, No.2, p. 73–78

INTRODUCTION

Entropion and ectropion are ophthalmological terms indicating a defect of the positioning of the eyelids. In the case of entropion, this concerns an unusual coiling of the margin of the eyelid (primarily the lower eyelid) and eyelashes in an inward direction, thus against the eyeball [1]. This pathology leads to chronic irritation of the cornea and bulbar conjunctiva, which results in a whole series of unpleasant symptoms. Patients reporting to the surgery of an ophthalmologist most commonly complain of increased lachrymation and reddened or painful eye. They may also describe blurred vision or a feeling of a foreign body in the eye. Neglect of timely treatment frequently leads to the development of corneal vascularisation and superficial keratopathy. In the most severe cases, corneal ulceration to perforation appears [1,2]. Depending on the etiology, we classify entropion into a number of different types – we distinguish between involutional, cicatricial, spastic and congenital entropion [3]. Involutional entropion, i.e. linked to age, is the most commonly represented type of entropion within the population. With incre-

asing age, degeneration of the elastic tissue takes place, with a prolapse of fat in the eyelid. These processes lead to a weakening of the complex of the external lateral ligament, capsulopalpebral fascia, to loss of integrity of the retractors and horizontal laxity of the lower eyelid [1,4]. The complex of all these phenomena culminates in the aforementioned abnormal rotation of the margin. We attempt to suppress these unpleasant symptoms by means of both conservative and surgical treatment. As the first-place treatment we apply lubrication or artificial tears. Another alleviating procedure is the technique of adhesion of eyelids. We perform this adhesion with the aid of strips, the aim of which is to achieve correction of the eyelids. The cornea can be protected simply by the application of contact lenses. In the case of spastic form, an effective but temporary method is injections of botulinum toxin into the lateral preseptal part of the musculus orbicularis oculi. Depending on the laxity of the eyelid, an improvement is achieved in almost 94% of cases for up to 12.5 weeks. However, this therapeutic method is limited in its use due to the financial demand factor of botulinum toxin, and also due to the occurrence of a whole range of

adverse side effects such as diplopia, epiphora and iatrogenically induced ectropion [2]. An advanced approach to achieving relief from unpleasant symptoms is surgical correction of the eyelids. We can induce correction lasting for several months with the aid of auxiliary sutures, by means of the "Quickert suture technique". We use this method primarily on older patients, in whose case we attempt to achieve strengthening of the retractors. The greatest advantage of this technique is its speed and easy implementation. We apply the individual sutures vertically from the internal fornix via the conjunctiva, the preseptal part of the musculus orbicularis oculi and skin approximately 2-3 mm beneath the lower edge of the eyelashes. Another of the large number of used methods is the technique of lower lid retractor insertion, in which we perform dissection of part of the preseptal portion of the musculus orbicularis oculi and capsulopalpebral fascia of the musculus obliquus inferior, with their subsequent connection to the edge of the tarsus. At our clinic, the technique of lateral tarsal strip has become the most popular method due to its speed and virtually perfect anatomical and aesthetic correction. This technique is commenced by inducing anaesthesia of the outer corner of the eye. It continues in canthotomy and cantholysis. After cantholysis, the outer part of the lower eyelid is divided into anterior and posterior lamellas. Abrasion of the conjunctival epithelium and removal of the eyelashes from the posterior lamella causes exposure of a strip of the tarsus, which is truncated to the required length and fixed according to the custom of the operating surgeon by absorbent or non-absorbent suture into the periosteum of the outer part of orbit. An important factor is fixation of the suture to the internal edge of the outer rim of orbit. The reason for this specific fixation is the prevention of protrusion of the eyelid in the temporal part. We select the height of the fixation at 1-2 mm above the level of the inner corner of the eye. The required tension of the eyelids is corrected by tightening the suture. A fundamental measure which decides on the resulting effect of the entire operation is the application of a suture in the outer corner, which must preserve its sharp angle. The final step is resection of excess skin, suture of the musculus orbicularis oculi and closure of the skin incision [1,5,6,7].

Cicatricial entropion is the second most common type within the population. Scarring of the conjunctiva and truncation of the posterior lamella of the eyelid occurs primarily due to the influence of external factors, which are: injuries (burns, chemical burns), inflammations (trachoma, herpes), Stevens-Johnson syndrome, pemphigoid, radiation therapy, excision of malignant tumours and others [2,3,4]. Cicatricial entropion is characterized by progression. The therapeutic approach again ensues from the etiology. In the case of inflammatory conditions, we apply azitromycine or doxycycline. We commence therapy of pemphigoid by steroids or if applicable immunosuppressants [2]. However, the only long-term solution remains surgical correction. For cicatricial entropion it is possible to use "Z-plasty" for correction. In the

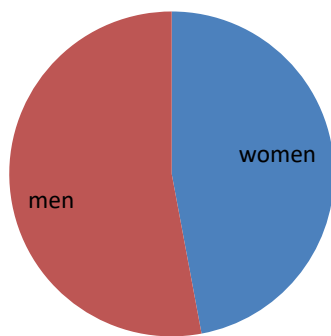
case of more extensive cicatricial processes, however, we more frequently select correction with the aid of an auto-transplant by a loose or sliding fold [1].

We encounter congenital entropion in rare cases in newborns and infants [4]. Spastic entropion originates upon excessive contraction of the internal fibres of the musculus orbicularis oculi, due to the influence of inflammation, trauma or prior operation [2,4].

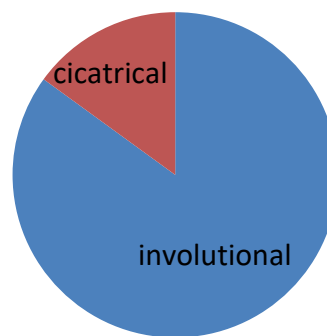
Ectropion is defined as a pathological position of the eyelid in which its eversion from the eyeball occurs [4]. Due to the influence of gravitational force, it almost always concerns an affliction of the lower eyelid [8]. As in the case of entropion, we distinguish a number of types according to cause. The most common type, namely involutional ectropion, is caused by increased horizontal laxity of the lower eyelid [1]. Cicatricial ectropion is generated by a deficiency of skin, which occurs as a consequence of a trauma, following prior operations or dermatitis. The development of paralytic ectropion takes place upon weakening of the musculus orbicularis oculi due to the influence of paresis of the nervus facialis. Other rare ectropions include congenital and mechanical [1,4,8]. The most common clinical manifestations of ectropion are epiphora, hyperaemia of the conjunctiva, irritation or chronic inflammatory changes of the conjunctiva. Untreated ectropion leads to exposure keratopathy, keratitis or corneal ulceration [1,8]. The only long-term solution to ectropion is again surgical correction. The choice of surgical procedure depends both on the etiology and the extent of ectropion. In the case of generalised involutional ectropion, the gold standard is the lateral tarsal strip technique. Correction of eversion of the lachrymal punctum itself can be performed simply with the aid of myrtle excision beneath the punctum from the conjunctival side, with subsequent suture [1]. In the case of localised cicatricial ectropion, the method of Z-plasty is used. Generalised cicatricial ectropion is best corrected by excision of the scar and its subsequent coverage with the aid of an auto-transplant [1]. The source of such a skin fold may be the upper eyelid, the retroauricular or supraclavicular region [9]. The most frequent surgical complications include hemorrhage, hematoma, infection, dehiscence of the wound, pain and poor location of the tarsal strip [8].

METHOD

A retrospective analysis was conducted at the Department of Ophthalmology at the Military University Hospital Prague, with the aim of demonstrating the quality and reliability of the surgical technique of lateral tarsal strip for the pathologies of the eyelids ectropion and entropion. The examined cohort contained a total of 43 eyes of 33 patients. The average age of all the patients was 79 years (range from 61 to 94 years). The ratio of women to men included in the study was 17:16. Data gathering took place from April 2018 to April 2020 at the Department of Ophthalmology at the Military University Hospital Prague. The operations were performed by two surgeons (JT, VK). Postoperative correction of the eyelid and the postoperative complications of the surgical method were evaluated objectively. This observa-



Graph 1. A Entropion - division of cohort by gender



Graph 1. B Entropion - division of cohort by origin

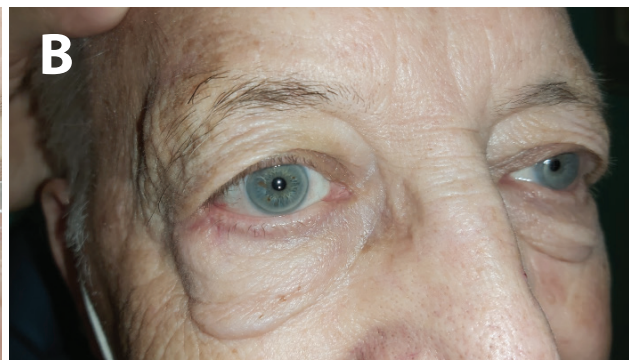
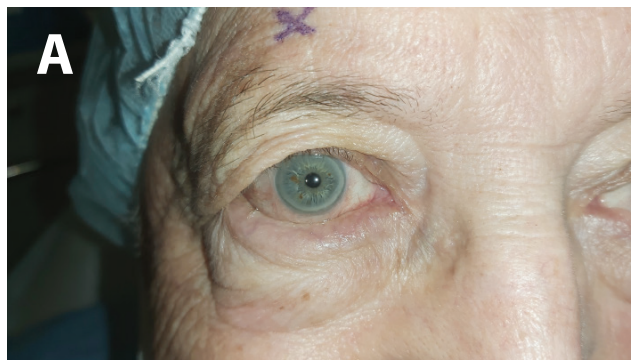
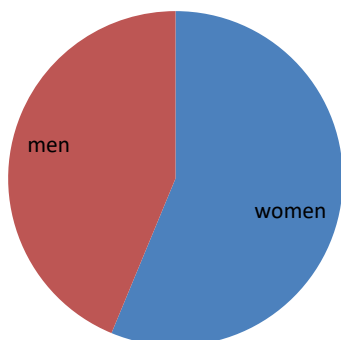


Fig. 1. (A) Entropion right eye – before surgery, **(B)** after surgery

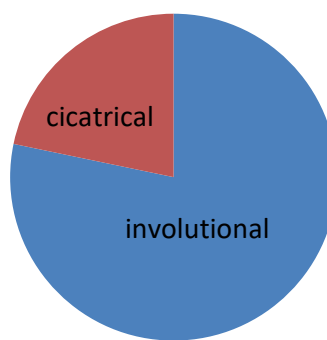
tion took place one week after surgery. The evaluation was conducted by the operating surgeon or assisting doctor, who had been well familiarized with the given pathology of the patient. In many cases, pictorial documentation obtained before the operation served to provide a more precise evaluation. In the second point, we observed subjective patient satisfaction. We asked patients about alleviation or subsidence of adverse symptoms, and for an evaluation of the result of the operation from a cosmetic point of view. In the group containing patients diagnosed with entropion, 17 patients were observed within the age range of 62 to 92 years (8 women, 9 men). A total of 20 eyes were operated on within this sample, in 12 cases the right eye and in 8 cases the left eye. In the studied group, the most widely represented was involutional entropion, with only 3 cases of cicatricial entropion originating after previous operations

(Graph 1 A,B). Other types of entropion did not appear in the observed sample (Fig. 1 A,B).

The observed group with a diagnosis of ectropion comprised a total of 16 patients within an age range of 61 to 94 years, women and men in a ratio of 9:7. The group consisted of 23 eyes, in 12 cases the right eye and 11 cases the left eye. In 18 cases this concerned involutional ectropion with symptoms of lachrymation, burning, stinging. In 5 cases it concerned cicatricial ectropion originating postoperatively, where in the past either surgical excision of a basal-cell carcinoma had been performed, or surgical correction of ectropion by another surgical technique with an unsatisfactory result (Graph 2 A,B). In the case of both diagnoses, correction of the lower eyelid was performed on all the patients (Fig. 2 A-D, Fig. 3 A-D, Fig. 4).



Graph 2. A Ectropion - division of cohort by gender



Graph 2. B Ectropion - division of cohort by origin

RESULTS

Entropion of lower eyelid

In 19 cases out of 20 in which a lateral tarsal strip was used, no pathological early secretion or dehiscence of

the wound took place during the period of healing. In a small number of cases, residual swelling or hematoma of the eyelids was perceptible. Only in one patient did we observe the presence of purulent secretion in the outer corner of the eye approximately one week after the pro-

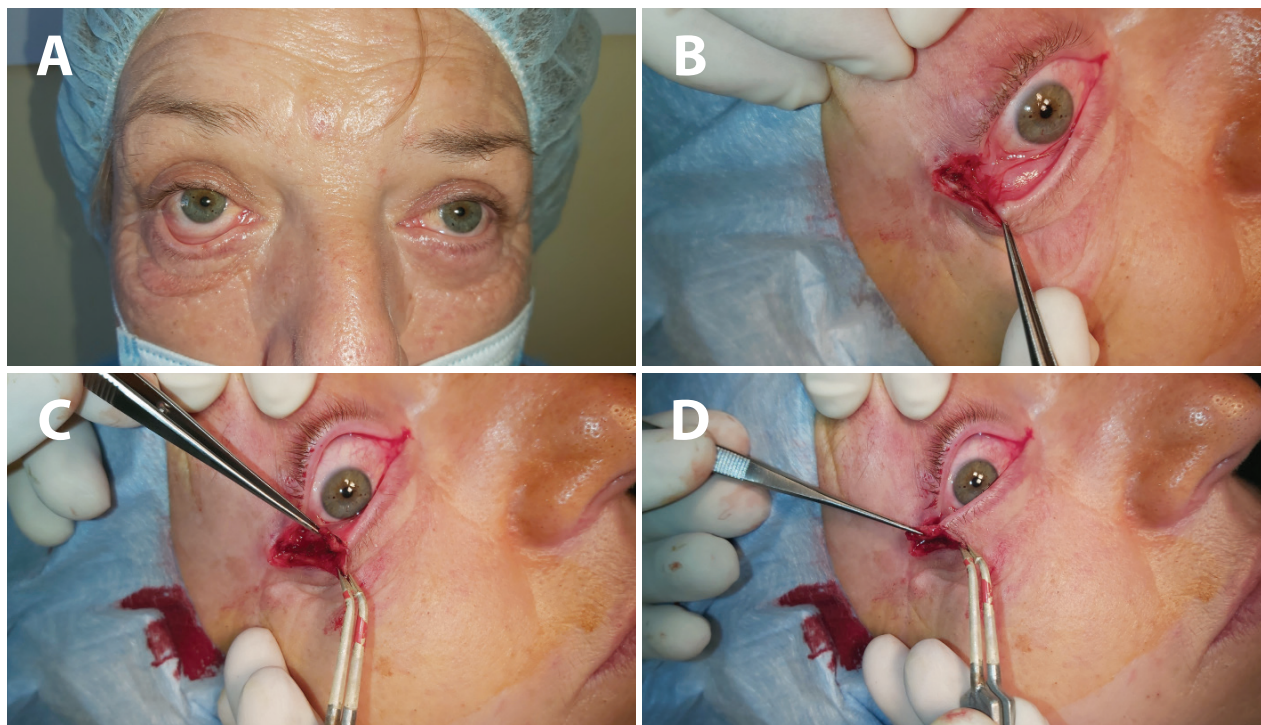


Fig. 2. (A) Ectropion right eye – before surgery, (B) canthotomy, cantholysis, (C) division of eyelid into two lamellas, (D) tarsal strip

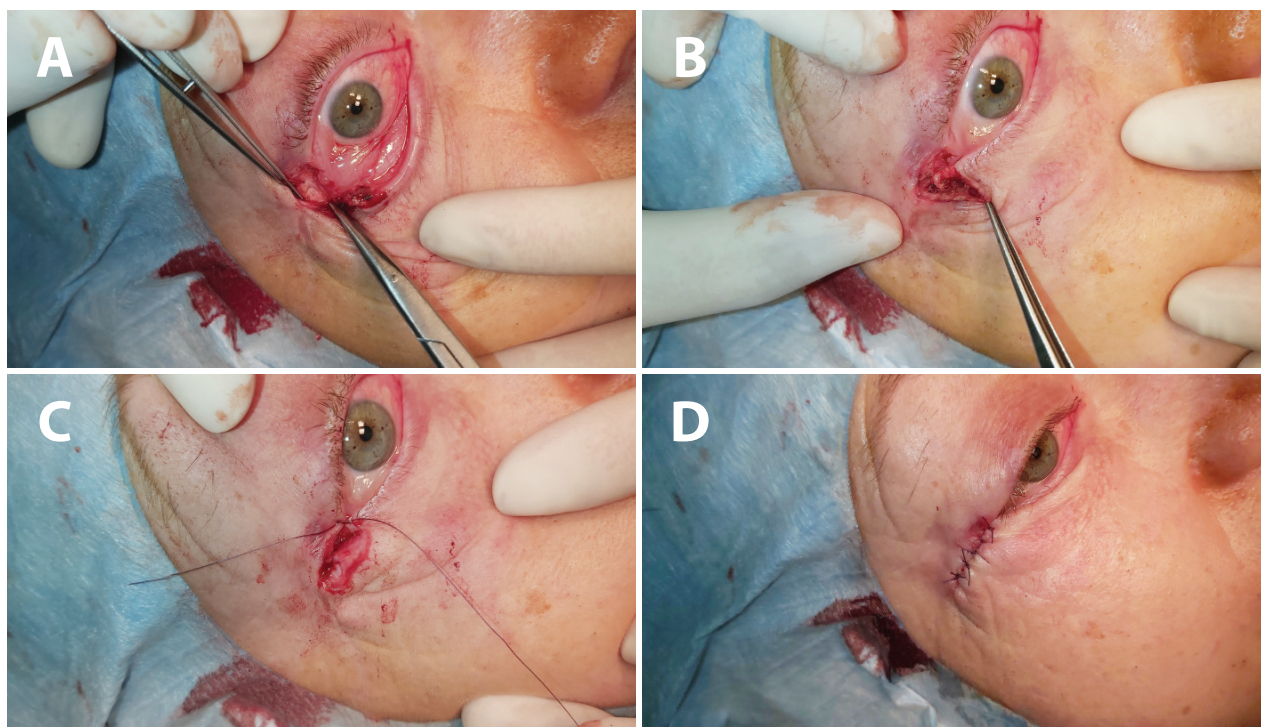


Figure 3. (A) Ectropion right eye – periosteum visualisation, (B) fixation of strip to periosteum (C) first suture, (D) suture of skin

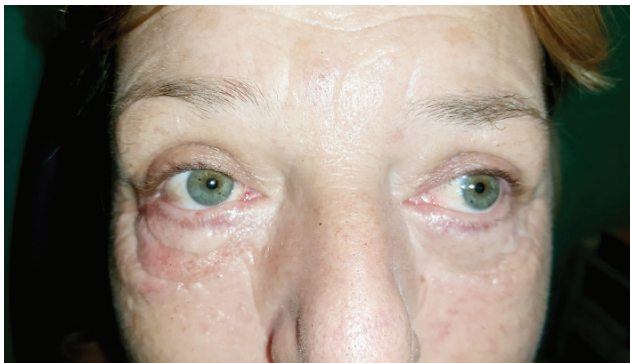


Figure 4. Ectropion right eye – after surgery

cedure, though this was not linked with any other complications. We succeeded in achieving correct repositioning of the eyelids in 95 % of cases. Entropion persisted postoperatively in only one patient. However, to date the patient has not stated any subjective complaints. In all three cases in which a secondary operation for correction of the eyelids took place, the resulting repositioning was satisfactory.

Ectropion of lower eyelid

No postoperative complications occurred during healing in any of the 23 cases, in which similarly as above, the lateral tarsal strip technique was used. At the first postoperative follow-up examination approximately one week after the procedure, in isolated cases we observed recurring swelling of the eyelids or residual hematoma in the surrounding area of the suture. However, no case arose in which there was purulent pathological secretion or dehiscence of the wound. In 91.3 % of cases of involutional and cicatricial ectropion, full correction of the position of the lower eyelids was achieved. Only in two cases we did not succeed in achieving the desired result. In the first of these two cases, slight apoptosis of the eyelids developed, which the patient perceived subjectively as persistent increased lachrymation and irritation of the inner corner. In the second case, undesirable temporal trichiasis occurred postoperatively. Of the original five cases of ectropion of cicatricial origin, in four cases we succeeded in achieving full repositioning of the eyelids, while in one case of cicatricial ectropion fully satisfactory correction of the eyelids was not achieved.

DISCUSSION

Ectropion and entropion are terms designating pathologies of the lower eyelids, and in rarer cases also the upper eyelids, appearing primarily within the ranks of the older population. Although on first impression it may appear that within the framework of ophthalmology this concerns defects of minor significance, the opposite is true. This often-inconspicuous defect of the eyelids may lead to unpleasant and burdensome symptoms, chronic irritation of the cornea, and thus cause severe corneal defects. A number of different surgical procedures are used

worldwide for the correction of ectropion and entropion. The choice of an appropriate need not necessarily always be a simple task. The surgical procedure is selected most often on the basis of the etiology, the pathogenesis of the given problem, the experience of the operating surgeon, horizontal laxity of the eyelid and other factors. Due to the aforementioned wide range of available surgical techniques, a questionnaire survey was published in Great Britain in 2017 by Mcveigh et al., concerning the preferences of oculoplastic surgeons. Out of a total number of 135 addressed surgeons, only 47 respondents took part in the questionnaire survey. In the case of diagnosis of entropion, according to the study the most popular method was a combined procedure of the lateral tarsal strip technique secured by auxiliary sutures (preferred in 44% of cases). In the case of ectropion, the lateral tarsal strip technique alone was the most preferred (in 35% of cases). However, the differences in preferences of the individual techniques were not substantial [10]. The aim of our retrospective study was to demonstrate the safety and quality of the lateral tarsal strip technique. On the basis of the results, we present here, the reliability of this relatively quick and simple method is clear, although it is not successful in 100% of cases. The study by Young et al., similarly to our study, dealt with an evaluation of the position of the eyelids after a performed corrective procedure using the lateral tarsal strip method. The evaluation was conducted on the basis of photographs obtained before and after surgery. The following parameters were observed: change of angle of outer corner, curvature of lower eyelid, size of exposed lower ocular surface and margin to reflex distance. The retrospective study incorporated 51 patients. According to the results, in these patients a reduction of exposure of the ocular surface was achieved, with more gradual curvature of the lower eyelids and a reduction of the margin – reflex distance, without any significant change to the angle of the outer corner [11]. A number of comparative studies have been conducted worldwide for the purpose of finding the safest and most reliable surgical techniques. In 2019 a randomized trial was published by Nakos et al., comparing the lateral tarsal strip technique against the Quickert auxiliary suture technique for involutional entropion. In the case of auxiliary sutures, the incidence of recurrence 12 months after surgery was markedly more frequent than in the case of the lateral tarsal strip technique [12]. However, according to a study by Scheepers et al., the lateral tarsal strip technique alone is affected by a higher rate of recurrences than a combined technique of lateral tarsal strip with securing by auxiliary sutures [13,14,15]. The published data shows that the degree of recurrence in the case of the lateral tarsal strip technique alone is 14-22%, whereas according to López-García it is around 4% in the case of a combined procedure [12,16]. However, this contrasts with the results of a study by Dulz et al., which focused on a comparison of a combined technique of lateral tarsal strip with auxiliary sutures and the Quickert suture technique alone. All the patients inclu-

ded in this study were operated by a single surgeon. The rate of recurrence in this study was comparable in the case of both techniques [17]. The last study we mention is the trial conducted by K. Y. R. Kam et al. from the Western Eye Hospital in London from 2012, comparing surgical correction of involutional ectropion using the lateral tarsal strip method with a combined technique of lateral tarsal strip and myrtle excision, which was performed on patients with higher initial laxity of the lower eyelids. The functional success rate of both methods was similar, in the case of the lateral tarsal strip method alone the success rate was 87%, while in the other group an improvement was achieved in 89% of cases. Although the results here are in favour of a combined approach, the authors themselves concede that the lateral tarsal strip method alone was not used on any of the patients with greater preoperative laxity of the lower eyelids, and that it is therefore impossible to compare the two groups unequivocally [18]. In conclusion, it is possible to state generally that the incidence of postoperative recurrences upon

the use of combined techniques is lower, and disorders of postoperative healing are minimal [13,14,15,16,19].

CONCLUSION

The main aim of surgical correction of eyelid abnormalities is to alleviate patients' subjective complaints, as well as an endeavour to prevent corneal degradations. Last but not least, a significant role is played also by the aesthetic aspect. From our sample of patients, it is evident that the sex of the individuals with the given pathology does not play a significant role. The surgical technique of lateral tarsal strip is one of several methods that can be used to correct ectropion or entropion, and in recent years it has gained considerable popularity among surgeons for good reason. It represents a relatively quick and safe technique of correcting involutional and cicatricial abnormalities, with good results and virtually zero incidence of complications. The rate of relief from symptoms and patient satisfaction is high.

LITERATURE

1. Kuchynka P. a kol. Oční lékařství, 2. přepracované a doplněné vydání. Praha (Česká republika): Grada Publishing, a.s.; 2016. Očnice, víčka a slzná žláza – jiná onemocnění; p. 740-741.
2. Burkat CN. Involutional or Senile Entropion. Retrieved. November 01, 2020. Available from: <https://www.aao.org/oculoplastics-center/involutional-senile-entropion>
3. Bashour M. Entropion Lower Eyelid Reconstruction. [online] Medscape. McGill University Faculty of Medicine. Feb 2020 [cit. 2020-10-28]. Available from: <https://emedicine.medscape.com/article/877281>
4. Heissigerová J. a kol. Oftalmologie pro pregraduální i postgraduální přípravu, 1. vydání. Praha (Česká republika): Maxdorf s.r.o.; 2018. Poruchy postavení víček; p. 74-75.
5. Parnes SM. Dynamic Reanimation for Facial Paralysis Treatment & Management. [online] Medscape. Albany Medical College. January, 2020 [cit. 2020-10-28]. Available from: <https://emedicine.medscape.com/article/879441-treatment>
6. DeBacker Ch. Entropion and Ectropion Repair. [online] Medscape. University of Texas Health Science Center at San Antonio. May, 2019 [cit. 2020-10-28]. Available from: <https://emedicine.medscape.com/article/1844045>
7. Krátký V. Trendy soudobé oftalmologie, Svazek 12. Praha (Česká republika): Galen Publishing; 2019. Běžná onemocnění víček a jejich chirurgické řešení; p. 79-111.
8. Ing ED. Ectropion. [online] Medscape. University of Arkansas for Medical Sciences. Jul, 2018 [cit. 2020-10-28]. Available from: <https://emedicine.medscape.com/article/1212398>
9. Kanski JJ, Bowling B. Clinical Ophthalmology a systematic approach, 7. vydání. Windsor, Blackpool (United Kingston): Elsevier; 2011. Eyelid; p. 46-50.
10. Mcveigh KA, Harrison R, Ford R. Entropion and ectropion repair: a snapshot of surgical practice in the United Kingdom. Orbit. 2018; 37(2): 105-109, doi: 10.1080 / 01676830.2017.1383461
11. Young W, Scofield-Kaplan SM, Levy RE, Keenum Z, Mancini R. Change in Lower Eyelid Contour Following Ectropion Repair With Lateral Tarsal Strip. Ophthalmic Plast Reconstr Surg. 2020 Mar. doi: 10.1097/IOP.0000000000001634
12. Nakos EA, Boboridis KG, Kakavouti-Doudou AA, Almaliotis DD, Sioulis CE, Karampatakis VE. Randomized Controlled Trial Comparing Everting Sutures with a Lateral Tarsal Strip for Involutional Lower Eyelid Entropion. Ophthalmol Ther. 2019;8(3):397-406. doi:10.1007/s40123-019-0189-3
13. Scheepers MA, Singh R, Ng J, et al. A randomized controlled trial comparing everting sutures with everting sutures and a lateral tarsal strip for involutional entropion. Ophthalmology. 2010;117(2):352-355. doi:10.1016/j.opht.2009.06.056
14. Ho SF, Pherwani A, Elsherbiny SM, Reuser T. Lateral tarsal strip and quickert sutures for lower eyelid entropion. Ophthalmic Plast Reconstr Surg. 2005;21(5):345-348. doi:10.1097/01.iop.0000179370.96976.ee
15. Rougraff PM, Tse DT, Johnson TE, Feuer W. Involutional entropion repair with fornix sutures and lateral tarsal strip procedure. Ophthalmic Plast Reconstr Surg. 2001;17(4):281-287. doi:10.1097/00002341-200107000-00008
16. López-García JS, García-Lozano I, Giménez-Vallejo C, Jiménez B, Sánchez Á, de Juan IE. Modified lateral tarsal strip for involutional entropion and ectropion surgery. Graefes Arch Clin Exp Ophthalmol. 2017;255(3):619-625. doi:10.1007/s00417-016-3536-2
17. Dulz S, Green S, Mehlan J, Schüttauf F, Keserü M. A comparison of the lateral tarsal strip with everting sutures and the Quickert procedure for involutional entropion. Acta Ophthalmol. 2019;97(6):e933-e936. doi:10.1111/aos.14093
18. Kam KY, Cole CJ, Bunce C, et al. The lateral tarsal strip in ectropion surgery: is it effective when performed in isolation? Eye 26(6); 2012: 827-832.
19. Serin D, Buttanri IB, Karslioglu S, Sevim MS, Buttanri B, Akbaba M. The efficacy of the combined procedure in involutional entropion surgery: a comparative study. Korean J Ophthalmol. 2013;27(6):405-408. doi:10.3341/kjo.2013.27.6.405