

# DIABETIC MACULAR EDEMA – DIAGNOSTICS AND TREATMENT GUIDELINES

Ernest J<sup>1,2,3</sup>, Němčanský J<sup>4,5</sup>, Vysloužilová D<sup>6</sup>, Veith M<sup>7</sup>,  
Studnička J<sup>8,9</sup>, Němec P<sup>3</sup>

<sup>1</sup>Neoris Vitreoretinal Center, s.r.o., Prague, Czech Republic

<sup>2</sup>Axon Clinical, s.r.o., Prague, Czech Republic

<sup>3</sup>Department of Ophthalmology, Central Military Hospital and 1<sup>st</sup>  
Faculty of Medicine, Charles University Prague, Czech Republic

<sup>4</sup>Department of Ophthalmology, University Hospital Ostrava,  
Czech Republic

<sup>5</sup>Department of Craniofacial Surgery, Faculty of Medicine,  
University of Ostrava, Czech Republic

<sup>6</sup>Department of Ophthalmology, University Hospital Brno Bohunice,  
Faculty of Medicine, Masaryk University Brno, Czech Republic

<sup>7</sup>Department of Ophthalmology, University Hospital Královské  
Vinohrady and 3<sup>rd</sup> Faculty of Medicine, Charles University Prague,  
Czech Republic

<sup>8</sup>Department of Ophthalmology, University Hospital Hradec  
Králové and Faculty of Medicine, Charles University in Hradec  
Králové, Czech Republic

<sup>9</sup>VISUS, spol. s r.o., Police nad Metují, Czech Republic

The authors of the study declare that no conflict of interests exists in the compilation, theme and subsequent publication of this professional communication, and that it is not supported by any pharmaceuticals company.

Received: June 4, 2023

Accepted: July 16, 2023

Available on-line: September 20, 2023



First author  
MUDr. Jan Ernest, Ph.D.

Corresponding author  
MUDr. Jan Němčanský, Ph.D., MBA  
Oční klinika FN Ostrava  
17. listopadu 1790  
708 52 Ostrava  
E-mail: jan.nemcansky@fno.cz

## SUMMARY

Together with diabetic retinopathy, diabetic macular edema (DME) ranks among the most common causes of severe loss of vision in working adults. Due to recent developments in imaging methods, new classification schemes of DME have been created. In addition to this, new treatment options have been introduced (new intravitreal drugs as well as treatment protocols). At the same time laser, surgical as well as combination therapy is still available.

In this paper we evaluate the current knowledge about DME diagnostic and treatment options and formulate recommended guidelines for the management of DME.

**Key words:** diabetic macular edema, treatment, recommended guidelines

*Čes. a slov. Oftal., 79, 2023, No. 5, p. 225–235*

## INTRODUCTION AND EPIDEMIOLOGY

Diabetic retinopathy (DR) is the most common organ complication of diabetes mellitus (DM), and together with diabetic macular edema (DME) is the main cause of blindness in the population of working age [1–4]. Diabetic macular edema (DME) occurring upon a background of diabetic retinopathy causes a deterioration of visual functions, primarily of central visual acuity (VA). It affects approximately 7% of diabetic patients [5–9]. Unless treatment of DME is commenced, a deterioration of visual acuity by 2 or more rows occurs in approximately 50% of patients within a period of 2 years [2,10].

In previous years, the treatment of DME was influenced by the results and recommendations of the ETDRS (Early Treatment Diabetic Retinopathy Study) for clinically significant macular edema [11]. This consisted in laser photocoagulation (LPC) of the retina, in the form of “grid” or focal LPC. For several decades this technique was the only option for the treatment of DME.

Despite the fact that grid LPC of the macula significantly reduced the risk of loss of central VA by 50% and also had a protective effect, it did not have a significant influence on improving visual functions [12]. For this reason also, at present laser photocoagulation of DMA is now limited to a narrow group

of macular edemas which do not afflict the center of the macular region (non-central involved DME – non-CIDME) and/or are not present in patients with very good initial VA.

With regard to advances in pharmacology, the focus of treatment of DME today consists in the intraocular administration of various types of pharmaceuticals, which have demonstrated very good effectiveness not only in stabilizing the pathology but also in improving visual functions in a significant proportion of patients [12–15].

Together with the development of new therapeutic techniques, in the last decade there has also been a precipitous advance in diagnostics – primarily in imaging methods. As a result, we are now better able to understand and classify the pathology in the specific patients, and subsequently to choose a tailor-made therapeutic procedure from a wide range of options – frequently consisting in a combination of pharmaceuticals or therapeutic methods.

## **PATHOPHYSIOLOGY OF DME**

DME has a multifactorial pathophysiology, which incorporates angiogenesis, increased vascular permeability and local inflammatory processes [16]. A whole range of mechanisms share in its origin and progression, the proportions and relationships of which have not yet been entirely clarified in detail. In general it is assumed that persistent hyperglycemia leads to microvascular changes, to a breach of the blood-ocular barrier, hypoxia and subsequently to a cascade of pathological metabolic processes. During the course of these events, a fundamental influence is exercised by increased production of vascular endothelial growth factor (VEGF) and inflammatory mediators (e.g. interleukins (IL-6, IL-10), intercellular adhesion molecule 1 (ICAM-1), tumor necrotizing factor  $\alpha$  (TNF- $\alpha$ ), angiopoietin 2 (Ang2), monocyte chemoattractant protein 1 (MCP-1), P-selectin etc. [17–20]. A breached blood-ocular barrier is the cause of an accumulation of intracellular and extracellular fluid and the depositing of lipid exudates in the retina, which leads to morphological and functional changes.

Pathological morphological manifestations can be effectively detected with the aid of fluorescence angiography (FAG), optical coherence tomography (OCT) and OCT angiography (OCT-A) [9]. The current approach to the treatment of DME respects its multifactorial pathophysiology, and is targeted at influencing processes of vasogenic and inflammatory activity and regulating their mediators.

The onset of DME may also be contributed to by adverse effects of certain orally administered antidiabetic

drugs – insulin sensitizers, which have the ability to retain fluid, primarily in advanced forms of DR. These include for example thiazolidinediones (pioglitazone) or the GLP 1 incretin mimetics liraglutide and semaglutide [21]. As a result, examination of the ocular fundus is appropriate before any planned application of these agents.

## **CLASSIFICATION OF DME**

The historical system of assessing DME according to the ETDRS (and the term clinically significant macular edema) is no longer adequate today, since it does not respect the advances that have been made in diagnostic imaging methods: FAG, OCT and OCT angiography, including their wide-field modalities. Above all, the development of OCT diagnosis enables the detection of early morphological changes and the precise definition of new markers of the onset and course of DME. Moreover, use of the latest technologies (e.g. neural networks) enables a detailed analysis and prediction of the natural development of the pathology and the effect of various therapeutic techniques [22]. All these factors have contributed to a revision of the classification of DME and to proposals for a whole range of new classification systems [2,5,23,24]. The most complex of these include the classification proposed by the international panel of leading European retina experts published in 2020 in the European Journal of Ophthalmology [2], which is based precisely upon a whole series of markers (see below).

The current basic system of classification of DME is based on OCT diagnosis and localization of the edema in relation to the center of the macula (Table 1) [25].

### **CIDME is further divided into:**

- **with deterioration of VA** (worse than 20/32 – Snellen worse than 6/9)
- **without deterioration of VA** (20/32 and better – Snellen 6/9 and better)

A key factor in the more detailed diagnosis and classification of DME is an analysis of morphological retinal changes, the detection of precisely defined biomarkers and an assessment of the thickness of the subfoveal zone with a diameter of 1 mm around the center (CST – central subfield thickness). We use high-definition (HD) OCT scans in parallel, raster and radial configuration, and we assess 7 basic OCT parameters [2]. Some authors do not consider the CST value itself to be significant, since it does not need to

**Table 1.** DME classification

<b>Diabetic macular edema</b>	<b>Retinal findings</b>
No DME	No increase in retinal (macular) thickness, absence of hard exudates
<b>Non-CIDME</b> (non-central involved DME)	Increase in macular thickness outside 1 mm diameter of the central subfoveal zone
<b>CIDME</b> (central involved DME)	Increase in macular thickness inside 1 mm diameter of the central subfoveal zone

*DME – diabetic macular edema*

correlate with the functional results [5,26,27]. However, for the purposes of our recommended guidelines and to follow on from our experience, assessment activity, evaluations and reporting of care to date, we consider this parameter and the assessment thereof to be beneficial and important.

Classification parameters and main markers of DME assessed in the central zone of 1 mm (CST) [2]:

- a) retinal thickness (T)– subfoveal retinal thickness
  - b) intraretinal cysts (IC) – rounded, minimally reflective spaces of outer/inner nuclear layer or ganglion cell layer
  - c) condition of ellipsoid zone (EZ) and/or external limiting membrane (ELM) – disorganization of outer retinal layers in region of connecting cilium of inner/outer segments of photoreceptors and line of ELM – inflammation marker
  - d) disorganization of retinal inner layers (DRIL) in foveal region – loss of stratification between layers between ganglion cells and inner plexiform layer – inflammation marker
  - e) hyperreflective lesions – foci (H) – inflammation marker
  - f) subretinal fluid (F) – presence of fluid between retinal pigment epithelium (RPE) and neurosensory retina – inflammation marker
  - g) vitreoretinal status (VS) – simplified version according to International Vitreomacular Traction Group [28]
- absence of any kind of visible adhesion or traction between vitreous and retina
  - incomplete vitreous detachment (PVD, posterior vitreous detachment)
  - complete vitreous detachment
  - vitreomacular traction (VMT)
  - epiretinal membrane (ERM)

All these parameters may occur in mutual combination, and their presence is of determining significance for the choice of treatment.

A comprehensive assessment of the individual OCT parameters is the basis for a detailed classification of DME (and diabetic maculopathy in the broader sense) according to Panozzo et al. [2] This is determined primarily for retinal specialists and centers, where specialized DME treatment is provided. First of all an assessment (grading) of the 7 fundamental parameters is performed, with a calculation of the TCED-HFV score, followed by a determination of the stage of DME (staging) – early, medium, severe, atrophic maculopathy [2].

Grading of the TCED-HFV score, including pictorial documentation, is illustrated in sections 6 and 7 of this article.

## TREATMENT OF DME

### Compensation of diabetes and concomitant illnesses

A fundamental precondition for the successful treatment of complications of diabetes (including treatment

of DR and DME) is the treatment of the underlying pathology and associated disorders (hypertension, lipid metabolism disorders etc.). At the same time patient cooperation is necessary, including adherence to the general guidelines relating to lifestyle and exercise regimen. This issue is dealt with in the Recommended Guidelines for the diagnosis and treatment of DR, and is under the guidance of the attending specialist – general practitioner, internal medicine specialist or diabetologist.

### Laser photocoagulation

Today LPC is used in strictly indicated cases – for eyes with non-CIDME or eyes with CIDME and concurrent very good VA (better than 20/32). The goal is direct focal photocoagulation of the individual infiltrating microaneurysms (or if applicable retinal thickening) according to the modified ETDRS protocol [29, 30]. A prerequisite for successful treatment is prior performance of FAG, detection of the individual infiltrating aneurysms and subsequently their targeted treatment, optimally navigated by an automatic laser. By this procedure it is possible to achieve subsequent regression of DME [31-34].

In eyes with non-CIDME we perform focal treatment if the edema is threatening the fovea [25,35].

In eyes with CIDME and VA better than 20/32 we perform focal treatment of microaneurysms in the case that they are located at least 300–500 µm from the center of the macula. Previously used grid photocoagulation of the macula has only a minimal effect on improving visual functions [11,13,14], and has now been replaced by intravitreal applications of substances acting against vascular endothelial growth factor (anti-VEGF) or corticoids.

Comparable and better results than classical photocoagulation can be achieved by a micropulse laser, which is more economical – it works by photostimulation of chromophores in the RPE and does not cause collateral damage to tissue, atrophy or scarring [36–40]. It is used successfully in combination with pharmacotherapy, and is less effective in eyes with CST of >400 µm [36–39]. The technique differs from classical photocoagulation; we use confluent subthreshold beams on the region of the fovea (at least 500 µm from the center) and into the region of retinal thickening [39].

For patients with the appearance of DME and concurrent presence of non-proliferative or proliferative diabetic retinopathy, we consider an indication of “scatter” laser photocoagulation of the ischemic zones of the peripheral retina. In these cases, LPC reduces the production of VEGF and subsequently also limits the risk of onset of DME by reducing the production of VEGF factors. LPC is effective in monotherapy and in combination with intraocular application of anti-VEGF agents [26,41].

### Pharmacological intraocular intravitreal treatment ANTI-VEGF AGENTS

Anti-VEGF treatment today represents the basic therapeutic procedure in the treatment of CIDME.

In eyes with CIDME with VA worse than 20/32, nu-

merous randomized clinical trials have demonstrated a statistically significant effect and an improvement of VA in comparison with observation or laser treatment [13,14,26,42]. This was the case of the Protocol T study by DRCR.net, which concurrently evaluated several anti-VEGF agents and compared their effectiveness and side effects. The assessed agents were aflibercept, bevacizumab and ranibizumab [15]. Ranibizumab and aflibercept demonstrated their effectiveness also in regular clinical practice.

Further effective new anti-VEGF agents are brolicizumab and faricimab. These pharmaceuticals have demonstrated comparable effectiveness with aflibercept in prospective randomized trials, and at the same time attain a therapeutic effect with a low frequency of administration of the drug during the observation period [43,44].

In eyes with CIDME with very good VA, i.e. 20/32 and better, we only have a limited quantity of data from clinical trials. Nevertheless, it has been demonstrated that in these patients also, the application of anti-VEGF agents has a positive influence on improving the anatomical and functional finding. At the same time a smaller number of injections is required in order to attain a therapeutic effect [26].

The aim of anti-VEGF treatment is to achieve an optimal therapeutic response with a minimal number of injections, taking into account the burden placed on the patient, the healthcare providers and the healthcare payers. For this reason, a very important aspect of treatment is also the dosing of the drug and the choice of therapeutic intervals. We commence treatment by the loading phase, which has fixed therapeutic intervals, and subsequently continue through the maintenance phase of treatment. The dosing and therapeutic intervals are individual, according to the type of individual agents. At the same time, clinical trials have unequivocally demonstrated the need for initial intensive treatment in the first

year, while in the second year a certain relaxation of these parameters is possible according to the response to treatment and the development of the finding [15,35,45].

In principle, the following options of application regimen have currently been established:

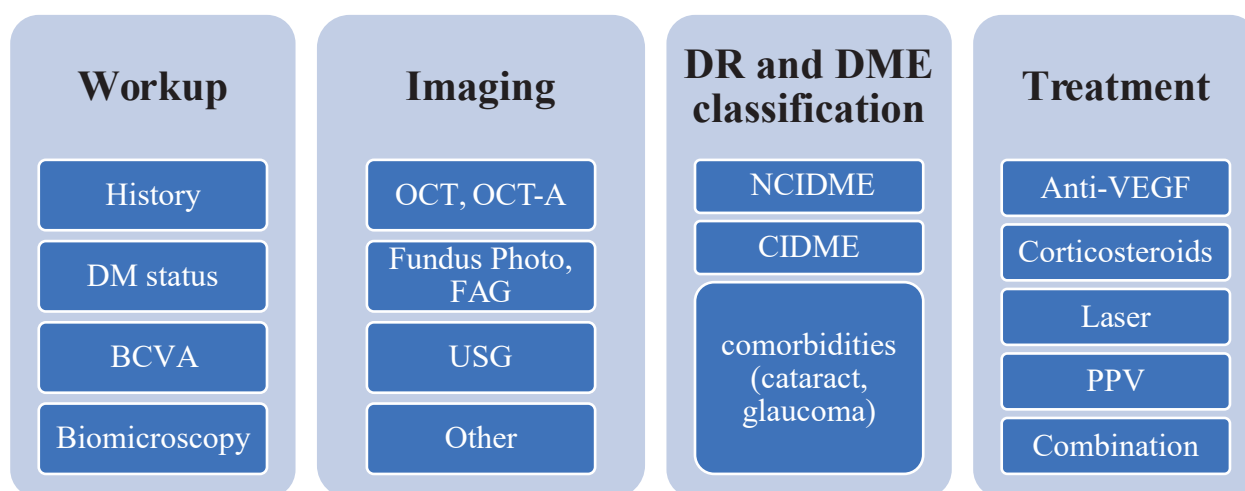
- fixed regimen with fixed intervals between individual administrations of drug
- treatment with progressive extension of therapeutic intervals – treat and extend regimen (T&E)

A fixed regimen of applications at fixed intervals according to the individual agents (1–3 months between doses), as well as rigorous monitoring of treatment, enables us to attain the best anatomic and functional result [15,46]. For this reason, this regimen is selected for all patients as a rule in the initial loading phase.

However, conclusions from a series of trials also support the fact that an optimal therapeutic result can be attained in the maintenance phase with a smaller number of injections. Consequently, after the loading phase it is an advantage to continue in a T&E regimen [15,46–49].

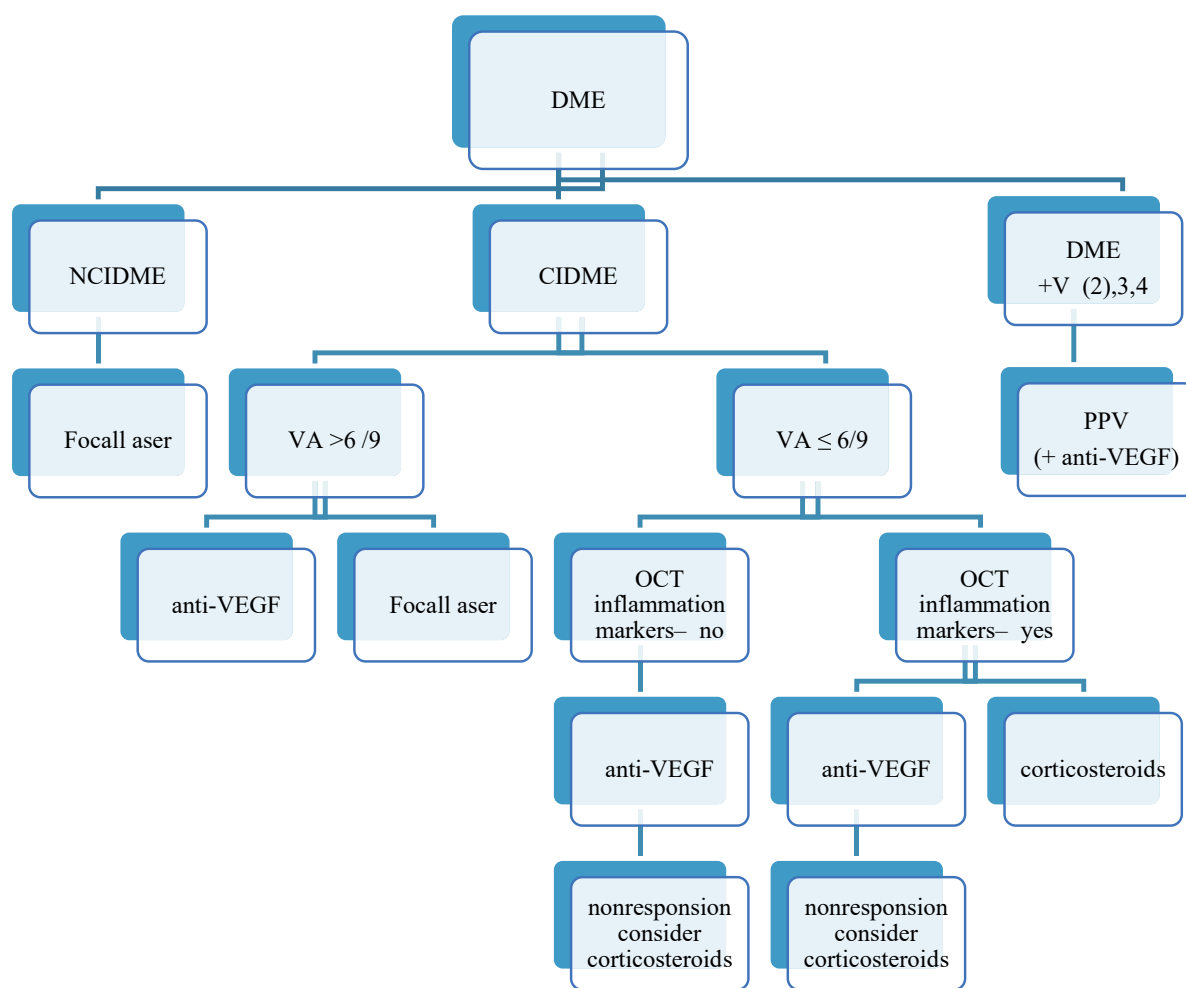
The choice of therapeutic interval in the maintenance phase ensues primarily from the therapeutic response and dynamics of the finding of the patient in the first year of treatment. In the case of a good therapeutic response to the initial doses of the anti-VEGF preparation in the first year of treatment, it is possible to expect an extension of the interval between applications to as long as 12–20 weeks in the second year within the T&E regimen.

The previously used pro re nata (PRN) regimen may attain similar results (especially in the first year of treatment) as the fixed and T&E regimen, but at the price of intensive monitoring of patients – a larger number of follow-up examinations – and for this reason it is used only minimally today [50,51].



**Figure 1.** Diabetic macular edema diagnostics and treatment

DM – diabetes mellitus, DME – diabetic macular edema, BCVA – best corrected visual acuity, OCT – optic coherent tomography, OCT-A – OCT angiography, FAG – fluorescein angiography, USG – ultrasonography, NCIDME – non central involved DME, CIDME – central involved DME, VEGF – vascular endothelial growth factor, PPV – pars plana vitrectomy



**Figure 2.** Management of DME treatment

*DME – diabetic macular edema, NCIDME – non central involved DME, CIDME – central involved DME, VA – visual acuity, OCT – optic coherent tomography, PPV – pars plana vitrectomy, VEGF – vascular endothelial growth factor, V – vitreoretinal status*

**Table 2.** TCED-HFV DME score/grading. Adapted from Panozzo et al [2]

Parameter	Zkratka	0	1	2	3	4
Retinal thickness (normal value)	T	Increase less than 10%	Increase more than 10%	Increase more than 30%		
Intraretinal cysts	C	No	Mild	Moderate	Severe	
Ellipsoid zone and ELM	E	Intact	Disruption	Absent		
DRIL	D	No	Yes			
Hyperreflective foci	H	< 30	≥ 30			
Subretinal fluid	F	No	Yes			
Vitreoretinal status	V	No adhesion No traction	Incomplete PVD	Total PVD	VMT	ERM

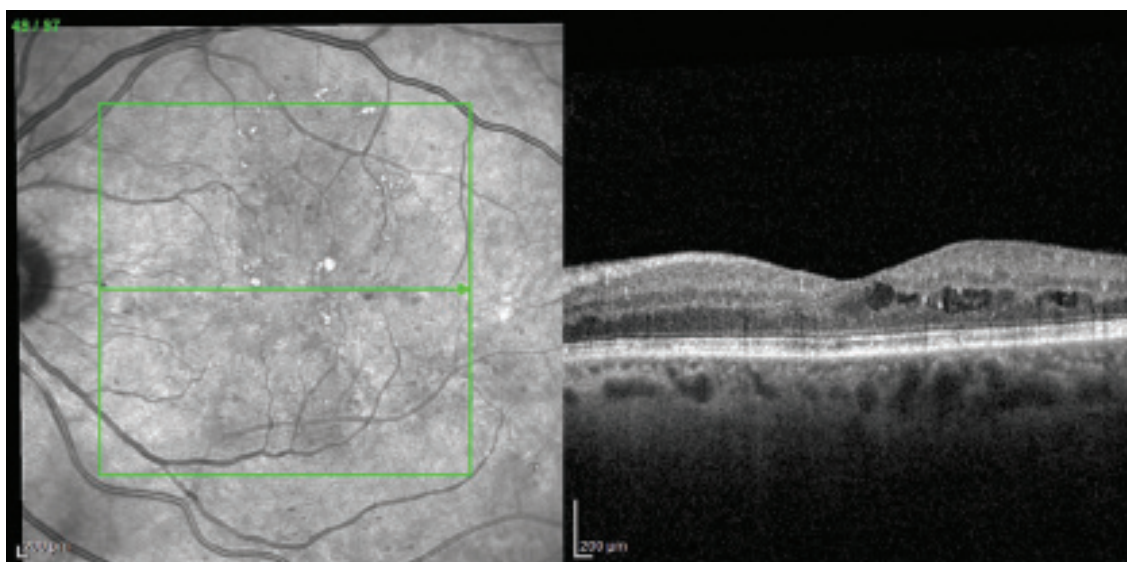
*DME – diabetic macular edema, ELM – external limiting membrane, DRIL – disorganisation of the inner retinal layers, PVD – posterior vitreous detachment, VMT – vitreomacular traction, ERM – epiretinal membrane*



**Table 3.** DME staging. Adapted from Panozzo et al [2]

Stage	T	C	E and/or D
Early DME	T1	C1-2	<b>E0 and D0</b>
Advanced DME	T1-2	C1-3	E0-1 and D0 or D1
Severe DME	T1-3	C1-3	E2 and D0 or D1
Atrophic diabetic maculopathy	<b>T0</b>	C0-2	E2 and D0 or D1

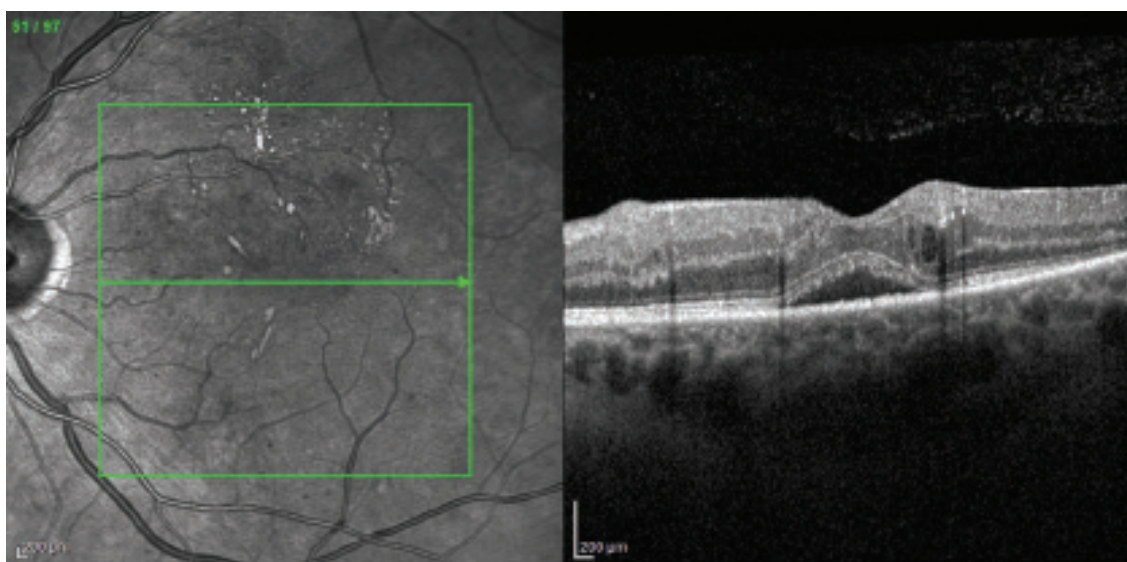
*DME – diabetic macular edema*



**Figure 3.** Early DME

Edema temporally to fovea, mild intraretinal cysts in inner and outer retinal layers, hyperreflective foci (less than 30). Grading T-1, C-2, E-0, D-0, H-0, F-0, V-0. Adapted from Panozzo et al [2]

*DME – diabetic macular edema*



**Figure 4.** Early DME

Minimal edema temporally, preserved retinal architecture, mild intraretinal cysts, preserved outer and inner retinal layers, hyperreflective foci (more than 30), subretinal fluid, vitreoretinal status without pathology. Grading T-1, C-1, E-0, D-0, H-1, F-1, V-0. Adapted from Panozzo et al [2]

*DME – diabetic macular edema*

Approximately 20–42% of treated patients manifest insufficient (suboptimal) or no therapeutic response, referred to as “nonresponse”, regardless of the chosen anti-VEGF preparation [14,16,47,52–55].

Symptoms of suboptimal response or nonresponse are:

- persistent worsened VA even despite intensive treatment
- deterioration of VA
- persistence of edema
- signs of activity (markers) on OCT examination – quantitative evaluation during the course of treatment, above all DRIL, EZ, H, F.

We also consider a gain of less than 5 letters of VA at the end of the loading phase to constitute a suboptimal response. At the same time, it has been demonstrated that such eyes have poor long-term results [54].

After an assessment of the morphological signs (biomarkers), we recommend that patients who manifest

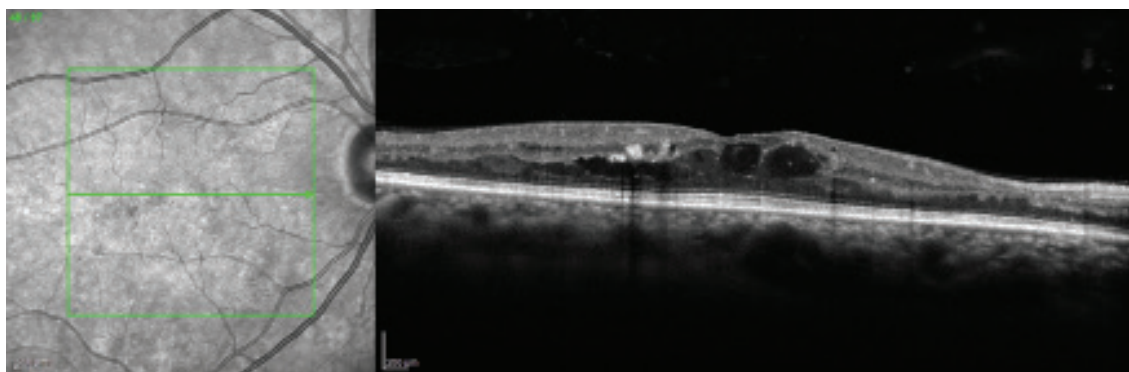
signs of suboptimal response or nonresponse are transferred to another type of treatment.

#### CORTICOIDS

For many years, anti-VEGF was the treatment of first choice for DME, and depot corticoids were considered the drug of second choice. They were used only after the failure of anti-VEGF or in the case of contraindications, upon limited patient co-operation and in the case of impossibility of conducting frequent follow-up examinations. With the ever-increasing number of patients and the attendant increase in the number of suboptimal therapeutic responses or nonresponses to anti-VEGF agents, there is also an increased requirement for the use of corticoid treatment.

In the case of detection of inflammation markers on OCT (DRIL, EZ, HF), or upon signs of chronicity of the finding, the use of intravitreal depot corticoids may in fact be the primary choice.

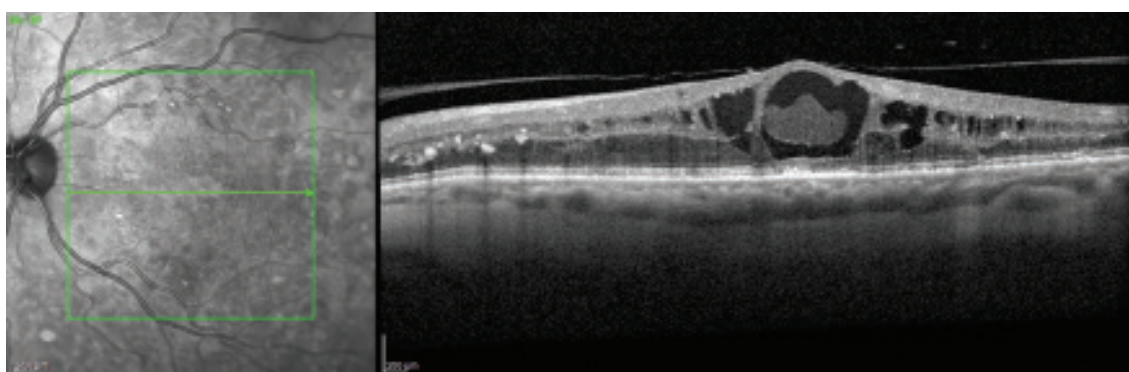
Intravitreal depot corticoids act with a different mechanism than anti-VEGF agents. They block a broad spectrum



**Figure 5.** Advanced DME

Retinal edema, intraretinal cysts in outer and inner retinal layers, preserved outer retinal layers, disorganisation of the inner retinal layers, hyperreflective foci (more than 30), no subretinal fluid, vitreoretinal status without pathology. Grading T-1, C-2, E-0, D-1, H-1, F-0, V-0. Adapted from Panozzo et al [2]

*DME – diabetic macular edema*



**Figure 6.** Advanced DME

Retinal edema, intraretinal cysts, macrocysts in central subfoveal zone with hyperdense content, disrupted ellipsoid zone, disorganisation of the inner retinal layers, hyperreflective foci (more than 30), no subretinal fluid, adherent cortical vitreous. Grading T-2, C-3, E-1, D-1, H-1, F-0, V-1. Adapted from Panozzo et al [2]

*DME – diabetic macular edema*

of cytokines, inhibit leukostasis and reduce vascular permeability [42,56–58]. At present it is possible to use dexamethasone or fluocinolone acetonide for intravitreal application. Both agents are in the form of depot reservoirs with gradual release of the pharmaceutical into the vitreous area.

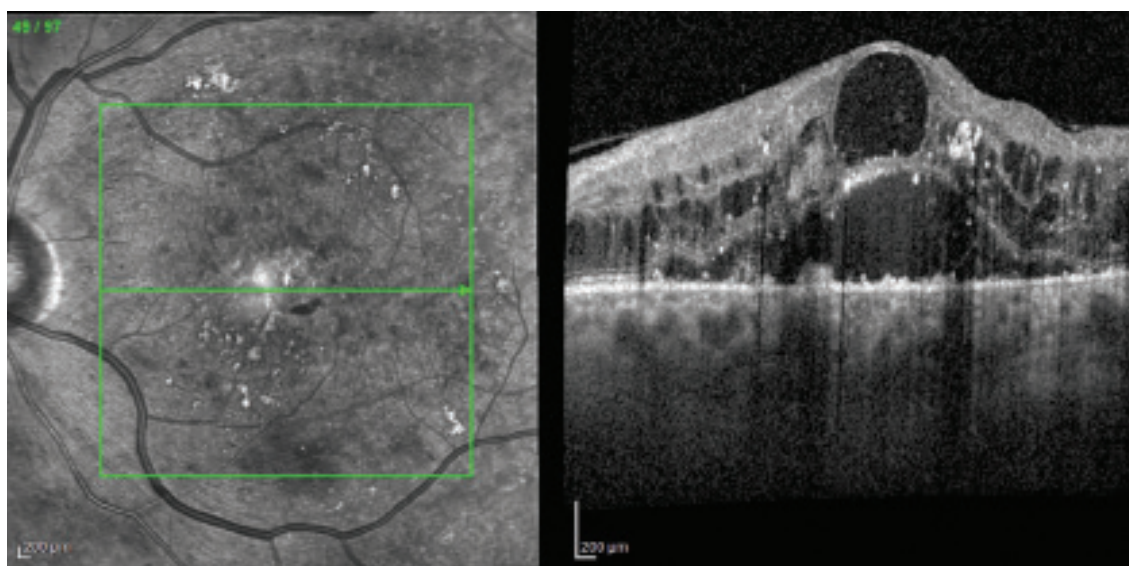
#### DEPOT DEXAMETHASONE

In the case of depot dexamethasone, a significant anatomical and functional effect has been demonstrated in comparison with observation, although at the same time a high percentage (68%) of development of complicated cataract has also been observed [42]. In more than 28% of patients it was also necessary to apply local treatment with antiglaucoma drugs, and in 0.3% of patients antiglaucoma surgery

was required [59]. Repeated intravitreal applications did not lead to a further increase of intraocular pressure (IOP), and as a result it is possible to apply depot dexamethasone more frequently than once per 6 months. We recommend depot dexamethasone for the following conditions:

- insufficient therapeutic response to anti-VEGF
- contraindication of anti-VEGF
- signs of chronicity of pathology (persistent edema)
- advanced morphological changes on OCT: DRIL, EZ, HF

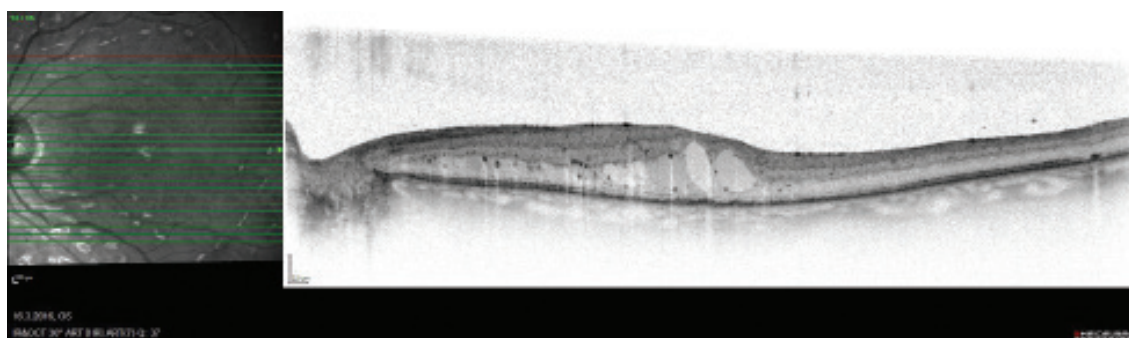For all patients it is necessary to take into account the risk of IOP elevation, in phakic patients there is also a risk of development or progression of cataract.



**Figure 7.** Severe DME

Retinal edema, intraretinal cysts in outer and inner layers, macrocyst in the center, disorganisation of the inner retinal layers, absent ellipsoid zone, multiple hyperreflective foci (more than 30), subretinal fluid present, adherent cortical vitreous. Grading T-2, C-3, E-2, D-1, H-1, F-1, V-1. Adapted from Panozzo et al [2]

*DME – diabetic macular edema*

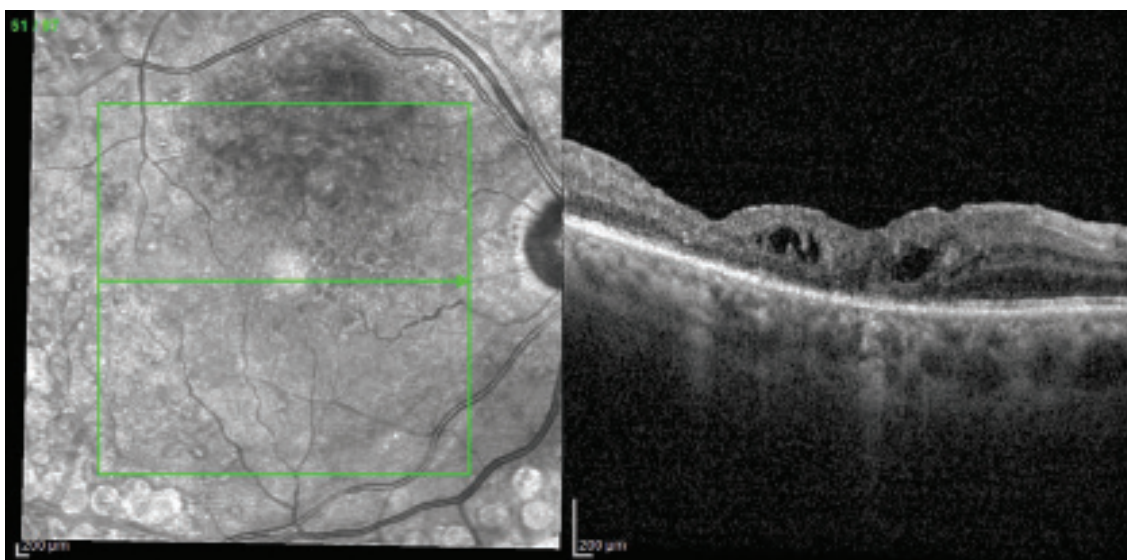


**Figure 8.** Severe DME

Retinal edema, intraretinal cysts in outer layers, larger cysts in the central subfoveal zone, minimal disorganisation of the inner retinal layers, absent ellipsoid zone, multiple hyperreflective foci, no subretinal fluid, vitreoretinal status without pathology. Grading T-1, C-2, E-2, D-0, H-1, F-0, V-0. Adapted from Panozzo et al [2]

*DME – diabetic macular edema*





**Figure 9.** Atrophic diabetic maculopathy

Central retinal thickness increased less than 10% of normal value (303  $\mu\text{m}$ ), mild intraretinal cysts, disorganization of the inner retinal layers, disruption of the ellipsoid zone, hyperreflective foci (more than 30), atrophic retinal pigment epithelium, epiretinal membrane with tangential traction. Grading T-0, C-1, E-1, D-1, H-1, F-0, V-1. Adapted from Panozzo et al [2]

The dosing of depot dexamethasone is individual according to the response to the previous application. The interval of the subsequent application is usually between 4 and 6 months, and before each further application it is necessary to pay regard to the TCED-HFV classification.

Depot dexamethasone can be combined with other therapeutic procedures, above all with LPC or anti-VEGF treatment. In clinical trials, patients treated with a combination of depot dexamethasone and anti-VEGF drugs have shown a greater improvement of visual functions and a greater reduction of CST in comparison with patients with anti-VEGF monotherapy [60].

#### DEPOT FLUOCINOLONE ACETATE

Another type of depot intravitreal corticoid used for the treatment of DME is fluocinolone acetate. The FAME study demonstrated a significant positive effect of this corticoid on reducing CST and improving visual functions in patients with DME [61]. In a trial conducted over a three-year observation period, it was necessary to apply an average of only 1.3 injections to patients. Similarly as in the case of dexamethasone, the application of fluocinolone is linked with a higher risk of the development of cataract (82%) and elevation of IOP (37%) [57]. Most patients with IOP elevation responded well to local antiglaucoma agents, and surgical intervention was necessary in only 4.8% of cases [57]. The therapeutic effect of corticoid treatment persisted over 3 years even with a minimal number of injections (average 1.3 injections). Almost 28% of patients had a gain of > 15 letters of ETDRS.

Patients with DME suitable for treatment with fluocinolone acetate are those in whom:

- prior treatment with anti-VEGF was unsuccessful
- good therapeutic response to application of another corticoid was recorded

#### Surgical treatment– pars plana vitrectomy

The role of the vitreoretinal interface and adherent posterior cortical vitreous has long been considered a significant factor in the pathophysiology of DME. At the same time, it also plays a role in influencing the reaction to conservative therapy [62,63]. Within the TCED-HFV classification, the vitreoretinal status should therefore always be evaluated, and the individual treatment selected according to the determined classification. A significant role in the diagnosis of the condition of the vitreoretinal (VR) interface is played not only by clinical examination and OCT, but also by sonographic examination with a B scan and its kinetic recording. The removal of the adherent cortical vitreous from the posterior pole and elimination of the pathology of the VR interface improves oxygenation of the vitreous and retina [63,64].

The indication for the performance of pars plana vitrectomy (PPV) is DME which is resistant to conservative therapy (anti-VEGF or corticoids) in patients:

- with adherent cortical vitreous
- with manifest ERM
- with vitreomacular traction syndrome
- with another pathology of the VR interface

At present there is no randomized clinical trial which compares the effect of PPV alone and PPV in combination with pharmacological treatment, though a series of publications exist which demonstrate a positive effect of additive anti-VEGF treatment before, during and after the performance of PPV [45,64].

## SCHEMA OF DIAGNOSIS AND TREATMENT OF DME

The schemas of diagnosis and treatment of DME and the decision-making procedure for treatment of DME are illustrated in Fig. 1,2.

## REFERENCES

- Ehlers JP, Yeh S, Maguire MG, et al. Intravitreal Pharmacotherapies for Diabetic Macular Edema: A Report by the American Academy of Ophthalmology. *Ophthalmology*. 2022;129(1):88-99.
- Panozzo G, Cicinelli MV, Augustin AJ, et al. An optical coherence tomography-based grading of diabetic maculopathy proposed by an international expert panel: The European School for Advanced Studies in Ophthalmology classification. *Eur J Ophthalmol*. 2020;30(1):8-18.
- Rowley WR, Bezold C, Arian Y, Byrne E, Krohe S. Diabetes 2030: Insights from Yesterday, Today, and Future Trends. *Popul Health Manag*. 2017;20(1):6-12.
- Zhang X, Saaddine JB, Chou CF, et al. Prevalence of diabetic retinopathy in the United States, 2005-2008. *Jama*. 2010;304(6):649-656.
- Huang YT, Chang YC, Meng PP, et al. Optical Coherence Tomography Biomarkers in Predicting Treatment Outcomes of Diabetic Macular Edema After Dexamethasone Implants. *Front Med (Lausanne)*. 2022;9:852022.
- Lian JX, Gangwani RA, McGhee SM, Chan CK, Lam CL, Wong DS. Systematic screening for diabetic retinopathy (DR) in Hong Kong: prevalence of DR and visual impairment among diabetic population. *Br J Ophthalmol*. 2016;100(2):151-155.
- Tan GS, Cheung N, Simó R, Cheung GC, Wong TY. Diabetic macular oedema. *Lancet Diabetes Endocrinol*. 2017;5(2):143-155.
- Wong TY, Cheung CM, Larsen M, Sharma S, Simó R. Diabetic retinopathy. *Nat Rev Dis Primers*. 2016;2:16012.
- Yang Y, Bailey C, Loewenstein A, Massin P. Intravitreal corticosteroids in diabetic macular edema: pharmacokinetic considerations. *Retina*. 2015;35(12):2440-2449.
- Sabanayagam C, Yip W, Ting DS, Tan G, Wong TY. Ten Emerging Trends in the Epidemiology of Diabetic Retinopathy. *Ophthalmic Epidemiol*. 2016;23(4):209-222.
- Photocoagulation for diabetic macular edema. Early Treatment Diabetic Retinopathy Study report number 1. Early Treatment Diabetic Retinopathy Study research group. *Arch Ophthalmol*. 1985;103(12):1796-1806.
- Bakri SJ, Wolfe JD, Regillo CD, Flynn HW, Wyckoff CC. Evidence-Based Guidelines for Management of Diabetic Macular Edema. *Journal of Vitreoretinal Diseases*. 2019;3(3):145-152.
- Korobelnik JF, Do DV, Schmidt-Erfurth U, et al. Intravitreal aflibercept for diabetic macular edema. *Ophthalmology*. 2014;121(11):2247-2254.
- Nguyen QD, Brown DM, Marcus DM, et al. Ranibizumab for diabetic macular edema: results from 2 phase III randomized trials: RISE and RIDE. *Ophthalmology*. 2012;119(4):789-801.
- Wells JA, Glassman AR, Ayala AR, et al. Aflibercept, Bevacizumab, or Ranibizumab for Diabetic Macular Edema: Two-Year Results from a Comparative Effectiveness Randomized Clinical Trial. *Ophthalmology*. 2016;123(6):1351-1359.
- Downey L, Acharya N, Devonport H, et al. Treatment choices for diabetic macular oedema: a guideline for when to consider an intravitreal corticosteroid, including adaptations for the COVID-19 era. *BMJ Open Ophthalmol*. 2021;6(1):e000696.
- Funatsu H, Noma H, Mimura T, Eguchi S, Hori S. Association of vitreous inflammatory factors with diabetic macular edema. *Ophthalmology*. 2009;116(1):73-79.
- Funk M, Schmidinger G, Maar N, et al. Angiogenic and inflammatory markers in the intraocular fluid of eyes with diabetic macular edema and influence of therapy with bevacizumab. *Retina*. 2010;30(9):1412-1419.
- Lupo G, Motta C, Giurdanella G, et al. Role of phospholipases A2 in diabetic retinopathy: in vitro and in vivo studies. *Biochem Pharmacol*. 2013;86(11):1603-1613.
- Sonoda S, Sakamoto T, Yamashita T, Shirasawa M, Otsuka H, Sonoda Y. Retinal morphologic changes and concentrations of cytokines in eyes with diabetic macular edema. *Retina*. 2014;34(4):741-748.
- Sharma A, Parachuri N, Kumar N, et al. Semaglutide and the risk of diabetic retinopathy-current perspective. *Eye (Lond)*. 2022;36(1):10-11.
- Gallardo M, Munk MR, Kurmann T, et al. Machine Learning Can Predict Anti-VEGF Treatment Demand in a Treat-and-Extend Regimen for Patients with Neovascular AMD, DME, and RVO Associated Macular Edema. *Ophthalmol Retina*. 2021;5(7):604-624.
- Szeto SK, Hui VWK, Tang FY, et al. OCT-based biomarkers for predicting treatment response in eyes with centre-involved diabetic macular oedema treated with anti-VEGF injections: a real-life retina clinic-based study. *Br J Ophthalmol*. 2023;107(4):525-533.
- Tang F, Wang X, Ran AR, et al. A Multitask Deep-Learning System to Classify Diabetic Macular Edema for Different Optical Coherence Tomography Devices: A Multicenter Analysis. *Diabetes Care*. 2021;44(9):2078-2088.
- Wong TY, Sun J, Kawasaki R, et al. Guidelines on Diabetic Eye Care: The International Council of Ophthalmology Recommendations for Screening, Follow-up, Referral, and Treatment Based on Resource Settings. *Ophthalmology*. 2018;125(10):1608-1622.
- Bressler SB, Qin H, Beck RW, et al. Factors associated with changes in visual acuity and central subfield thickness at 1 year after treatment for diabetic macular edema with ranibizumab. *Arch Ophthalmol*. 2012;130(9):1153-1161.
- Szeto SK, Hui VWK, Tang FY, et al. OCT-based biomarkers for predicting treatment response in eyes with centre-involved diabetic macular oedema treated with anti-VEGF injections: a real-life retina clinic-based study. *Br J Ophthalmol*. 2021;107(4):525-533.
- Duker JS, Kaiser PK, Binder S, et al. The International Vitreomacular Traction Study Group classification of vitreomacular adhesion, traction, and macular hole. *Ophthalmology*. 2013;120(12):2611-2619.
- Fong DS, Strauber SF, Aiello LP, et al. Comparison of the modified Early Treatment Diabetic Retinopathy Study and mild macular grid laser photocoagulation strategies for diabetic macular edema. *Arch Ophthalmol*. 2007;125(4):469-480.
- Treatment Techniques and Clinical Guidelines for Photocoagulation of Diabetic Macular Edema: Early Treatment Diabetic Retinopathy Study Report Number 2. *Ophthalmology*. 1987;94(7):761-774.
- Everett LA, Paulus YM. Laser Therapy in the Treatment of Diabetic Retinopathy and Diabetic Macular Edema. *Curr Diab Rep*. 2021;21(9):35.
- Kernt M, Cheuteu R, Vounotrypidis E, et al. Focal and panretinal photocoagulation with a navigated laser (NAVILAS®). *Acta Ophthalmol*. 2011;89(8):e662-664.

## CLASSIFICATION, GRADING AND STAGING OF DME ACCORDING TO OCT MARKERS [2]

Classification of DME according to OCT markers – TCED-HFV score/grading – is presented in Table 2. The stages of DME/staging are determined according to the TCED-HFV evaluation of grading and are displayed in Table 3.

## PICTORIAL DOCUMENTATION

The appendix presents examples of early DME (Fig. 3,4), medium DME (Fig. 5,6), severe DME (Fig. 7,8) and atrophic diabetic maculopathy (Fig. 9).

33. Kozak I, Oster SF, Cortes MA, et al. Clinical evaluation and treatment accuracy in diabetic macular edema using navigated laser photocoagulator NAVILAS. *Ophthalmology*. 2011;118(6):1119-1124.
34. Sosna T. Diabetická retinopatie: diagnostika, prevence, léčba. 2 ed. Sosna T, editor. Praha: Axonite CZ; 2016.
35. Flaxel CJ, Adelman RA, Bailey ST, et al. Diabetic Retinopathy Preferred Practice Pattern®. *Ophthalmology*. 2020;127(1):P66-p145.
36. Sivaprasad S, Elagouz M, McHugh D, Shona O, Dorin G. Micropulsed diode laser therapy: evolution and clinical applications. *Surv Ophthalmol*. 2010;55(6):516-530.
37. Stanga PE, Reck AC, Hamilton AM. Micropulse laser in the treatment of diabetic macular edema. *Semin Ophthalmol*. 1999;14(4):210-213.
38. Scholz P, Altay L, Fauser S. A Review of Subthreshold Micropulse Laser for Treatment of Macular Disorders. *Adv Ther*. 2017;34(7):1528-1555.
39. Lois N, Campbell C, Waugh N, et al. Diabetic Macular Edema and Diode Subthreshold Micropulse Laser: A Randomized Double-Masked Noninferiority Clinical Trial. *Ophthalmology*. 2023;130(1):14-27.
40. Zavorkova M, Nekolova J, Prochazkova L, Cermakova E, Jiraskova N. Diabetic macular edema treatment with subthreshold micropulse laser - five-year long monitoring. *Biomedical papers*. 2023;167(1):74-79.
41. Vujosevic S, Toma C, Villani E, et al. Diabetic macular edema with neuroretinal detachment: OCT and OCT-angiography biomarkers of treatment response to anti-VEGF and steroids. *Acta Diabetol*. 2020;57(3):287-296.
42. Boyer DS, Yoon YH, Belfort R, Jr., et al. Three-year, randomized, sham-controlled trial of dexamethasone intravitreal implant in patients with diabetic macular edema. *Ophthalmology*. 2014;121(10):1904-1914.
43. Brown DM, Emanuelli A, Bandello F, et al. KESTREL and KITE: 52-Week Results From Two Phase III Pivotal Trials of Brolucizumab for Diabetic Macular Edema. *Am J Ophthalmol*. 2022;238:157-172.
44. Wyckoff CC, Abreu F, Adamis AP, et al. Efficacy, durability, and safety of intravitreal faricimab with extended dosing up to every 16 weeks in patients with diabetic macular oedema (YOSEMITE and RHINE): two randomised, double-masked, phase 3 trials. *Lancet*. 2022;399(10326):741-755.
45. Amoaku WM, Ghanchi F, Bailey C, et al. Diabetic retinopathy and diabetic macular oedema pathways and management: UK Consensus Working Group. *Eye (Lond)*. 2020;34(Suppl 1):1-51.
46. Baker CW, Glassman AR, Beaulieu WT, et al. Effect of Initial Management With Aflibercept vs Laser Photocoagulation vs Observation on Vision Loss Among Patients With Diabetic Macular Edema Involving the Center of the Macula and Good Visual Acuity: A Randomized Clinical Trial. *Jama*. 2019;321(19):1880-1894.
47. Dugel PU, Campbell JH, Kiss S, et al. Association between early anatomic response to anti-vascular endothelial growth factor therapy and long-term outcome in diabetic macular edema: An Independent Analysis of Protocol I Study Data. *Retina*. 2019;39(1):88-97.
48. Payne JF, Wyckoff CC, Clark WL, Bruce BB, Boyer DS, Brown DM. Long-term outcomes of treat-and-extend ranibizumab with and without navigated laser for diabetic macular oedema: TREX-DME 3-year results. *Br J Ophthalmol*. 2021;105(2):253-257.
49. Kim YC, Shin JP, Pak KY, et al. Two-year outcomes of the treat-and-extend regimen using aflibercept for treating diabetic macular oedema. *Sci Rep*. 2020;10(1):22030.
50. Lim SY, Wong WM, Seah I, et al. Treat and extend regimen for diabetic macular oedema-a systematic review and meta-analysis. *Graefes Arch Clin Exp Ophthalmol*. 2023;261(2):303-315.
51. Sarohia GS, Nanji K, Khan M, et al. Treat-and-extend versus alternate dosing strategies with anti-vascular endothelial growth factor agents to treat center involving diabetic macular edema: A systematic review and meta-analysis of 2,346 eyes. *Surv Ophthalmol*. 2022;67(5):1346-1363.
52. Bressler NM, Beaulieu WT, Maguire MG, et al. Early Response to Anti-Vascular Endothelial Growth Factor and Two-Year Outcomes Among Eyes With Diabetic Macular Edema in Protocol T. *Am J Ophthalmol*. 2018;195:93-100.
53. Bressler NM, Beaulieu WT, Glassman AR, et al. Persistent Macular Thickening Following Intravitreal Aflibercept, Bevacizumab, or Ranibizumab for Central-Involvement Diabetic Macular Edema With Vision Impairment: A Secondary Analysis of a Randomized Clinical Trial. *JAMA Ophthalmol*. 2018;136(3):257-269.
54. Gonzalez VH, Campbell J, Hlekamp NM, et al. Early and Long-Term Responses to Anti-Vascular Endothelial Growth Factor Therapy in Diabetic Macular Edema: Analysis of Protocol I Data. *Am J Ophthalmol*. 2016;172:72-79.
55. Pieramici D, Singh RP, Gibson A, et al. Outcomes of Diabetic Macular Edema Eyes with Limited Early Response in the VISTA and VIVID Studies. *Ophthalmol Retina*. 2018;2(6):558-566.
56. Augustin AJ, Kuppermann BD, Lanzetta P, et al. Dexamethasone intravitreal implant in previously treated patients with diabetic macular edema: subgroup analysis of the MEAD study. *BMC Ophthalmol*. 2015;15:150.
57. Campochiaro PA, Brown DM, Pearson A, et al. Long-term benefit of sustained-delivery fluocinolone acetonide vitreous inserts for diabetic macular edema. *Ophthalmology*. 2011;118(4):626-635.e622.
58. Danis RP, Sadda S, Li XY, Cui H, Hashad Y, Whitcup SM. Anatomical effects of dexamethasone intravitreal implant in diabetic macular oedema: a pooled analysis of 3-year phase III trials. *Br J Ophthalmol*. 2016;100(6):796-801.
59. Maturi RK, Pollack A, Uy HS, et al. Intraocular pressure in patients with diabetic macular edema treated with dexamethasone intravitreal implant in the 3-year MEAD study. *Retina*. 2016;36(6):1143-1152.
60. Maturi RK, Glassman AR, Liu D, et al. Effect of Adding Dexamethasone to Continued Ranibizumab Treatment in Patients With Persistent Diabetic Macular Edema: A DRCR Network Phase 2 Randomized Clinical Trial. *JAMA Ophthalmol*. 2018;136(1):29-38.
61. Campochiaro PA, Brown DM, Pearson A, et al. Sustained delivery fluocinolone acetonide vitreous inserts provide benefit for at least 3 years in patients with diabetic macular edema. *Ophthalmology*. 2012;119(10):2125-2132.
62. Nasrallah FP, Jalkh AE, Van Coppenolle F, et al. The role of the vitreous in diabetic macular edema. *Ophthalmology*. 1988;95(10):1335-1339.
63. Stefansson E, Landers MB, 3rd, Wolbarsht ML. Increased retinal oxygen supply following pan-retinal photocoagulation and vitrectomy and lensectomy. *Trans Am Ophthalmol Soc*. 1981;79:307-334.
64. Haller JA, Qin H, Apte RS, et al. Vitrectomy outcomes in eyes with diabetic macular edema and vitreomacular traction. *Ophthalmology*. 2010;117(6):1087-1093.e1083.