

Subretinal Triamcinolone Acetonide and Transpupillary Thermotherapy in Circumscribed Choroidal Hemangioma. A Case Report

Umanets Mykola, Kustryn Taras, Pasychnikova Nataliya

State Institution «The Filatov Institute of Eye Diseases and Tissue Therapy of the National Academy of Medical Sciences of Ukraine»



First author:
Umanets Mykola, MD, DSc

Corresponding author:
Taras Kustryn, MD, PhD
State Institution «The Filatov Institute of Eye Diseases and Tissue Therapy of the National Academy of Medical Sciences of Ukraine»
Frantsuzkyi Boulevard 49/51
65061 Odesa
Ukraine
E-mail: tkustryn@gmail.com

Submitted to the editorial board: April 9, 2025

Accepted for publication: May 16, 2025

Available on-line: July 8, 2025

The authors declare that no conflict of interest exists in the compilation, theme and subsequent publication of this professional communication, and that it is not supported by any pharmaceutical company. The study has not been submitted to another journal and has not been published elsewhere.

SUMMARY

Purpose: To evaluate the potential use of a combination of subretinal triamcinolone acetonide (TA) injection with transpupillary thermotherapy (TTT) in the treatment of circumscribed choroidal hemangioma (CCH) with exudative retinal detachment.

Case report: The clinical case of a 27-year-old patient demonstrates the treatment of CCH with exudative retinal detachment. We used a combination of subretinal injection of 4 mg preservative-free TA with the simultaneous partial aspiration of subretinal fluid in the first stage. After one week, when the retina was fully attached, TTT of CCH was used in the second stage. At Month 12, visual acuity in the left eye increased from light perception with projection to 20/400. Ultrasonography did not reveal any signs of choroidal masses or retinal detachment. During the follow-up period, 3 sessions of TTT were performed.

Conclusion: A combination of subretinal TA injection with TTT can be an alternative treatment for CCH with exudative retinal detachment.

Key words: circumscribed choroidal hemangioma, exudative retinal detachment, subretinal injection, triamcinolone acetonide, transpupillary thermotherapy

Čes. a slov. Oftal., 82, 2026, No. 2, p. 107–111

INTRODUCTION

Choroidal hemangioma (CCH) is a benign vascular tumor, which is more often localized in the posterior pole of an eye and may cause a decrease of visual acuity by exudative retinal detachment. Clinically, choroidal hemangioma occurs in two forms: diffuse and circumscribed. Symptoms of the disease appear between the second and fourth decade of life and are more common among men [1,2]. CCH leads to the loss of visual functions of the affected eye in almost one-half of cases. CCH presents as a single isolated orange-red-colored choroidal lesion, frequently localized peripapillary or/and in the macular areas. Exudative retinal detachment and cystoid macular edema are common findings in symptomatic CCH [1]. Progression of the exudation can result in neovascular glaucoma. The frequency of enucleation in CCH with neovascular glaucoma is approximately 0.7% [2].

Currently, ultrasonography, fluorescein angiography (FA), indocyanine green angiography and spectral domain optical coherence tomography (SD-OCT) are the preferred diagnostic methods for CCH. The main treatment options for CCH include laser photocoagulation, photodynamic therapy (PDT), transpupillary thermotherapy (TTT) and radiation therapy [2,3]. CCH with exudative retinal detachment has been treated with combinations such as PDT and antiangiogenic therapy, as well as PDT and dexamethasone implant [4,5].

PDT with verteporfin is an effective and safe method of treating patients with CCH [6]. However, the global shortage of verteporfin since July 2021 has further limited its availability in ophthalmological practice [7]. Therefore, the search for alternative methods of treating CCH remains relevant.

In the presented case, we have demonstrated the potential use of a combination of subretinal triamcinolone acetonide (TA) injection and TTT for the treatment of CCH with exudative retinal detachment.

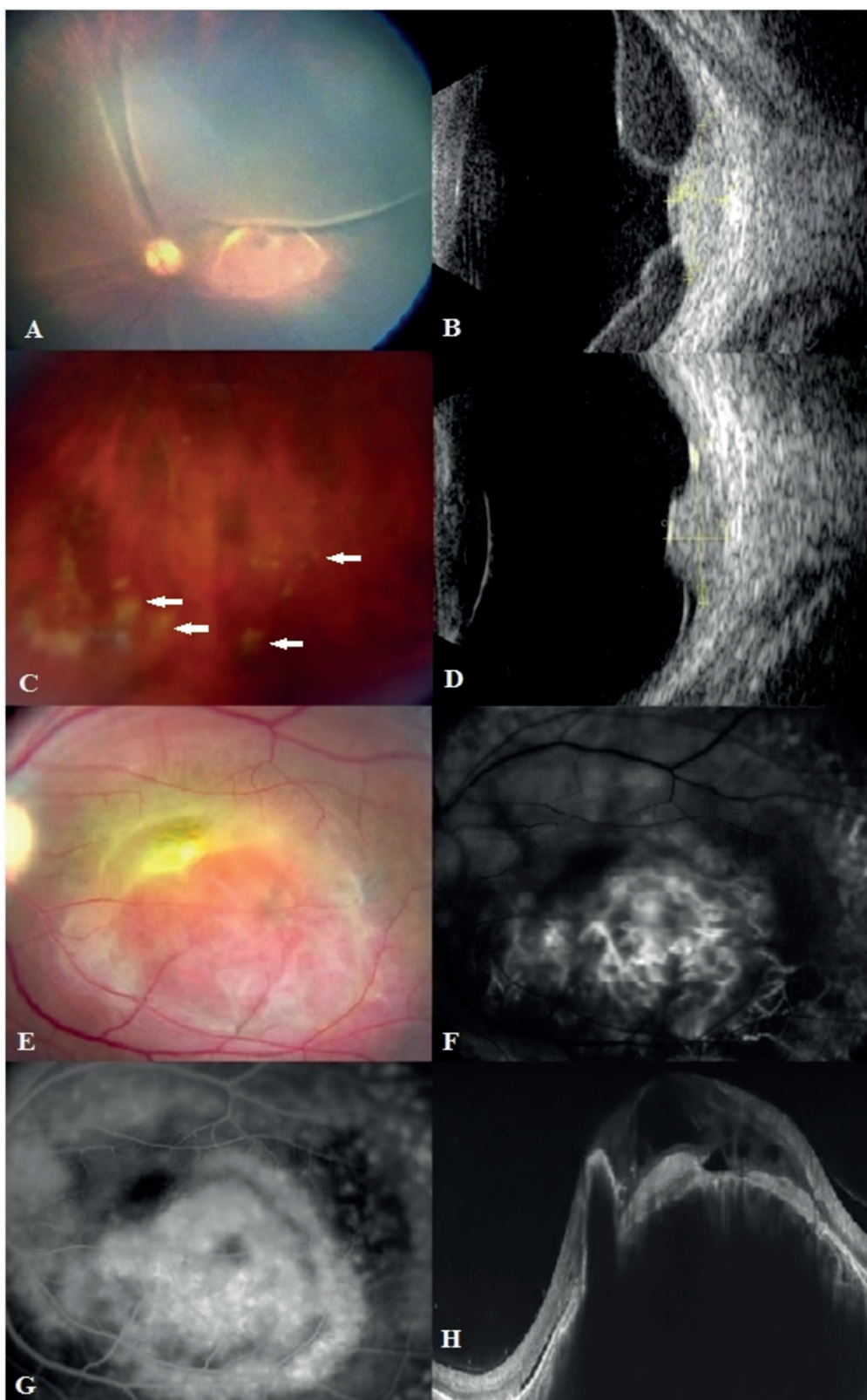


Figure. 1. Multimodal imaging of patient with circumscribed choroidal hemangioma. Before treatment: RetCam fundus photo showed orange lesion located in macula and exudative retinal detachment (A). Ultrasonography revealed a solitary choroidal mass, surrounded by a retinal detachment (B). One week after subretinal injection of TA. Fundus photo showed white subretinal deposit of triamcinolone acetonide (white arrows) (C). Ultrasonography of the eye demonstrated solitary choroidal lesion and residual retinal detachment (D). Fundus photo showed orange lesion located in macula (E). Early phase fluorescein angiography revealed lacy hyperfluorescence of the lesion (F). Late phase fluorescein angiography demonstrated increased hyperfluorescence corresponding to the circumscribed choroidal hemangioma (G). Spectral domain optical coherence tomography showed a single choroidal lesion with the elevation of retinal pigment epithelium-Bruch's membrane complex, intraretinal and subretinal fluid (H)

CASE REPORT

A 27-year-old female presented with complaints of visual impairment and flashes in the left eye over a period of 2 months. Her best-corrected visual acuity (BCVA) was 1.0 in the right eye and light perception with projection in the left eye. Intraocular pressure (IOP) of the left eye according to pneumotonometry was 15 mmHg. Fundus ophthalmoscopy of the left eye revealed a sub-total exudative retinal detachment and an indistinctly defined, rounded orange-red formation in the posterior pole abutting the optic nerve head (Figure 1, A). Ultrasonography of the left eye revealed a solitary choroidal mass abutting the optic nerve head, surrounded by a retinal detachment, measuring 9.9 mm (horizontal basal) × 9.7 mm (vertical basal) × 3.65 mm (height) (Figure 1, B). A subretinal injection of 4 mg preservative-free TA (Kenalog®-40, KRKA, d.d., Novo mesto, Slovenia) was administered for resolution of the exudative retinal detachment. The subretinal injection of TA was performed in the operating room under local anesthesia. Prior to the procedure, the skin around the eyes, eyelids and eyebrows was prepared with 0.5% alcoholic chlorhexidine solution. In addition, an aqueous solution of 5% povidone iodine was instilled into the conjunctival cavity for 30 seconds. The subretinal injection of TA was conducted using an insulin syringe with a 29G needle 6 mm from the limbus in the lower temporal quadrant, in the projection of maximal height of the retinal detachment. After injection of TA, the needle was moved 30° medially and 0.3 ml of subretinal fluid was transsclerally aspirated. One week after the subretinal injection of TA, white subretinal deposits of TA were visualized in the lower quadrant (Figure 1, C). Ultrasonography of the eye revealed a solitary choroidal lesion and a residual retinal detachment (Figure 1, D). Fundus ophthalmoscopy of the left eye indicated a reduction in the exudative retinal detachment (Figure 1, E). During the early phase of fluorescein angiography (FA), lacy hyperfluorescence was observed, which increased in the later phases (Figure 1, F and G). Spectral-domain optical coherence tomography (SD-OCT) revealed a single choroidal lesion, with elevation of the retinal pigment epithelium-Bruch's membrane complex, intraretinal and subretinal fluid (Figure 1, H). BCVA of the left eye was 20/630. After one week, complete retinal attachment occurred. Given the good visualization of the CCH, the patient was treated with TTT, which consisted of four consecutive daily laser treatments [8]. TTT was performed under dilated pupil and local anesthesia. A diode laser with a wavelength of 810 nm was used for the TTT (Vitra 810, Quantel Medical, Courron d'Auvergne, France). An ocular Mainster (Standard) Focal/Grid contact lens was used to focus the laser beam on the treated area. The parameters for the laser radiation during TTT were as follows: the spot size was 3 mm, exposure time was set to 60 sec and the average laser power was 500 mW.

At Month 12, BCVA of the left eye was 20/400. IOP of the left eye, as measured by pneumotonometry, was 17.0 mm Hg. The optical media of the eye (cornea, aqueous humor in the anterior chamber, lens and vitreous) remained transparent. Fundus examination of the left eye revealed an atrophic focus in the posterior pole (Figure 2, A). Ultrasonography did not detect any choroidal mass or retinal detachment in the left eye (Figure 2, B). FA revealed hyperfluorescence in the early and late phases, associated with atrophy of the retinal pigment epithelium, with no evidence of tumor activity detected (Figure 2, C and D). SD-OCT showed a decrease in elevation of the retinal pigment epithelium-Bruch's membrane complex and complete resolution of intraretinal and subretinal fluid (Figure 2, E).

DISCUSSION

PDT and brachytherapy are commonly considered the most effective methods for treating CCH. However, these methods have some limitations [2]. TTT serves as an alternative treatment method for CCH. TTT causes hyperthermia and blood vessel occlusion with minimal damage to the surrounding retina. This leads to tumor regression and resolution of the subretinal fluid. TTT is used for tumors less than 10 mm in diameter and less than 4 mm in height. However, the efficacy of TTT depends not only on the size of the hemangioma, but also on the presence of an exudative retinal detachment, which can reduce tumor visualization and disrupt the focusing of the laser beam. Complications associated with this treatment may include retinal vein occlusion, recurrent macular edema and subretinal fibrosis [9].

TA has a pronounced anti-inflammatory activity and angiostatic effects. TA reduced the permeability of the vascular wall and inhibited the migration of endothelial cells involved in the formation of a newly formed vessel [10]. TA has previously been applied in ophthalmic oncology for the treatment of exudative retinal detachment associated with uveal melanoma. Parrozzani et al. demonstrated that intravitreal TA injection promotes the regression of exudative retinal detachment in 69% of patients with uveal melanoma [11]. However, intravitreal TA injection may lead to complications, such as increased intraocular pressure, steroid cataract, pseudophycon, and endophthalmitis, which can limit further treatment [12,13].

An animal study demonstrated that subretinal TA injection did not alter the multifocal electroretinogram response and retinal structure on histological examination [14]. In a clinical study, Kozak et al. presented the results of a subretinal injection of 2 mg preservative-free TA during vitrectomy in patients with exudative age-related macular degeneration. According to the authors, subretinal administration of TA preserved visual acuity without increasing IOP [15].

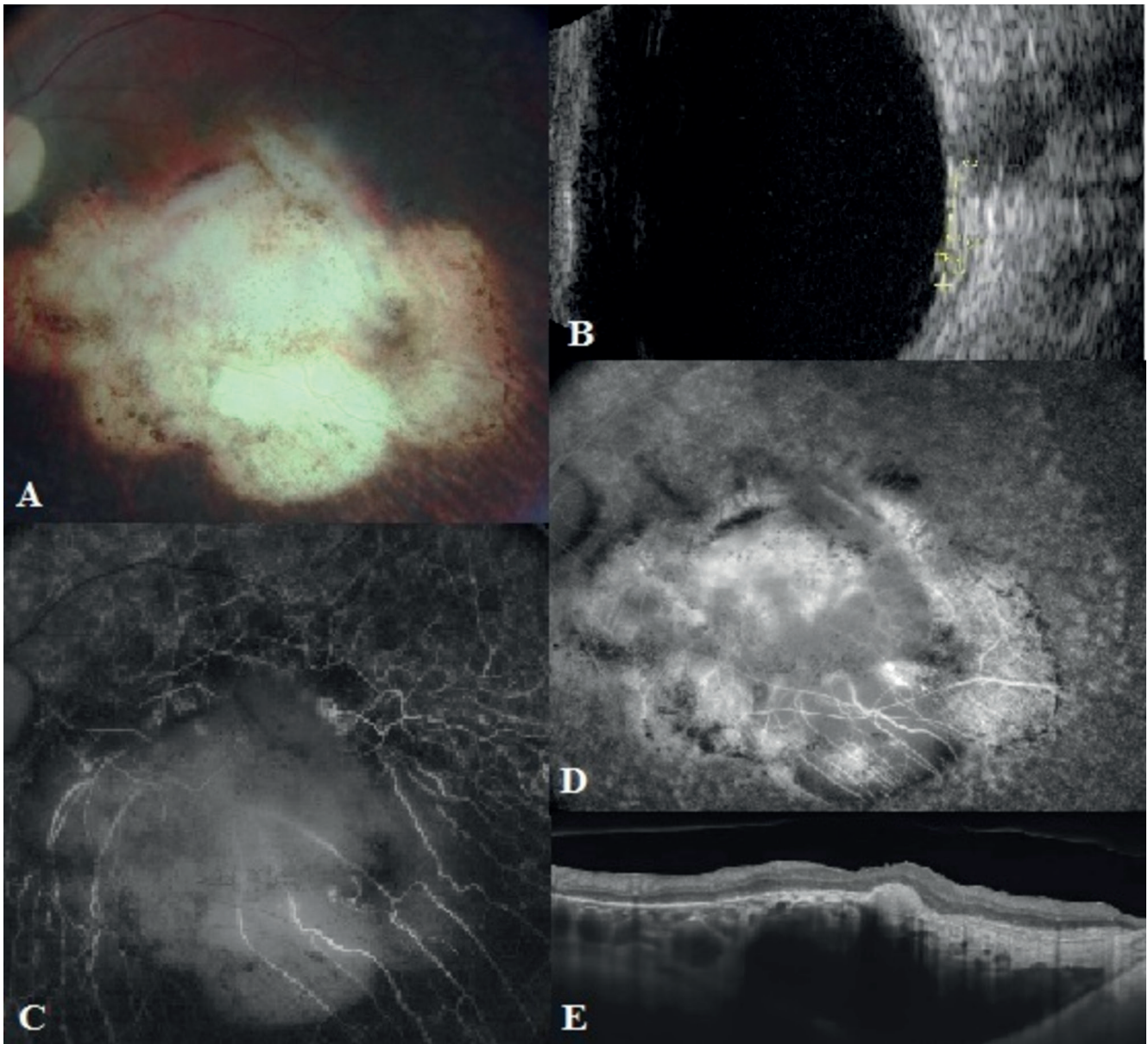


Figure. 2. At Month 12, after subretinal triamcinolone acetate and transpupillary thermotherapy: Fundus photo showed atrophic focus in the posterior pole (A). Ultrasonography showed a regressed circumscribed choroidal hemangioma with complete resolution of the exudative retinal detachment (B). In early (C) and late (D) phases fluorescein angiography revealed hyperfluorescence associated with atrophy of the retinal pigment epithelium. Spectral domain optical coherence demonstrated a decrease in elevation of the Bruch pigment epithelium-membrane complex, complete resorption of intraretinal and subretinal fluid (E)

In our clinical case, the patient already presented with exudative retinal detachment associated with CCH localized in the posterior pole. Brachytherapy is often used to treat limited choroidal hemangioma with extensive subretinal exudation, since the presence of detachment makes access difficult for photocoagulation, TTT, and PDT [16]. However, in our case, the patient refused to undergo brachytherapy, and the limited availability of verteporfin in Ukraine further restricted our choice of treatment methods. For this reason, it was decided to proceed with a combined treatment approach. Subretinal injection of TA was used for resorption of the exu-

dative retinal detachment, while TTT was performed for regression of the CCH. The use of a subretinal TA injection contributed to the reattachment of the exudative detachment one week after the injection, while regression of CCH occurred after TTT. In our case, the use of subretinal TA injection and TTT demonstrated the preservation of visual acuity.

A combination of subretinal TA injection and TTT may be an alternative treatment for CCH with exudative retinal detachment. Further studies are needed to establish the efficacy and safety of subretinal injection of TA combined with TTT in CCH with exudative retinal detachment.

REFERENCES

1. Singh AD, Kaiser PK, Sears JE. Choroidal hemangioma. *Ophthalmol Clin North Am.* 2005;18(1):151-161.
2. Shields CL, Dalvin LA, Lim LS, et al. Circumscribed Choroidal Hemangioma: Visual Outcome in the Pre-Photodynamic Therapy Era versus Photodynamic Therapy Era in 458 Cases. *Ophthalmol Retina.* 2020;4(1):100-110.
3. Korol A, Nasinnyk I. *Retina Lasers in Ophthalmology* In: Grzybowski, A., Luttrull, J.K., Kozak, I. (eds). Springer, Cham; c2023. Chapter 8, Laser Treatment in Intraocular Tumors; p. 183-194.
4. Hsu CC, Yang CS, Peng CH, Lee FL, Lee SM. Combination photodynamic therapy and intravitreal bevacizumab used to treat circumscribed choroidal hemangioma. *J Chin Med Assoc.* 2011;74(10):473-477.
5. Bazin L, Gambrelle J. Traitement combiné par photothérapie dynamique et implant intravitréen de dexaméthasone (Ozurdex[®]) pour un hémangiome choroïdien circonscrit [Combined treatment with photodynamic therapy and intravitreal dexamethasone implant (Ozurdex[®]) for circumscribed choroidal hemangioma]. *J Fr Ophtalmol.* 2012;35(10):798-802. French.
6. Blasi MA, Tiberti AC, Scupola A, et al. Photodynamic therapy with verteporfin for symptomatic circumscribed choroidal hemangioma: five-year outcomes. *Ophthalmology.* 2010; 117(8):1630-1637.
7. Sirks MJ, van Dijk EHC, Rosenberg N, et al. Clinical impact of the worldwide shortage of verteporfin (Visudyne[®]) on ophthalmic care. *Acta Ophthalmol.* 2022;100(7):e1522-e1532.
8. Tsukanova IV, Poliakova SI, Naumenko VO, et al. Efficacy of 810-nm diode laser transpupillary thermotherapy delivered using the methodology developed for small (T1) choroidal melanomas. *J ophthalmol (Ukraine).* 2019;3:36-40.
9. Gunduz K. Transpupillary thermotherapy in the management of circumscribed choroidal hemangioma. *Surv Ophthalmol.* 2004;49:316-326.
10. Wang YS, Friedrichs U, Eichler W, Hoffmann S, Wiedemann P. Inhibitory effects of triamcinolone acetonide on bFGF-induced migration and tube formation in choroidal microvascular endothelial cells. *Graefes Arch Clin Exp Ophthalmol.* 2002;240:42-48.
11. Parrozzani R, Pilotto E, Dario A, Miglionico G, Midena E. Intravitreal triamcinolone versus intravitreal bevacizumab in the treatment of exudative retinal detachment secondary to posterior uveal melanoma. *Am J Ophthalmol.* 2013;155(1):127-133.
12. Tao Y, Jonas JB. Intravitreal triamcinolone. *Ophthalmologica.* 2011;225(1):1-20.
13. Kustryn T, Nasinnyk I, Nevskaya A, Zadorozhnyy O, Korol A. Changes in structural and functional retinal features resulting from the effect of a long-acting steroid in serous PED associated with AMD: a 36-month follow-up study. *J ophthalmol (Ukraine).* 2016;5:28-34.
14. Ejstrup R, la Cour M, Heegaard S, Kiilgaard JF. Toxicity profiles of subretinal indocyanine green, Brilliant Blue G, and triamcinolone acetonide: a comparative study. *Graefes Arch Clin Exp Ophthalmol.* 2012;250(5):669-677.
15. Kozak I, Cheng L, Falkenstein I, Tammewar AM, Freeman WR. Evaluation of subretinal triamcinolone acetonide in patients with exudative age-related macular degeneration. *J Ocul Pharmacol Ther.* 2007;23(1):46-53.
16. Aizman A, Finger PT, Shabto U, et al. Palladium 103 (103Pd) plaque radiation therapy for circumscribed choroidal hemangioma with retinal detachment. *Arch Ophthalmol.* 2004;122: 1652-1656.