

Uveitis associated with juvenile idiopathic arthritis (JIA) and JIA-like uveitis in pediatric patients

Bártková Dominika¹, Timkovič Juraj^{1,2},
Kolarčíková Veronika¹, Pískovský Tomáš^{3,4},
Polách Ondřej¹, Němčanský Jan^{1,2}

¹Department of Ophthalmology, University Hospital Ostrava, Czech Republic

²Department of Craniofacial Surgery, Faculty of Medicine, University of Ostrava, Czech Republic

³Department of Pediatrics, University Hospital Ostrava, Czech Republic

⁴Department of Pediatrics and Neonatal Care, Faculty of Medicine, University of Ostrava, Czech Republic

Submitted to the editorial board: January 10, 2024

Accepted for publication: February 7, 2025

Available on-line: April 10, 2025

The authors of the study declare that no conflict of interests exists in the compilation, theme and subsequent publication of this professional communication, and that it is not supported by any pharmaceuticals company. The study has not been submitted to any other journal or printed elsewhere, with the exception of congress abstracts and recommended procedures



MUDr. Dominika Bártková

Correspondence address:

Oční klinika FN Ostrava

17. listopadu 1790

708 52 Ostrava

Česká republika

E-mail: dominika.bartkova2@fno.cz

SUMMARY

Aims: To evaluate the prevalence of uveitis and ocular complications in children with juvenile idiopathic arthritis (JIA) and “JIA-like” form. To determine the onset of ocular symptoms in relation to the diagnosis of the underlying disease and identify the most common predictive factor preceding the onset of uveitis.

Materials and Methods: Retrospective analysis of medical records of children with JIA and JIA-like uveitis monitored at the Pediatric Rheumatology and Ophthalmology Clinic at the University Hospital Ostrava between 2016–2024. Observed parameters included the child's age at the time of diagnosis of JIA or JIA-like uveitis, laboratory tests, ocular findings, age at the onset of uveitis symptoms, time correlation with the diagnosis of the underlying disease, ocular complications of recurrent uveitis attacks and overall treatment of the underlying disease.

Results: There were 27 children in the group with confirmed JIA, with an average age of 5 years. Ten patients were diagnosed with anterior or posterior uveitis. The average age at the time of JIA diagnosis was 6 years. The mean time interval from JIA diagnosis to the appearance of pathological ocular findings was 38 months. Ocular complications were recorded in 50% of children, most commonly cataracts (40%). All children with uveitis were laboratory positive for ANA antibodies.

There were 8 patients with JIA-like uveitis, with an average age of 9 years. All children showed signs of anterior or posterior uveitis, which was manifested on average at 8.5 years of age. Exclusion of JIA diagnosis was established on average 6 months after the appearance of ocular pathology. Ocular complications were observed in 88% of children, most frequently posterior synechiae (63%). Laboratory findings showed ANA antibody positivity in 88% of children with uveitis.

Conclusion: Regular ophthalmological examinations in JIA patients are essential due to the potential occurrence of complications, which are more frequent in young females with JIA-like uveitis and ANA antibody positivity.

Key words: juvenile idiopathic arthritis, uveitis, childhood, diagnosis, treatment

Čes. a slov. Oftal., 81, 2025, No. x, p.

INTRODUCTION

Juvenile idiopathic arthritis (JIA) is a chronic autoimmune inflammatory disorder of unknown etiology [1]. The first symptoms of the disease appear before 16 years of age, in which arthritis occurs in 97–99% of children with JIA. The main symptom is affliction of the joints persisting continuously for at least 6 weeks, which is characterized by painful intumescence with limited mobility of the joints caused by exudation and inflammatory swelling of the synovia. Not only the joints are affected, extraarticular manifestations are also very common [1]. The incidence

of JIA is stated within the range of 5–18/100 000, prevalence from 30–150/100 000 (the wide dispersion is caused by the different criteria in individual countries). According to the available sources, in 2017 approximately 2 069 246 patients aged under 16 years were suffering from JIA worldwide, in which the prevalence was highest in South Asia, followed by Africa, Europe and Oceania. According to the results of the majority of studies, girls are affected more frequently than boys in a ratio of 2–3:1 [1,2].

JIA probably occurs upon a background of a combination of immunogenetic predisposition and a triggering factor. HLA and non-HLA genes are manifested in immunogenetic

predisposition. Several studies have confirmed an association of JIA with HLA class I (HLA A-2 and HLA B27) and HLA class II genes (HLADRB1 and HLA DP), and thereby emphasized the significance of T-cells in the pathophysiology of this disorder. Primary among the non-HLA genes in connection with JIA are PTPN22, SLC11A6, WISP3, TNF α and MIF. Potential triggering factors of the pathology are considered to include stressful situations, pharmaceuticals, UV radiation and infection (Epstein-Barr virus, rubeola, parvovirus B19) [1,3].

JIA covers a group of disorders characterized by certain clinical and laboratory traits. As previously mentioned, in almost all cases it is linked with arthritis, which is manifested in swelling of the joints and impairment of their mobility due to inflammatory exudation. The affected joint is usually pale but warm to the touch, typically stiff, most often in the morning after awakening or after rest. The number of affected joints is also evaluated, which contributes to the diagnosis of the form of JIA. Daily recurring fevers are typical. In the blood count we may find thrombocytosis with anemia, increased sedimentation of erythrocytes and also elevated acute phase proteins. The finding of increased sedimentation at the time of manifestations of polyarthritis or oligoarthritis is associated with an increased risk of the development of uveitis [5]. From the immunological examinations we determine applicable positivity of rheumatoid factor (RF) and antinuclear antibodies (ANA) in the IgM class (these are rather prognostic and classification parameters). Another useful examination is analysis of the joint exudate, evaluating its appearance, viscosity, color and number of granulocytes with leukocytes. Of imaging examinations the most frequently used is native X-ray of bones and joints as well as MR for good visualization of cartilage, ultrasonography for monitoring the swelling and exudation, and also isotope examination [1].

The individual forms of JIA include systemic arthritis, seronegative polyarthritis (negative rheumatoid factor – RF) seropositive polyarthritis (positive RF), oligoarthritis, arthritis with enthesitis, psoriatic arthritis and other forms of arthritis.

Uveitis is most commonly associated with oligoarthritis, seronegative polyarthritis and psoriatic arthritis (in this case it is of a chronic character), as well as with enthesitis (mostly as acute anterior uveitis). It also depends on positivity of rheumatoid antibodies, sex (female sex constitutes a higher risk), time of diagnosis of the disorder and also the time of onset of the first ocular complaints [1,3–5].

JIA-like uveitis is not a defined clinical unit. It is the name given to a group of chronic forms of uveitis in which positivity of rheumatoid antibodies or antigens is present (RF, ANA, ANCA, HLA B27 and others), even if typical general symptoms of JIA are absent (no affliction of joints, typical transient skin rash). In the treatment of the condition we proceed as in the case of classic uveitis, and if complications occur or if it proves impossible to manage uveitis only with local therapy we administer systemic immunosuppression. As a rule this prevents manifestations of general pathology, and consequently the term JIA-like uveitis is imprecise.

Therapy of JIA is based on interdisciplinary cooperation, ideally of an ophthalmologist and pediatric rheuma-

tologist. Early diagnosis and commencement of therapy is a prerequisite for the successful management of this chronic disease.

Treatment is not only targeted at arthritis but also at non-joint manifestations of the pathology such as uveitis, osteopenia, growth disorders or depression.

The drugs of first choice in the initial stages of JIA are non-steroidal anti-inflammatory drugs (NSAIDs) such as ibuprofen, naproxen and diclofenac. Corticosteroids are also used, both systemically (in the form of pulse therapy with methylprednisolone of up to 30 mg/kg/dose/day for 3 to 5 days according to the activity of the pathology or in oral form with prednisone or methylprednisolone) and locally intraarticularly and in the form of drops upon ocular manifestation of the pathology. Methotrexate is the drug of first choice in systemic therapy. It is used in a “low dosing” regimen of 10 to 15 mg/m²/week, while the maximum dose is 25 mg per week. A positive response to this treatment is recorded in up to 70% of pediatric patients, though unfortunately discontinuation of the therapy is frequently followed by relapses. As a result it is recommended to continue with therapy for a further approximately two years following the disappearance of the last symptoms of the disease. A disadvantage is its hepatotoxicity and nematotoxicity, due to which its administration must be discontinued in some patients. Consequently it is essential to ensure rigorous laboratory monitoring and also substitution with folic acid. In the case of intolerance or insufficient therapeutic effect of methotrexate, biological treatment is commenced. Anti-TNF preparations are used such as adalimumab, infliximab and golimumab. Due to the high rate or relapses of uveitis, etanercept is not suitable in the treatment of ocular complications. If the effect of therapy is insufficient it is appropriate to measure the level of the pharmaceutical and also to examine the antibodies against the given biological agent. On this basis it is then possible to increase the dose of the drug or reduce the interval between individual doses if applicable. In the case of insufficient effectiveness of anti-TNF preparations, the drugs of choice are tocilizumab, abatacept and rituximab [1,5].

Non-pharmacological therapy includes rehabilitation, rheumatic surgical treatment and psychosocial therapy [1].

Ocular manifestations of JIA / JIA-like uveitis and treatment thereof

In most cases the condition concerns asymptomatic bilateral non-granulomatous uveitis of a chronic character. In isolated cases granulomatous uveitis also has been described, mainly in the Afro-Caribbean population [8]. It most frequently concerns anterior uveitis, although intermediary (approx. 9%), posterior (1%) and panuveitis (7%) have also been described in the literature [8]. A typical manifestation is cellular reaction in the anterior chamber and anterior vitreous, depending on the level of activity, and subsequent formation of posterior synechiae. Complications may then be zonular keratopathy, cataract (Figure 1), edema of the papilla and macula (Figure 2), vasculitis, secondary glaucoma and hypotonia [6].

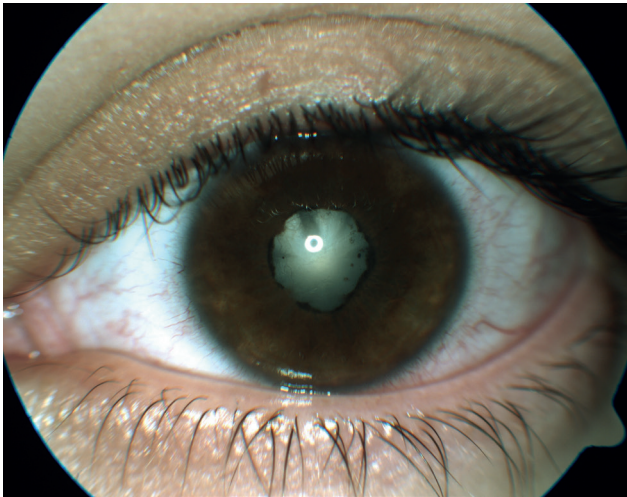


Figure 1. Complicated cataract and nearly circular posterior synechiae in a patient with polyarticular form of JIA
JIA – Juvenile idiopathic arthritis

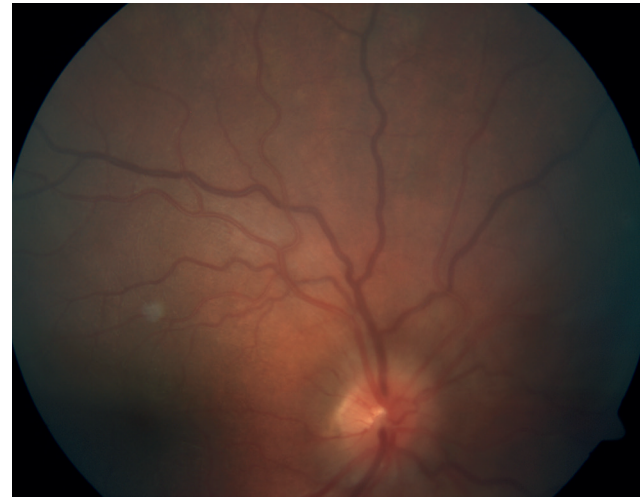


Figure 2. Optic disc edema in patient with JIA-like uveitis, ANA antibodies are weakly positive
JIA – Juvenile idiopathic arthritis, ANA – antinuclear antibodies

Therapy of uveitis itself incorporates topical application of steroids in the form of dexamethasone drops and cream, as well as mydriatic agents (1% tropicamide or 2–4% homatropine bromide). In the chronic phase we may consider the application of weak steroids. Non-steroidal anti-rheumatic drugs are only a supplementary treatment. If no pacification of uveitis takes place or if it is reactivated less than 3 months after the first attack, it is suitable to administer systemic immunosuppression [5].

This issue is described synoptically in the publication Recommendations for Diagnosis and Treatment of Uveitis in Association with Juvenile Idiopathic Arthritis: Czech-Slovak Adaptation of the European SHARE Recommendations, which was compiled on the basis of a consensus among ophthalmologists focusing on the issue of uveitis and pediatric rheumatologists.

Aim

The main aim of the submitted study is to evaluate the frequency of uveitis, its clinical manifestations and the incidence of potential ocular complications in pediatric patients with juvenile idiopathic arthritis and JIA-like form defined as positivity of ANA/ANCA/HLA B27/HLA B51 antibodies / antigen), without affliction of joints, temperatures or rashes of unclear origin. A secondary objective is to determine the time of onset of the ocular complaints in relation to the time of diagnosis of the underlying pathology, and to determine possible predictive factors preceding the onset of uveitis.

COHORT AND METHOD

A retrospective analysis was conducted of the medical records of all the children with JIA and JIA-like form of uveitis monitored at the Pediatric Rheumatology and Ophthalmology Clinic at the University Hospital Ostrava (FNO) between 2016–2024. A comprehensive eye examination was conducted on all the children, incorporating evaluation of best

corrected visual acuity (BCVA) on a Snellen chart (Medico – OTS, s.r.o., Hradec Králové, Czech Republic), intraocular pressure (IOP) with the aid of an automatic tonometer Tonoref III (Nidek, Gamagori, Japan), and examination of the anterior and posterior segment of the eye on a slit lamp CSO – SL 9900 (CSO, Scandicci, Italy). In the case of those children with limited cooperation, examination of the child was conducted in a recumbent position with the use of a manual slit lamp PSL Classic (Keeler, Windsor, England) and indirect ophthalmoscope Omega 600 (Heine, Gilching, Germany). Any changes on the anterior and posterior segment of both eyes were documented with the aid of a camera Zeiss FF450+IR (Carl Zeiss Meditec AG, Jena, Germany). Any applicable structural changes on the retina were objectified with the aid of the instrument OCT Spectralis (Heidelberg Engineering GmbH, Heidelberg, Germany).

The observed parameters included patient age at the time of determination of the diagnosis of JIA or JIA-like form, age at the time of the first ocular symptoms of uveitis and the time correlation with the diagnosis of the underlying disease, laboratory parameters (panels of specific antibodies and antigens), comprehensive ophthalmological finding, ocular complications of recurrent uveitis attacks of uveitis (zonular keratopathy, posterior synechiae, cataract, vitritis, optic nerve papilledema, macular edema, vasculitis and secondary glaucoma) and type of treatment of the underlying disease.

The numerical variables were described with the aid of methods of descriptive statistics (mean, median, interval, standard deviation). The categorical variables were described with the aid of absolute and relative frequencies (%).

In order to determine the statistical significance of the compared visual acuity at the beginning and at the end of the observation period we used a Student t-test (statistical program R, version 4.3.1, The R Foundation for Statistical Computing, Vienna, Austria). The indicator of statistical significance was the value $P < 0.05$.

RESULTS

A total of 35 children with JIA and JIA-like form of uveitis were treated at our center during the observation period. The average age of the children at the time of the first ocular examination was 6 years (median 6 years, interval 1–15 years, SD 3.69). Girls predominated within the cohort, numbering 23 (66%), compared with 12 boys (34%). The average observation period was 32 months (median 30 months, interval 2–103 months, SD 20.5).

The mean value of best corrected visual acuity (BCVA) in the children in our cohort was 0.8 upon entry (median 1, dispersion 0.16–1, SD 0.2), at the end of the observation period 1 (median 1, dispersion 0.16–1, SD 0.1). The difference between BCVA upon entry and at the end of the observation period was statistically significant ($p = 0.00035$).

The group of patients diagnosed with JIA comprised a total of 27 children, of whom 18 were girls (67%) and 9 were boys (33%), the mean age was 5 years (median 4 years, interval 1–15 years, SD 3.5). A form of anterior or posterior uveitis was diagnosed in 10 patients (37%), of whom 60% were girls. The average age at the time of determination of the diagnosis was 6 years. Of these 10 children with manifested uveitis, 5 had polyarticular form (50%), 4 oligoarticular (40%) and one patient had systemic JIA (10%). In this group we furthermore examined the time of diagnosis of the general pathology in relation to the onset of uveitis. The ocular manifestations preceded the general complaints in only one patient, appearing 4 months before the diagnosis of JIA. In the remaining 9 children the manifestation and diagnosis of JIA preceded the ocular inflammation, in which the average time from determination of the underlying diagnosis to the discovery of the pathological ocular finding was 38 months (median 38, interval 6–92 months, SD 30.54) (Table 1).

We recorded ocular complications in 50% of the children (Table 2). This most frequently concerned cataract (40%) and posterior synechiae (30%), followed by zonular keratopathy (20%), secondary glaucoma (20%), papilledema (10%), macular edema (10%) (Figures 3 and 4) and vasculitis (10%) (Figure 5). The complications occurred in various combinations.

In 27 children (78%) we determined ANA positivity of antibodies, followed by HLA B27 positivity in 14%. Five patients recorded negative findings for all the antibodies and antigens in laboratory tests. Rheumatoid factor was negative in all the children, moreover we did not record association with HLA B51 in any of the children (Table 3). In the group with manifested uveitis, ANA positivity was present in all the children.

A total of 20 children with JIA uveitis were treated with methotrexate, while 11 children underwent corticosteroid and biological therapy. In the remaining cases general therapy was not required during the given observation period, and activity of the inflammation was suppressed locally. An overview of systemic therapy and its combinations in patients with JIA is illustrated in Graph 1.

The group in which uveitis did not develop during the given observation period comprised 17 children, of whom 12 were girls (71%) and 5 were boys (29%). The average age of diagnosis of JIA was 3.7 years (median 2, interval

Table 1. Onset time of ocular complications from JIA diagnosis, n-number of months, p-average, result highlighted in bold. In one patient, uveitis manifested before the diagnosis of the systemic disease

Patient	n
1	38
2	50
3	47
4	6
5	12
6	92
7	12
8	38
9	44
p	37.7

Table 2. Overview of the frequency of ocular complications in patients with uveitis associated with juvenile idiopathic arthritis

Complications	Quantity	%
cataract	4	40 %
posterior synechiae	3	30 %
band keratopathy	2	20 %
secondary glaucoma	2	20 %
papilledema	1	10 %
macular edema	1	10 %
vasculitis	1	10 %

JIA – Juvenile idiopathic arthritis

Table 3. Frequency of antibody/antigen positivity in 27 patients with JIA (three patients were both ANA and HLAB27 positive while five patients were negative for all parameters)

Positivity for antibodies/antigen	Quantity	%
ANA	21	78 %
RF	0	0 %
HLA B27	4	14 %
HLA B51	0	0 %

JIA – Juvenile idiopathic arthritis, ANA – antinuclear antibodies, RF – rheumatoid factor, HLA B27 – human leukocyte antigen B27

1–8 years, SD 2.49). Oligoarticular form of JIA predominated (total 8 children), followed by polyarticular form in 17 children and systemic form in 2 patients. Positive ANA antibodies were present in 10 children (60%). The average age at the time of the first ocular examination at our center was 4.4 years (median 3, interval 1–9 years, SD 2.8).

The group of JIA-like uveitis comprised a total of 8 children, of whom 5 were girls (63%) and 3 were boys (37%). The average age at the time of the first examination was 9 years (median 10 years, interval 4–12 years, SD 2.55), and uveitis was manifested on average at 8.5 years of age (median 8.5, interval 3–12 years, SD 2.74). Exclusion of general joint affliction (i.e. exclusion of diagnosis of JIA and confirmation of JIA-like uveitis) was deter-

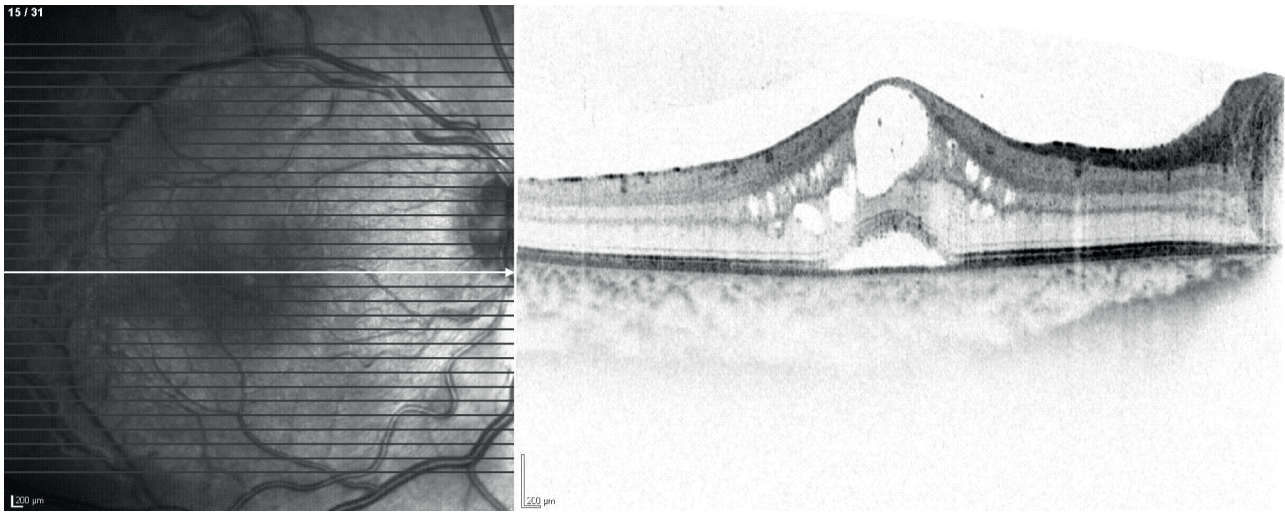


Figure 3. Cystoid macular edema and serous neuroablation of the center in a patient with the oligoarticular form of JIA
JIA – Juvenile idiopathic arthritis

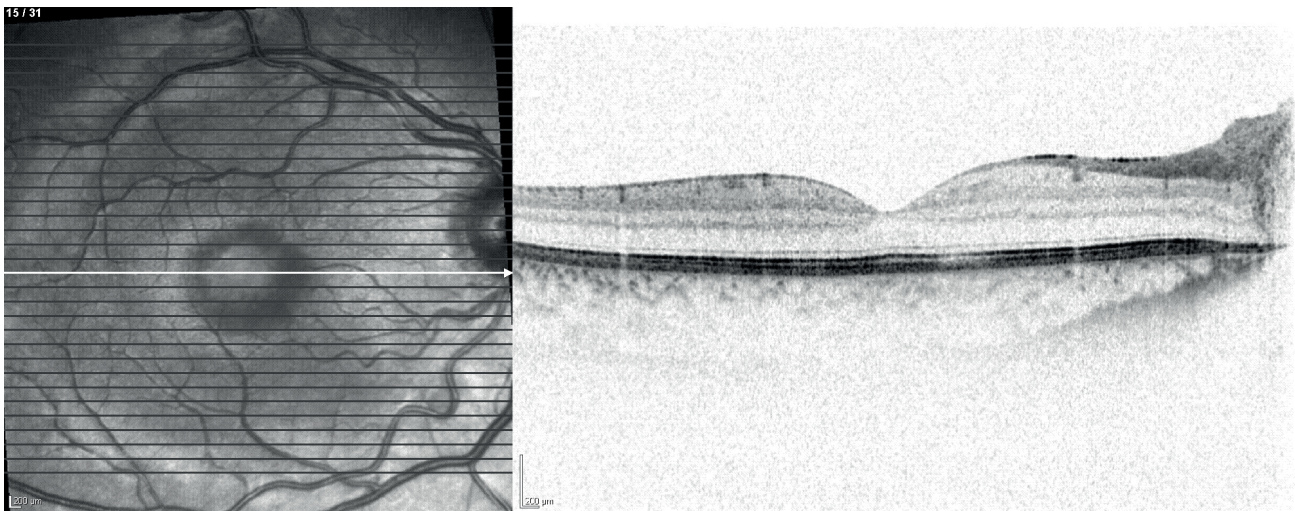
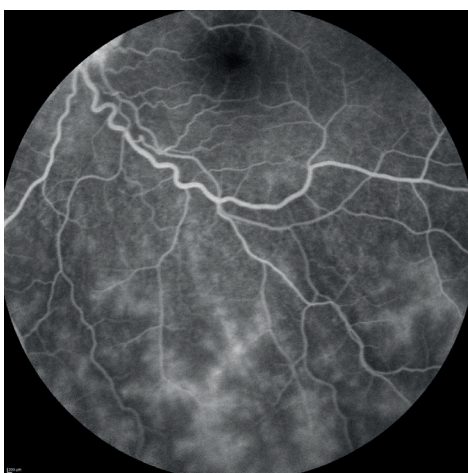
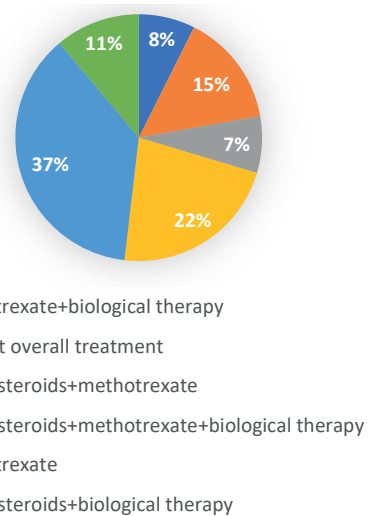


Figure 4. Follow-up OCT of the same patient 3 months after pulse therapy with methylprednisolone and subsequent conversion to corticosteroids per os, treatment further potentiated by methotrexate



Obrázek 5. Evidence of vasculitis in a patient with JIA uveitis (polyarticular form) using fluorescein angiography
JIA – Juvenile idiopathic arthritis



Graph 1. Overview of systemic therapy and its combinations in patients with JIA
JIA – Juvenile idiopathic arthritis

mined by a pediatric rheumatologist on average 5.8 months (median 4.5, interval 2–14 months, SD 3.4) after the discovery of the ocular finding (Table 4). Ocular complications developed in 7 patients in various combinations, in which the most common were posterior synechiae (63% of children), followed by papilledema (50%), secondary glaucoma (38%), zonular keratopathy (25%), vitritis (25%) and macular edema (25%) (Table 5). Pure ANA positivity was present in 75% of patients, in one patient there was weak positivity of ANA antibodies, in one patient borderline with concurrent positivity of HLA B51 antigen, and one patient was purely HLA B27 positive. Rheumatoid factor (RF) was negative in all the patients (Table 6). Corticosteroid therapy (most frequently used as “bridge therapy”) was applied to 5 children, while 7 children underwent treatment with methotrexate and 2 children underwent biological treatment (with adalimumab). General therapy was administered in various combinations (Graph 2).

Table 4. Time to exclude systemic involvement from the onset of ocular pathology, n-number of months, p-average, result highlighted in bold

Patient	n
1	4
2	5
3	7
4	6
5	4
6	2
7	14
8	4
p	5.8

Table 5. Overview of ocular complications in patients with JIA-like uveitis

Complication	Quantity	%
posterior synechiae	5	62.5 %
papilledema	4	50 %
secondary glaucoma	3	37.5 %
vitritis	2	25 %
macular edema	2	25 %
band keratopathy	2	25 %

JIA – Juvenile idiopathic arthritis

Table 6. Frequency of positivity for individual antibodies and antigens in JIA-like uveitis group (including weakly positive and borderline ANA values)

Positivity for antibodies/antigen	Quantity	%
ANA	7	87.5 %
RF	0	0 %
HLA B27	1	12.5 %
HLA B51	1	12.5 %

JIA – Juvenile idiopathic arthritis, ANA – antinuclear antibodies, RF – rheumatoid factor, HLA B27 – human leukocyte antigen B27

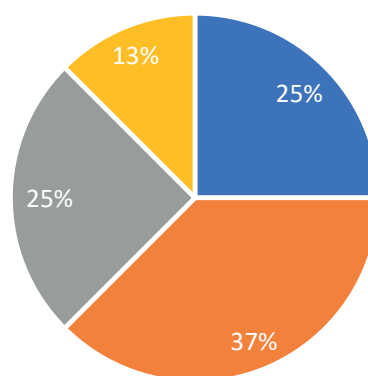
DISCUSSION

A total of 10 children out of 27 (i.e. 37%) in the group diagnosed with JIA had uveitis. On average arthritis appeared at the age of 3 years. In the available literature it is stated that if arthritis is manifested before the 5th year of life, it is far more commonly linked with uveitis [7]. In the group of 17 children with confirmed JIA but without ocular inflammation, arthritis was diagnosed on average at the age of 4 years. However, there was a relatively large number of children in this group whose age at the time of the first ocular examination was 1 or 2 years, and it is therefore possible that uveitis had not had the chance to manifest itself within the given observation period.

According to Heiligenhaus et al., inflammation of the anterior or posterior part of the eye most frequently develops between 4 and 6 years of age. In our cohort the average age of the children with uveitis upon a background of JIA was 6 years, and it was manifested in 90% of the affected patients approximately 3 years after the determination of the diagnosis of JIA. Ocular complications preceded arthritis in only one of the patients. Heiligenhaus et al. state that in 50% of patients uveitis appears shortly before or up to 5 months after the symptoms of arthritis, in 75% within one year and in 90% within 4 years. Uveitis is manifested before or five or more years after the onset of JIA in only approximately 3–5% of patients [7].

Girls predominated in the group with JIA uveitis (constituting 60%). It is known that female sex is one of the risk factors in the onset of uveitis upon a background of JIA (associated with it in 75–80% of cases) [7].

In our cohort the largest number of children had uveitis upon a background of polyarticular form of JIA (50%), followed by oligoarticular (40%) and one patient had systemic JIA (10%). The literature states the highest number of cases of uveitis in



- corticosteroids+methotrexate+biological therapy
- corticosteroids+methotrexate
- methotrexate
- without overall treatment

Graph 2. Overview of systemic therapy in patients with JIA-like uveitis
JIA – Juvenile idiopathic arthritis

association with oligoarticular form. This discrepancy is probably caused by the small number of patients in our cohort [7].

The most common determined complication of the chronic course of uveitis upon a background of JIA in our cohort was cataract. However, here it is necessary to consider local and systemic therapy with corticosteroids. Three out of four patients with cataract were treated with corticoids (both pulses and in tablet form and locally in drops), only one patient was treated with methotrexate and biological therapy.

The incidence of uveitis upon a background of JIA is still linked with positivity of antinuclear antibodies in 70–90% of cases [7]. All 10 patients with uveitis in our cohort had positive antinuclear antibodies, and thus therefore concerns a significant predictive factor.

The group with JIA-like uveitis contained 8 children, of whom again the majority were girls (63%). Uveitis first appeared on average at the age of 8.5 years of age and 88% of the patients had ocular complications (most commonly posterior synechiae in 63% of cases). Positivity of antinuclear antibodies was present in 88% of patients, which confirms the significance of this predictive factor. As we have already stated, JIA-like uveitis is a condition in which arthritis does not manifest itself due to treatment using systemic therapy. In our cohort 7 out of 8 patients were receiving systemic therapy (predominantly a combination of corticoids with methotrexate), only one patient was without general therapy (an 11-year-old girl with HLA B51 positive antigen monitored at our clinic for 18 months).

Methotrexate, which ranks among disease modifying pharmaceuticals, is the drug of first choice and prevents the onset of complications by reducing the necessity for local or general administration of corticosteroids. In recent years the use of TNF- α monoclonal antibodies (especially adalimumab and infliximab) has been consistently increasing in the treatment of JIA-like uveitis. The results of the multicentric study SYCAMORE demonstrated greater effectiveness of a combination of methotrexate with adalimumab in comparison with methotrexate alone (lower percentage of failure of treatment). Another pharmaceutical under examination is tocilizumab (inhibitor IL-6). Accord-

ing to the results of another multicentric study on 25 patients its use led to a regression of macular edema, as well as a pronounced reduction of the use of prednisone [10]. Further options for patients who do not respond to treatment with anti TNF- α preparations are Janus kinase (JAK) inhibitors, primarily baricitinib (JAK1 and JAK2 inhibitor). At present the European study JUVE-BRIGHT is under way, focusing on its effect and safety profile in children with JIA and JIA-like uveitis who do not respond to treatment with corticosteroids, methotrexate and biological agents. [9,10]

In our cohort we evaluated best corrected visual acuity in a total of 41 eyes (in one eye vision upon entry was light sensitivity and the final result fingers/20 cm, the patient underwent complicated cataract surgery during the observation period). In 14 patients it was not possible to evaluate BCVA adequately due to their low age or analgesation. The mean value of BCVA in the children in our cohort was 0.8 upon entry, and 1 at the end of the observation period. The difference between mean BCVA upon entry and at the end of the observation period was statistically significant ($p = 0.00035$). Among other factors, this indicates the necessity of timely diagnosis of uveitis and commencement of commensurate therapy, which in most cases leads to preventing the development of later complications limiting resulting visual acuity.

CONCLUSION

The incidence of ocular complications can be expected more frequently in young girls with JIA-like uveitis and positivity of ANA antibodies. These traits, in combination with female sex, constitute significant predictive factors of the potential development of uveitis with all its negative consequences.

The method of first choice of general therapy continues to be methotrexate either in monotherapy or in combination with corticosteroids. Biological treatment is reserved for cases resistant to the standard medical protocols. It is necessary to ensure close cooperation between an ophthalmologist and a pediatric rheumatologist.

REFERENCES

1. Lebl J. *Klinická pediatrie*, 2. Praha (Česká republika): Galén; 2014. *Revmatologie*; p. 261-266.
2. Dave M, Rankin J, Pearce M, Foster HE. Global prevalence estimates of three chronic musculoskeletal conditions: club foot, juvenile idiopathic arthritis and juvenile systemic lupus erythematosus. *Pediatr Rheumatol* 2020;18:1-7. doi: 10.1186/s12969-020-00443-8
3. Prakken B, Salvatore A, Martini A. Juvenile idiopathic arthritis. *Lancet* 2011;377(9783):2138-2149.
4. Zygmont A, Lipińska J, Biernacka-Zielińska M, Lipiec E, Niwald A, Smolewska E. Comparison of uveitis in the course of juvenile idiopathic arthritis with isolated uveitis in children - own experiences. *Reumatologia*. 2018;56(3):149-154. doi: 10.5114/reum.2018.76902
5. Malcová H, Dallos T, Bouchalová K, et al. Recommendations for the management of uveitis associated with juvenile idiopathic arthritis: the Czech and Slovak adaptation of the SHARE initiative. *Cesk Slov Oftalmol*. 2020;76(4):182-196. doi: 10.31348/2020/7
6. EL-Shereef RR, Lofty G, Mohamed AS, Hamdy L. Ocular manifestations of juvenile idiopathic arthritis and its relation to disease activity. *J Arthritis*. 2014;3(3):1-6. doi: 10.4172/2167-7921.1000137
7. Heiligenhaus A, Minden K, Föll D, Pleyer U. Uveitis in juvenile idiopathic arthritis. *Dtsch Arztebl Int*. 2015;112(6):92-100. doi: 10.3238/arztebl.2015.0092
8. Vitale AT, Graham E, de Boer JH. Juvenile idiopathic arthritis-associated uveitis: clinical features and complications, risk factors for severe course, and visual outcome. *Ocul Immunol Inflamm*. 2013;21(6):478-485. doi: 10.3109/09273948.2013.815785
9. Iannone C, Marelli L, Costi S, et al. Tocilizumab in juvenile idiopathic arthritis-associated uveitis: a narrative review. *Children* 2023;10(3):434. doi: 10.3390/children10030434
10. Calvo-Rio V, Santos-Gómez M, Calvi I, et al. Anti-interleukin-6 receptor tocilizumab for severe juvenile idiopathic arthritis-associated uveitis refractory to anti-tumor necrosis factor therapy: a multicenter study of twenty-five patients. *Arthritis Rheumatol*. 2017;69(3):668-675.