

New Features in Screening of Retinopathy of Prematurity. Our Experience with New Recommendations for Retinopathy of Prematurity Screening

Tomčíková Dana, Prepiaková Zuzana, Bušányová Beata, Kostolná Barbora

Department of Pediatric Ophthalmology, Faculty of Medicine of Comenius University and the National Institute of Children's Diseases, Bratislava, Slovakia



Doc. MUDr. Dana Tomčíková, PhD, MHA

Submitted to the editorial board: January 27, 2025

Accepted for publication: April 5, 2025

Available on-line: May 30, 2025

The authors of the study declare that no conflict of interests exists in the compilation, theme and subsequent publication of this professional communication, and that it is not supported by any pharmaceuticals company. The authors further declare that the study has not been submitted to any other journal or published elsewhere.

Correspondence address:

Klinika detskej oftalmológie NÚDCH- LFUK
Bratislava
Limbová 1
833 40 Bratislava
Slovakia
E-mail: Dana.Tomcikova@nudch.eu
dtomcikova@gmail.com

SUMMARY

Retinopathy of prematurity (ROP) is always a serious and sight-threatening condition, and its treatable stages require early detection and adequate treatment. It is necessary to focus on the principles of screening of ROP and recurrences thereof, which occur more often with the onset of intravitreal treatment using anti-vascular endothelial growth factor (anti-VEGF) agents. In this study, we evaluate the recurrence of ROP after primary treatment with intravitreally administered bevacizumab or ranibizumab, its frequency and timing of occurrence. Also discussed are the rules for screening of ROP, its recurrence and the need for long-term follow-up monitoring of children with any form of ROP.

Key words: ROP screening, recurrence of ROP, ROP recurrence screening, intravitreal treatment of ROP, follow-up monitoring of premature infants with ROP

Čes. a slov. Oftal., 81, 2025, No. 6, p. 301–305

INTRODUCTION

The late stages of retinopathy of preterm born infants represent a serious threat to loss of sight in one or both eyes. As a result it is extremely important to detect the disease sufficiently in time and to administer the patient the correct treatment. This provides motivation for the continual improvement and adjustment of the screening criteria for primary screening of ROP for the purpose of timely detection of the disease, while minimizing the patient stress by excessively frequent examination. It is also essential to ensure timely detection and attendant treatment of any recurrences of ROP. More frequent incidence of recurrences is directly linked to the development of anti-VEGF therapy in children with ROP.

MATERIAL AND METHOD

Our retrospective study included patients with ROP treated at the Department of Pediatric Ophthalmology at the Faculty of Medicine of Comenius University and the National Institute of Children's Diseases in Bratislava in the period of 2019–2023, who received intravitreal application of an-

ti-VEGF therapy as the primary treatment. The cohort consisted of 250 eyes of 125 patients. Primary intravitreal treatment with bevacizumab was applied in 164 eyes, and we used intravitreal administration of ranibizumab in 86 eyes. We focused on adequate detection of recurrences following intravitreal application. Figure 1. In the case of need to treat recurrences we used either repeated application of the same anti-growth agent, or diode laser coagulation (DLC). In the application of repeated intravitreal treatment we used the same drug due to the valid legislation in the Slovak Republic. We assessed the need for repeated treatment and post-conception age at the time of requirement for treatment of recurrence as fundamental factors. The study contains an updated overview of the literature, with recommendations for primary and secondary screening of ROP.

RESULTS

We especially assessed patients treated with bevacizumab and ranibizumab. In primary treatment with bevacizumab, supplementary treatment was administered in 32% of eyes (164 eyes, years 2019–2022), on average in the 41st post-conception week (PCW).

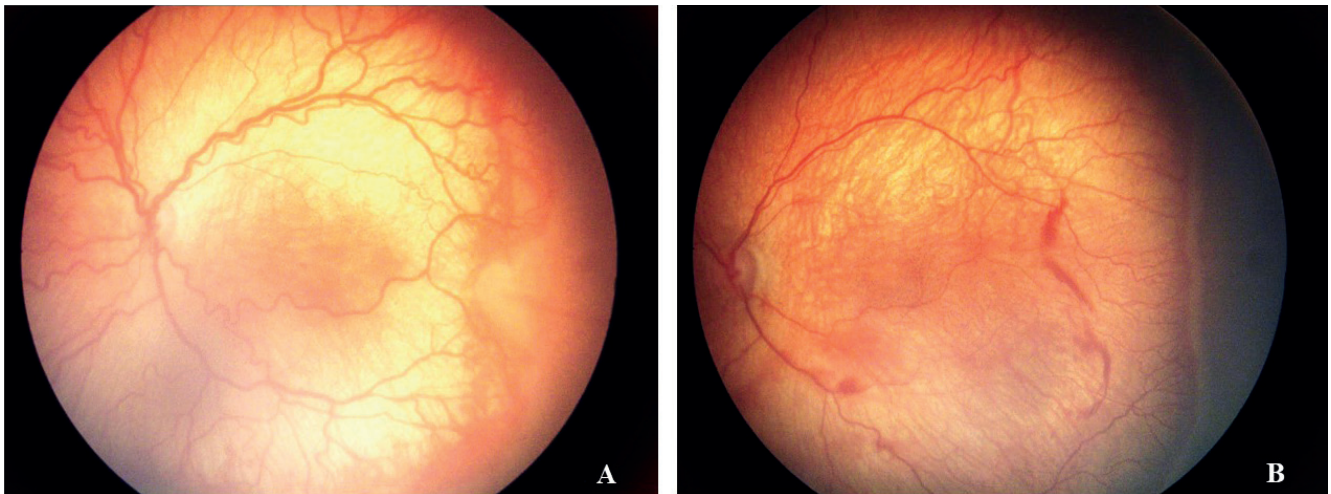


Figure 1. Aggressive ROP: (A) before intravitreal anti VEGF treatment, (B) reactivation of the disease 6 weeks

We used ranibizumab in treatment from 2022 onwards. Supplementary treatment was required in 46% of eyes. In our patients it was indicated on average at 43.3 PCW, most often between the 40th and 50th week. At the latest we observed recurrence in the 56th PCW (individual late cases were at 52, 53, 54, 56 and 58 PCW).

Recurrences occurred more frequently in children in poor clinical condition, on oxygen therapy, with small weight gains or after repeated surgeries. For comparison, supplementary treatment after paint (confluence) DLC in the years 2008–2009 was 6.7%. A total of 120 eyes were assessed. The results are summararily presented in Table 1.

DISCUSSION

According to the recommendations of the American Academy of Pediatrics 2013 [1] and the last review in 2019 [2], primary screening for ROP is recommended according to the following criteria:

- low birth weight – under 1500 g;
- gestation age (30 weeks or less).

Birth weight between 1500 and 2000 g and gestation age above 30 weeks in the presence of risk factors in connection with fluctuation of blood pO₂ level. According to the G-ROP study [3], new criteria have been estimated. They leave the threshold birth weight at 1500 g and less. The gestation week (GW) is stated at 28th GW. These criteria have 6 items. In addition to weight and gestation week

they incorporate 3 postnatal measurements with low weight gain of the infant or presence of hydrocephalus. According to the study, these criteria were 100% sensitive and reduced the number of examinations by 32.5%. They are not yet included in the guidelines of the American Academy of Ophthalmology (AAO). Examination of the ocular fundus is performed according to the indication of a neonatologist, whose presence is also appropriate at the examination of the high risk infants with respect to potential general complications during the examination (respiratory failure, bradycardia). It is necessary to keep in mind that the incidence of ROP closely correlates with pre and postnatal care of preterm born infants. As a result these criteria may or rather must be adjusted according to the experiences of the individual countries. In the Slovak Republic the limit gestation week has been moved to 32th week, while the threshold birth weight remains 1501 g and less. The examination should be performed by a highly trained ophthalmologist with sufficient experience and knowledge of identifying the localization and stage of ROP according to the international classification of ROP (International Committee for the Classification of Retinopathy of Prematurity) [2–6]. The examination is performed in maximal mydriasis, topical anesthesia, with indirect ophthalmoscope with the use of a lid speculum and scleral indenter. The immobilization of the infant is necessary during the examination. Upon the administration of eye drops, in particular Phenylephrine drops, it is necessary to press upon the lacrimal punctum

Table 1. Recurrence of ROP in % and average pkw. in individual treatment modalities

Type of primary treatment	Number of eyes	Years	Percent of recurrence	Average pkw* in time of recurrence
Bevacizumab	164	2019–2022	32%	41 pkw*
Ranibizumab	86	2022–2023	46%	43.3 pkw*
Paint DLC**	120	2008–2009	6.7%	unrated

* pkw – postconceptional week,

** Paint (confluent) DLC – diodlasercoagulation

Table 2. Timing of first ophtalmological examination – according to recommendations of American Academy of Pediatrics 2019 [6], and recommendations valid in Great Britain in 2022 [12]

Gestational age (weeks)	Postconceptional age (weeks)	Chronological-postnatal age (weeks)
22	31	9 (earlier examination according to patients' condition)
23	31	8 (earlier examination according to patients' condition)
24	31	7
25	31	6
26	31	5
27	31	4
28	32	4
29	33	4
30	34	4
>30 if risk factors present	34	4
31 (gw < 1500 g)	35	4
32 (gw < 1500 g)	36	4
33 (gw < 1500 g)	36	3
34 (gw < 1500 g)	36	2
35 (gw < 1500 g)	36	1

Table 3. Intervals of control examination according to recommendation of American Academy of Pediatrics 2019 [2]

Odporúčaný interval kontrolných vyšetrení (týždne)	Štádium ROP*
1 week and less	Zone I: Immature vascularization, ROP* Stage 1 or 2. Posterior zone II: Immature vascularization without ROP, Suspect A-ROP**
1-2 weeks	Zone I: Irregular regression of ROP* Posterior zone II: Immature vascularization without ROP* Zone II: ROP* Stage 2.
2 weeks	Zone II: Immature vascularization without ROP* ROP* 1 Stage Irregular regression of ROP*
2-3 weeks	Zone II: ROP* in regression Zone III: 1 or 2. Stage of ROP*

* ROP – Retinopathy of Prematurity,

**A-ROP – Aggressive ROP

in order to reduce systemic absorption of the medicaments and their adverse effects (tachycardia, systemic hypertension, paralytic ileus). To minimize discomfort and pain we use a local anesthetic and it is possible to administer 1 ml of 25% glucose orally 2 minutes before the ophthalmological examination [7]. The stage of ROP indicated for treatment most often develops in the period between the 34th and 37th post-conception week, while in very premature infants retinopathy develops later, on average between the 10th and 12th post-natal week. For this reason we indicate the first examination with respect to the gestation week at birth (Table 2).

The appointments for subsequent examinations are recommended by the examining ophthalmologist based on the condition of vascularization and the finding on the retina according to the international classification and the overall clinical condition of the infant. According to the AAO the following intervals are recommended (Table 3):

Treatment upon diagnosis of type 1 ROP must be perfor-

med within 48–72 hours. In the presence of plus (pre-plus) form of the disease in zone I or II depending on the finding, it is necessary to consider early indication for treatment rather than further monitoring. In the case of an ambiguous finding, in the presence of pre-plus form, for risk children with an unstable clinical condition and a less experienced examiner it is suitable to indicate an earlier examination. When deciding upon further monitoring or referral for treatment it is also necessary to consider the time necessary for transport of the infant to a specialized center. It is necessary to pay attention to the continuation of ophthalmological monitoring upon transfer of the child to another department and upon discharge home. The appointment of the following examination must be stated in writing and the parent must be instructed with regard to the risk of loss of sight in the case of failure to attend the appointment for the follow-up examination.

Termination of screening examinations for acute retinopathy of preterm born children is possible depending on

the age and the finding on the retina as follows:

- The retina is fully vascularized.
- Vascularization reaches into zone III without preceding ROP in zone I or II (may require confirming examination at age of < 35th PCW).
- At age of 45th PCW without preceding type 1 ROP (previously 50th PCW).
- ROP has completely regressed and there is no presence of any abnormal vascular tissue that could lead to reactivation of ROP
- Following previous anti-VEGF treatment monitor minimally up to 65th PCW, especially between 45th and 55th PCW[2].

Based on our results we recorded recurrence of ROP following anti-VEGF monotherapy on average at 41th PCW (bevacizumab) and 43.3th PCW (ranibizumab). This was most frequently between the 40th and 50th week, which corresponds with the most commonly stated data in the literature. Reactivation was recorded at maximum 8 weeks after primary treatment [8]. Recurrences occurred more frequently in children in poor clinical condition, on oxygen therapy, after repeated surgeries or with small weight gains. With reference to the frequency of recurrences, in our cohort they occurred in 32% (bevacizumab), and 46% (ranibizumab) respectively. According to the FIRE-FLEYE study, supplementary treatment upon primary treatment with ranibizumab was required in 22.6% of cases [9]. In some studies patients treated with ranibizumab had a higher percentage of repeated treatment (58%) in comparison with patients treated with bevacizumab (37%), especially with higher doses (0.3–1.25 mg) [8,10].

With respect to the possibility of recurrences upon monotherapy with intravitreally applied anti-VEGF agents (in Slovakia Lucentis and Eylea are currently approved), regular monitoring every 1–2 weeks is indicated until the retina is fully vascularized. The exact criteria for termination of secondary screening are stated above.

Avascular retinal periphery occurs in as many as 81% of cases following any ROP, in 22% of cases there is presence of fibrovascular tissue in the periphery following stage 1 ROP and as high as 100% following stage 3 ROP [11]. In children after any form of ROP there is a higher incidence of hemorrhages, retinal detachment, myopia, anisometropia,

amblyopia, strabismus and atrophy of the optic nerve head. With respect to the higher probability of development of later ocular complications of prematurity in children who were included for screening of ROP, children remain under monitoring by an ophthalmologist and it is necessary to inform parents about it. Subsequent ophthalmological monitoring of preterm born infants is recommended for:

Children without ROP and following spontaneous regression of ROP:

- 1st follow-up examination at approx. 1 year of corrected age;
- 2nd follow-up examination between 24 and 30 months;
- 3rd examination before beginning of school attendance.
- More frequent follow-up examinations are indicated depending on the objective finding.

Children with ROP regression after treatment:

- every 3 months over the course of 1 year;
- every 6 months until 6 years of age or according to the objective finding;
- long-term monitoring 1x per year, need to instruct parents of the risk of retinal detachment and self-monitoring at home.

CONCLUSION

In our study recurrence of ROP after primary treatment with bevacizumab occurred on average at 41th PCW in 32% of patients. After ranibizumab this occurred in 46.6% of patients, on average at 43.3th PCW. The percentage of recurrences was lowest after laser treatment. Only 6.7% of eyes required supplementary treatment due to the insufficient effect of primary treatment. With regard to the possibility of recurrences upon monotherapy with intravitreally applied anti-VEGF agents, regular monitoring of the patient is recommended every 1–2 weeks until full retinal vascularization, at minimum until 65th PCW. The current international screening criteria for primary screening and screening of recurrences have not yet been significantly modified. In our study we did not record any case of failure of primary screening or screening of recurrences. Thereof no need for their adjustment was demonstrated.

REFERENCES

1. Fierson WM, et al. Screening Examination of Premature Infants for Retinopathy of Prematurity. *Pediatrics* 2013;131(1):189-195.
2. Fierson WM, American Academy of Pediatrics Section on Ophthalmology, American Academy of Ophthalmology, American Association for Pediatric Ophthalmology and Strabismus, American Association of Certified Orthoptists. Screening Examination of Premature Infants for Retinopathy of Prematurity. *Pediatrics*. 2018;142(6):e20183061.
3. Binenbaum G, Tomlinson LA, de Alba Campomanes AG, et al. Validation of the Postnatal Growth and Retinopathy of Prematurity Screening Criteria. *JAMA Ophthalmol*. 2020;138(1):31-37.
4. Early Treatment for Retinopathy of Prematurity Cooperative Group. Revised indications for the treatment of retinopathy of prematurity: results of the early treatment for retinopathy of prematurity randomized trial. *Arch Ophthalmol*, 2003;121(12):1684-1694.
5. International Committee for the Classification of Retinopathy of Prematurity. The International Classification of Retinopathy of Prematurity revisited. *Arch Ophthalmol*. 2005; 123(7):991-999.
6. The Committee for the Classification of Retinopathy of Prematurity. An international classification of retinopathy of prematurity. *Arch Ophthalmol*. 1984;102:1130-1134.
7. Costa MCD, Eckert GU, Fortes BGB, et al. Oral glucose for pain relief during examination for retinopathy of prematurity: a masked randomized clinical trial. *Clinics*. 2013;68(2):199-204.
8. Lyu J, Zhang Q, Chen CL, et al. Recurrence of Retinopathy of Prematurity After Intravitreal Ranibizumab Monotherapy: Timing and Risk Factors. *Invest Ophthalmol Vis Sci*. 2017;58(3):1719-1725.
9. Stahl A, Sukgen EA, Wu WC, Lepore D, Nakanishi H, Mazela J, et al., FIREFLEYE Study Group. Effect of Intravitreal Aflibercept vs Laser Photocoagulation on Treatment Success of Retinopathy

- of Prematurity. The FIREFLEYE Randomized Clinical Trial. *JAMA*. 2022;328(4):348-359.
10. Patel N, Acaba-Berrocal L, Hoyek S, et al. Comparison in retreatments between bevacizumab and ranibizumab intravitreal injections for retinopathy of prematurity. A multicenter study. *Ophthalmology*. 2023;130(4):373-378.
 11. Ness P, Andaluz-Scher L, Leverant R, et al. Characteristics of spontaneously regressed retinopathy of prematurity at termination of acute retinal screening examinations using a novel grading system, *J Pediatr Ophthalmol Strabismus*. 2023;60(5):359-364.
 12. Wilkinson AR, Adams GGW, Fleck BW, Nieto-Hernandez R. Guideline Development Groups (GDG) of the Royal College of Paediatrics and Child Health (RCPCH) and the Royal College of Ophthalmologists (RCOphth). UK screening and treatment of retinopathy of prematurity Updated 2022 Guidelines. *Early Hum Dev*. 2023;Mar;177-178. doi: 10.1016/j.earlhumdev.2023.105715