Comparison of Efficacy of Antiseptic DROPsept and Antibiotic Tobrex in Patients with Chronic Blepharitis

Hrůzová Eliška[1,2]

[1]Lexum Eye Clinic, Brno, Czech Republic
[2]Private Ophthalmology Practice, Hrušovany nad Jevišovkou, Czech Republic

Submitted to the editorial board: April 30, 2026
Accepted for publication: June 27, 2026
Available on-line: October 14, 2026
https://doi.org/10.31348/2026/37

The author of the study declares that no conflict of interests exists in the compilation, subject and subsequent publication of this professional communication. The Fidia Farmaceutici company provided samples of the preparation DROPsept for the purposes of this clinical evaluation. The study has not been submitted to any other journal or printed or presented elsewhere, with the exception of congress abstracts and recommended procedures.

MUDr. Eliška Hrůzová

Correspondence address:
Klinika Lexum
Holandská 872/9
639 00 Brno-Štýřice
Czech Republic
E-mail: hruzova@lexum.cz

SUMMARY

Aim: To compare the efficacy and safety of DROPsept antiseptic eye drops (chlorhexidine digluconate 0.02% + Vitamin E TPGS 0.2%) with Tobrex antibiotic eye drops (tobramycin 0.3%) in patients with chronic blepharitis.

Material and Methods: Forty patients with chronic blepharitis were included in this prospective clinical evaluation (Tobrex group n = 20, DROPsept group n = 20), treated 4 times daily for 1 week, followed by application of preservative-free artificial tears. All patients received instructions on eyelid hygiene, warm compresses and Meibomian gland massage. Assessment was performed at T0 (baseline), T1 (1 week) and T2 (1 month). The evaluated parameters included BSS score (Blepharitis Severity Score) (0–12), microbiological swabs and a subjective questionnaire.

Results: Baseline BSS scores were comparable (Tobrex 5.55 ±1.83; DROPsept 5.80 ±1.57). After 1 week, the BSS score was significantly lower in the DROPsept group (2.86 ±1.49 vs. 4.20 ±2.09; p = 0.033). At T2, the favorable trend persisted in the DROPsept group (2.22 ±1.93 vs. 2.67 ±2.33; p = 0.689). In patients with an initially positive microbiological culture result, after a week of treatment the result was negative in 73% of patients receiving DROPsept therapy and in 57% of patients receiving Tobrex therapy. Patient satisfaction was significantly higher in the DROPsept group (9.2 ±1.4 vs. 6.6 ±2.8; p = 0.013).

Conclusion: DROPsept demonstrated a faster reduction of the BSS score after 1 week (p = 0.033) and significantly higher patient satisfaction (p = 0.013). The numerically higher eradication rate (73% vs. 57%) did not reach the level of statistical significance (p = 0.627). DROPsept offers the advantage of no risk of antibiotic resistance and a favorable safety profile. These findings are exploratory; confirmation in a larger randomized controlled trial with placebo control is required.

Key words: blepharitis, antiseptic, chlorhexidine, DROPsept, tobramycin, antibiotic resistance, cataract surgery, Meibomian glands

Čes. a slov. Oftal., 82, 2026, No. x, p.

INTRODUCTION

Blepharitis is a chronic inflammation of the edges of the eyelids, which ranks among the most common pathologies of the ocular adnexa in clinical practice. According to the anatomical localization, we divide it into anterior (blepharitis anterior) and posterior form – meibomitis (blepharitis posterior), in which the most commonly occurring type is mixed form [1]. Anterior blepharitis affects the skin, eyelashes and follicles, posterior blepharitis is conditioned by Meibomian gland dysfunction (MGD), which leads to a change in the composition and quality of the lipid layer of the lacrimal film, and the development of dry eye syndrome [1]. A chronic course of the disease with a tendency towards recurrences has a pronounced negative effect on the quality of life of patients, and places a long-term burden in terms of outpatient care.

The pathophysiology of blepharitis is multifactorial. A crucial role is played by bacterial colonization of the edge of the eyelids, with the formation of a biofilm that spreads along the eyelash follicles to the Meibomian glands; in the course of this process, bacterial lipases split the lipid content of the glands into irritant free fatty acids, and the released virulent factors sustain chronic inflammation [2]. The process is further supported by dysregulation of the immune response and vascular changes on the edge of the eyelid, especially in the case of rosacea. The most common cause of chronic blepharitis is Meibomian gland dysfunction with obstruction of the terminal ducts, change of the lipid layer of the lacrimal film and the development of evaporative dry eye syndrome [1].

The pathophysiology is closely linked to the condition of the ocular microbiome. A healthy ocular surface contains regular commensals (in particular Staphylococcus, Cory-

nebacterium, Cutibacterium), which maintain homeostasis. Its impairment (dysbiosis), with reduced diversity and overgrowth of pathogens, in particular Staphylococcus aureus, is associated with the development of blepharitis [3]. Repeated application of antibiotics intensifies dysbiosis and selects resistant strains, while antiseptic agents reduce the bacterial load without any fundamental change to the composition of the microbiome [3].

The foundation of treatment of blepharitis is regular eyelid hygiene, warming with warm compresses and Meibomian gland massage. In more severe forms, local or general antibiotic treatment is added (doxycycline, tetracycline creams). Complete curing of blepharitis is usually unsuccessful, nevertheless correct and regular eyelid hygiene is capable of pronouncedly alleviating its manifestations [1].

Within the context of cataract surgery, chronic blepharitis represents a potentially serious risk factor. Bacterial colonization of the edge of the eyelid and ocular surface increases the risk of postoperative endophthalmitis. Endophthalmitis is a rare but sight-threatening complication with an incidence of 0.023–0.026% [4]. Bacteria from the ocular surface may enter the anterior chamber through a surgical incision, and for this reason prophylactic preparation of the ocular surface is clinically of fundamental importance.

A serious and growing problem is antibiotic resistance of pathogens of the ocular surface. The American study ARMOR (Antibiotic Resistance Monitoring in Ocular Microorganisms), which monitors the presence of resistance to antibiotics in the case of regular pathogens of the ocular surface, describes the presence of methicillin resistance in 37% of isolates of Staphylococcus aureus and 49% of coagulase-negative staphylococci, in which methicillin resistant strains are multi-resistant in more than 70% of cases; resistances to azithromycin, ciprofloxacin and tobramycin are also common. Gram-negative Pseudomonas aeruginosa and Haemophilus influenzae remain predominantly sensitive [5]. Repeated prophylactic administration of antibiotics selects resistant strains [5], which leads to a search for alternatives that enable decontamination of the ocular surface without the risk of developing resistance.

Antiseptic agents represent a promising alternative thanks to their broad-spectrum antimicrobial effect, without the risk of developing antibiotic resistance. DROPsept (Fidia Farmaceutici) is an ocular preparation that combines chlorhexidine digluconate 0.02% with Vitamin E TPGS (D-alpha-tocopherol polyethylene glycol 1000 succinate) 0.2%. Chlorhexidine is a strong antiseptic agent with a bacteriostatic and bactericidal effect on gram-positive and gram-negative bacteria, its mechanism consisting in disrupting the integrity of the bacterial cell membrane, with subsequent precipitation of cytoplasmatic macromolecules and cell lysis [6,7]. A key innovation of the DROPsept preparation is combination with Vitamin E TPGS – an amphipathic molecule capable of forming stable micelles and increasing the biological accessibility of chlorhexidine in the corneal layers. Caruso et al. demonstrated as much as a 10 times greater concentration of chlorhexidine in corneal tissue upon the use of a formulation with TPGS in comparison with chlorhexidine alone, while maintaining a non-toxic profile both in vitro and in vivo [6]. In a comparative study, the preparation also demonstrated the broadest spectrum of antimicrobial, antiparasitic and antiviral activity in comparison with other ophthalmological preparations [7].

In a randomized controlled trial, Romano et al. (2024) demonstrated that three-day postoperative application of DROPsept 4× per day led to a significant reduction of bacterial colonization of the ocular surface ($p < 0.001$), in which the preparation was markedly better tolerated in comparison with povidone-iodine 0.6% (adverse side effects: 26% vs. 97% of patients) [8]. The taxonomic composition of the ocular microbiome remained unchanged upon the use of both antiseptic agents, in contrast with antibiotics [8].

The primary objective of our study was to conduct a prospective comparison of the efficacy and safety of DROPsept eye drops with Tobrex antibiotic eye drops (tobramycin 0.3%) in patients with chronic blepharitis within the conditions of regular clinical practice. A secondary objective was to evaluate whether patients are capable of adhering to a conservative, non-pharmacological therapeutic regime over the long term – eyelid hygiene, warming, Meibomian gland massage and artificial tears – and the effect of this care on the general symptoms of blepharitis after the end of active pharmacological therapy. The study also focused on optimizing the treatment of blepharitis with reference to growing antibiotic resistance and correct preoperative preparation of risk patients before cataract extraction.

MATERIAL AND METHODS

Cohort of patients and design of clinical evaluation

The prospective clinical evaluation included patients with clinically diagnosed chronic blepharitis, who were observed at the Lexum Brno eye clinic and in Private Ophthalmology Practice Hrušovany nad Jevišovkou from October 2025 to March 2026. All the patients signed an informed consent form to their inclusion in the study, as well as to the compilation of photo documentation. The clinical evaluation was conducted in accordance with the Declaration of Helsinki. The inclusion criterion was clinically confirmed chronic blepharitis. The exclusion criteria were known intolerance or hypersensitivity to the contents of the preparations used. The patients were divided into two groups based on an alternating scheme: even registration numbers were allocated to the group for treatment with Tobrex (Alcon) and odd registration numbers allocated to the group for treatment with DROPsept (Fidia Farmaceutici). A total of 40 patients were included (Tobrex n = 20; DROPsept n = 20). Representative examples of the clinical findings are documented in Figure 1A, 1B, 2A, 2B, 3 and 4. The Tobrex group comprised 20 patients (14 women, 6 men) with an average age of 58.5 years (range 22–82 years). The DROPsept group comprised 20 patients (12 women, 8 men) with an average age of 55.8 years (range 20–86 years). The patients were examined at two centers – Lexum Eye Clinic Brno (Tobrex n = 10, DROPsept n = 9) and Private Ophthalmology Practice Hrušovany

nad Jevišovkou (Tobrex n = 10, DROPsept n = 11). The baseline BSS (Blepharitis Severity Score) was comparable in both groups (Tobrex 5.55 ±1.83; DROPsept 5.80 ±1.57; p = 0.805), corresponding to medium-severe blepharitis. The basic characteristics of the cohort are summarized in Table 1.

Therapeutic protocol

The patients in the DROPsept group were treated with the preparation 4× daily according to the recommendations of the manufacturer (Fidia Farmaceutici), provided by means of a company representative, while the patients in the Tobrex group were treated with the preparation 4× daily according to the recommendations in the package information leaflet. For the purposes of this clinical evaluation, samples of the DROPsept preparation were provided by the Fidia Farmaceutici company. The length of active treatment with eye drops was 1 week. After the end of treatment, the patients applied preservative-free artificial tears. At the baseline examination, all patients were educated on eyelid hygiene – application of warm compresses, Meibomian gland massage, and cleaning of the edges of the eyelids.

Evaluated parameters and follow-up intervals

The evaluation was conducted at three points in time:

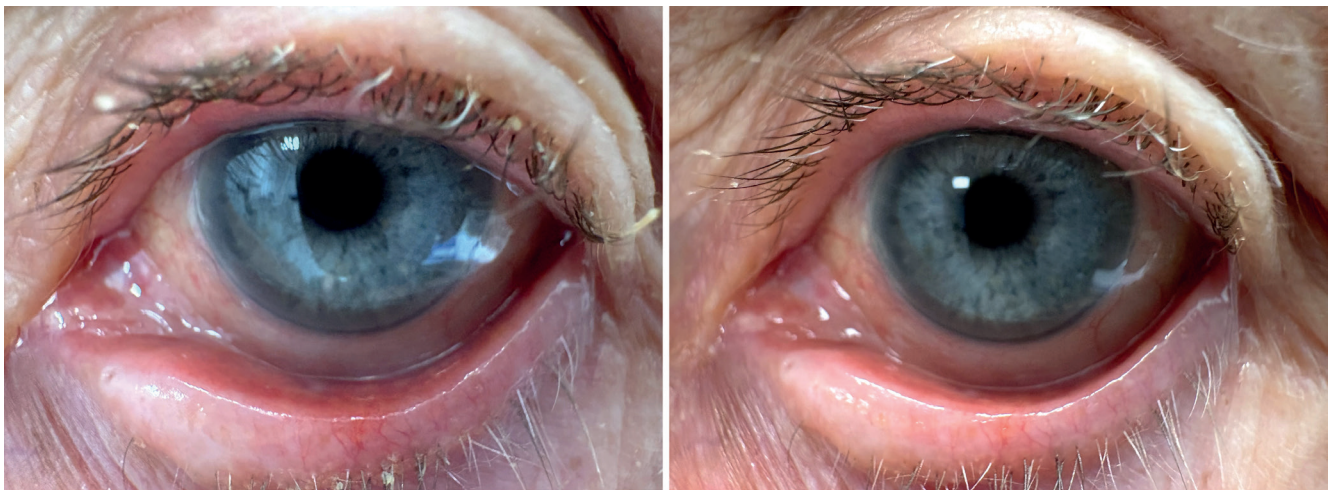

A B

Figure 1. Chronic mixed blepharitis (anterior and posterior form), right eye, DROPsept group. (**A**) Baseline status prior to treatment (T0). Note eyelid margin erythema, crusting of the eyelashes of both upper and lower eyelid, and inspissated Meibomian gland secretion. (**B**) Same patient, status after 1 week of treatment (T1). Marked improvement of eyelid margin erythema, resolution of eyelash crusting, and improvement of Meibomian gland expressibility

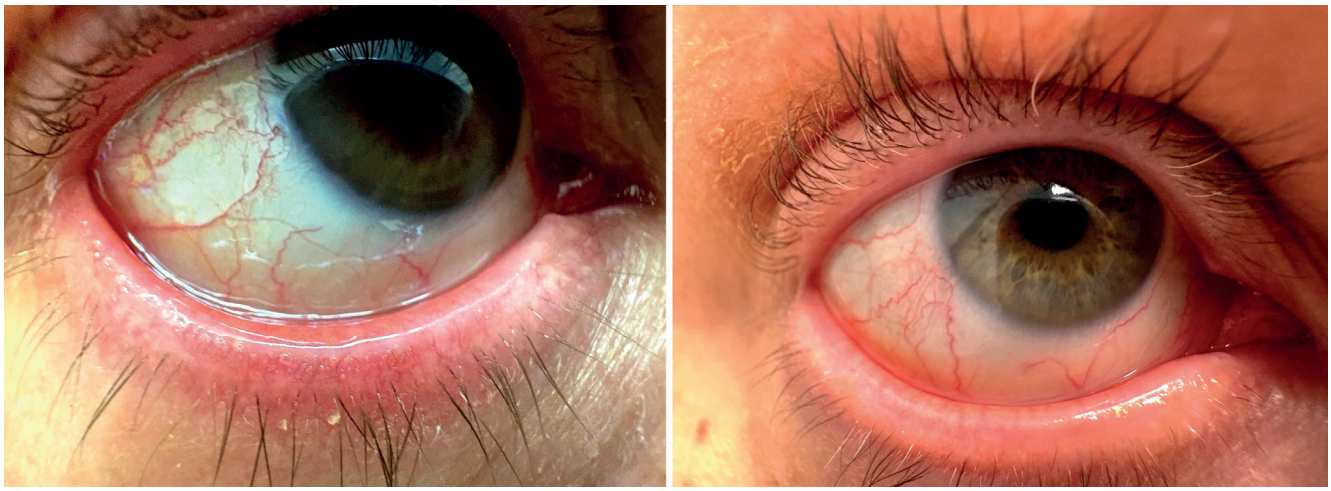

A B

Figure 2. Posterior blepharitis (meibomitis, Meibomian gland dysfunction), right eye, Tobrex group. (**A**) Baseline status at initial examination (T0). Note marked erythema of the lower eyelid margin, telangiectasia and hyperaemia of the bulbar conjunctiva, and inspissated Meibomian gland secretion with reduced expressibility. (B)Same patient, status after 1 month from treatment initiation (T2), following completion of the 1-week pharmacological treatment and regular eyelid hygiene, warm compresses and Meibomian gland massage. Marked improvement of Meibomian gland function, reduction of eyelid margin erythema and telangiectasia. The findings demonstrate the positive effect of non-pharmacological treatment on Meibomian gland function

Table 1. Baseline characteristics of the study population

Parameter	Tobrex (n = 20)	DROPsept (n = 20)
Sex (female/male)	14/6	12/8
Mean age in years (range)	58.5 (22–82)	55.8 (20–86)
Study site – Lexum Clinic Brno (n)	10	9
Study site – Eye Clinic Hrušovany nad Jevišovkou (n)	10	11
Baseline BSS score – mean ± SD	5.55 ±1.83	5.80 ±1.57
p-value for baseline BSS score (Mann-Whitney U test)	p = 0.805 (NS)	

BSS score – Blepharitis Severity Score

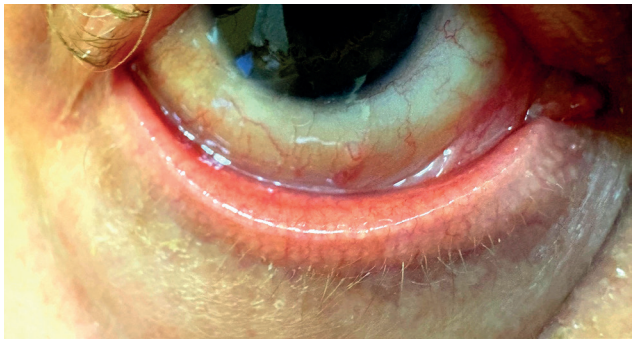

Figure 3. Obstruction of the Meibomian gland orifices of the lower eyelid – a typical finding in posterior blepharitis (meibomitis). Note the white inspissated secretion plugs in the Meibomian gland orifices along the eyelid margin, and eyelid margin erythema. Meibomian gland obstruction leads to disruption of the lipid layer of the tear film and development of dry eye syndrome

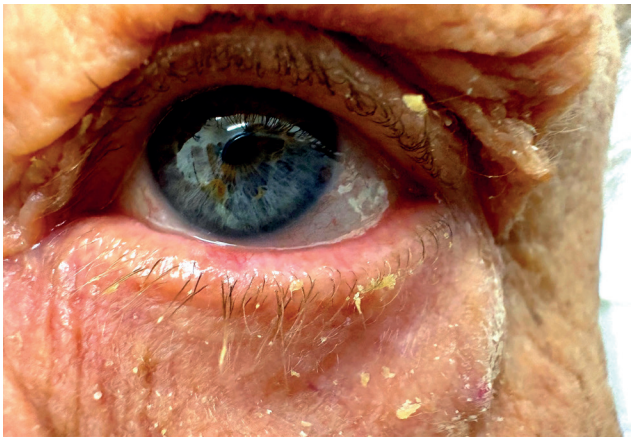

Figure 4. Seborrhoeic anterior blepharitis, left eye – typical clinical appearance. Note the prominent golden-yellow greasy scales and crusts on the eyelashes and eyelid margin skin, as a manifestation of concurrent seborrhoeic dermatitis. Eyelid margin erythema is present. The seborrhoeic form of anterior blepharitis is characterized by less intense inflammation compared to the staphylococcal form, but with greasy scaling and a tendency for chronic recurrence

T0 (baseline examination), T1 (follow-up after one week) and T2 (follow-up after one month). Microbiological swabs were taken at T0 (before commencement of therapy) and at T1 (after the end of weekly treatment with eye drops). At T2 only a clinical evaluation of the BSS was conducted, together with a subjective questionnaire.

The BSS score is a simple clinical scoring system based on the morphological finding on the edge of the eyelid, which enables objective evaluation of blepharitis and monitoring of the response to treatment over time. It evaluates four parameters: erythema of the edge of the eyelid (0 = none, 1 = mild, 2 = medium-severe, 3 = severe diffuse), crusts (0 = none, 1 = minimal, 2 = medium-severe, 3 = massive), secretion (0 = clear/none, 1 = scant/viscous, 2 = medium-severe/purulent, 3 = widespread/purulent) and Meibomian gland expression (0 = normal secretion, 1 = slightly thickened, 2 = thickened, 3 = complete obstruction/no secretion). The total score is the sum of the four components within the range of 0–12 points; according to this value we evaluate blepharitis as mild (0–3 points), medium-severe (4–7 points) or severe (8 or more points). With reference to the absence of a universally validated scoring system for blepharitis, the composite clinical BSS score was used, evaluating the four parameters consistent with the parameters used in the published literature.

Microbiological swabs were taken from the edge of the eyelid before the commencement of therapy (T0) and after the completion of one week of treatment (T1), processed by the standard cultivation method (inoculation for cultivation media, cultivation, identification of isolated microorganisms and determination of their sensitivity to antibiotics). The patients filled out a subjective questionnaire evaluating their symptoms (burning, itching, reddening, feeling of foreign body, lacrimation), and the degree of satisfaction with treatment at T0, T1, and T2.

Statistical analysis

A Mann-Whitney U test (nonparametric test for two independent cohorts) was used for comparison of the BSS score between the groups. A Wilcoxon signed-rank test (nonparametric test for paired data) was used for evaluation of the decrease of the BSS score over time. A Fisher's exact test was used for comparison of the degree of eradication in the swabs. The level of statistical significance was set at p = 0.05. The statistical analysis was performed in Python software (module scipy.stats).

RESULTS

Characteristics of cohort and compliance

20/20 patients in the Tobrex group and 19/20 in the DROPsept group underwent a follow-up examination at

T1 (1 patient did not attend: 1× COVID-19). The BSS score was recorded for 20 patients in the Tobrex group and for 18 patients in the DROPsept group (the BSS score was not recorded at the follow-up for one patient in the DROPsept group). 15/20 patients in the Tobrex group and 17/20 patients in the DROPsept group underwent a follow-up examination at T2; the BSS score was recorded for 15 patients in the Tobrex group and for 16 patients in the DROPsept group (the BSS score was not recorded at the follow-up for one patient in the DROPsept group). The total number of patients who did not attend the follow-up examination at T2 was eight (five in the Tobrex group, three in the DROPsept group). The reasons for premature termination of the observation included unconnected health complications (n = 2) and discontinuation of participation in the study without stating a reason (n = 6). As a consequence, the statistical analysis evaluating the BSS score is based on a reduced number of patients at the time of the T2 follow-up examination (Tobrex n = 15; DROPsept n = 16).

Development of BSS score

After one week of active treatment (T1), the mean BSS score in the DROPsept group was 2.86 ±1.49 (n = 18), as compared with 4.20 ±2.09 (n = 20) in the Tobrex group. The difference between the groups was statistically significant (Mann-Whitney U test, p = 0.033). At T2 (one month after commencement of treatment), the BSS score continued to decrease in both groups: Tobrex 2.67 ±2.33 (n = 15); DROPsept 2.22 ±1.93 (n = 16); the difference between the groups was not statistically significant (p = 0.689). The decrease of the BSS score in comparison with the baseline values was statistically significant in both groups both at T1 (Tobrex p = 0.002; DROPsept p < 0.001), and at T2 (Tobrex p = 0.003; DROPsept p = 0.003) (Wilcoxon signed-rank test). The development of the BSS score over time is illustrated in Graph 1. The representative clinical documentation of the finding before and after treatment is presented in Figure 1A/1B (DROPsept group) and 2A/2B (Tobrex group).

Results of microbiological swabs

Microbiological swabs were taken at two points in time: before the commencement of therapy (T0) and after the end of one week of treatment with drops (T1). The clinical finding of anterior blepharitis before and after treatment is documented in Figure 1A and 1B, posterior blepharitis with obstruction of the Meibomian glands in Figure 2A, 2B, and 3, seborrheic form of anterior blepharitis in Figure 4. A positive finding on the baseline swab (T0) was recorded in 7 out of 20 patients (35%) in the Tobrex group and in 11 out of 20 patients (55%) in the DROPsept group. The most frequently isolated microorganisms were coagulase of negative staphylococcus (Staphylococcus epidermidis, Staphylococcus hominis, Staphylococcus species), as well as Staphylococcus aureus, viridans group streptococci and Escherichia coli. A control swab after one week of treatment (T1) was taken for 18 patients in each group. The efficacy of treatment was evaluated in patients with a positive result of baseline cultivation. In patients with an originally positive result of bacterial cultivation, a negative result was recorded in 57% (four out of seven patients) after one week of treatment with To-

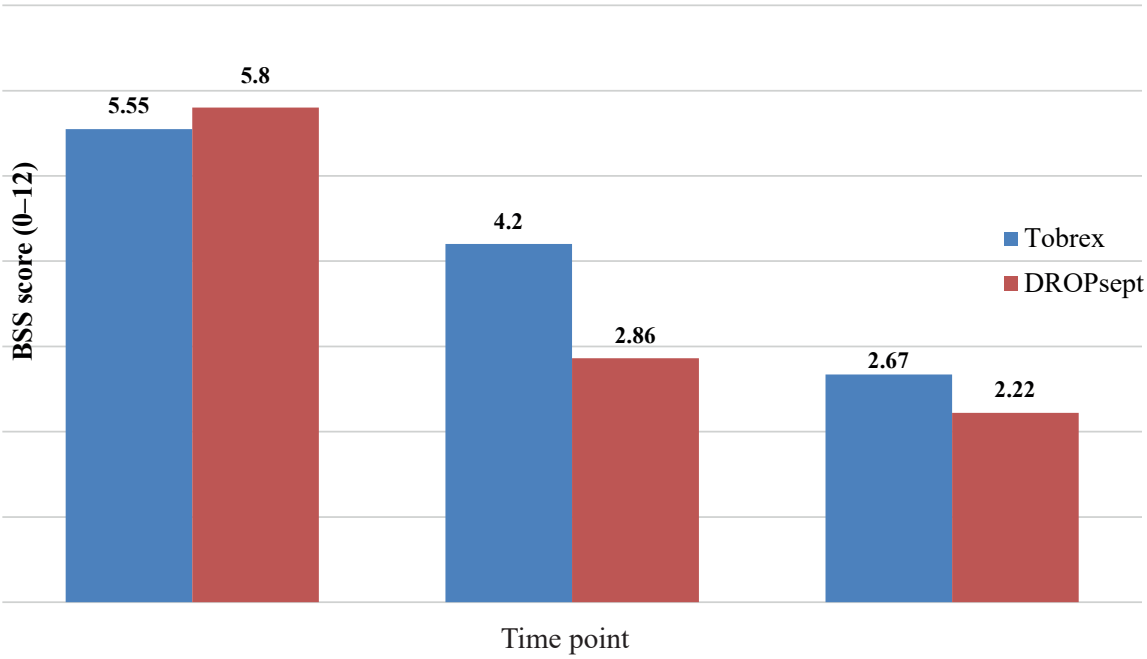

Graph 1. Mean BSS score (± SD) in both groups during follow-up

*SD – standard deviation; BSS score (Blepharitis Severity Score): 0–3 mild blepharitis, 4–7 moderate, 8–12 severe blepharitis; blue columns = Tobrex group, red columns = DROPsept group; * p < 0.05 (statistically significant difference between groups, Mann-Whitney U test)*

Table 2. Results of microbiological swabs

Parameter	Tobrex (n = 20)	DROPsept (n = 20)
Baseline swab T0 – positive	7/20 (35 %)	11/20 (55 %)
Eradication after treatment (follow-up swab T1)	4/7 (57 %)	8/11 (73 %)
Persistent positive swab at T1	3/7 (43 %)	3/11 (27 %)
Most frequently isolated MO – baseline swab T0	Staphylococcus species (3×) S. aureus (2×) S. epidermidis (1×) Streptococcus viridans (1×)	S. epidermidis (4×) Staphylococcus species (4×) S. aureus (1×) S. hominis (1×) E. coli (1×)
Most frequently isolated MO – follow-up swab T1 (persistent)	Staphylococcus species (3×)	Staphylococcus species (3×)

MO – microorganism; eradication assessed only in patients with positive baseline swab; Staphylococcus species = strain not further classified by culture

brex, while the control swab was positive for three patients (43%). In the DROPsept group a negative result was recorded in 73% (eight out of eleven patients with an originally positive cultivation) for the control swab, while the control swab remained positive for three patients (27%). The difference in the degree of eradication of bacterial colonization was not statistically significant between the groups (Fisher's exact test, p = 0.627), which is probably due to the small number of patients with a positive baseline swab. DROPsept reached a numerically higher level of eradication of bacteria (73% vs. 57%, see Table 2). Graph 1 describes the development of the mean BSS score (± SD) in both groups during the course of the observation.

Subjective questionnaire and tolerance

The subjective questionnaire was evaluated at T1 for 17 patients in the DROPsept and 15 patients in the Tobrex group; at T2 for 17 patients in the DROPsept group and 15 patients in the Tobrex group. The questionnaire evaluated the intensity of complaints (scale of 0–10), the impact of the complaints on everyday activities (scale of 0–4), overall condition of eyes at T1 (scale of 0–10, in which 10 = very good) and at T2 (scale of 0–10, in which 10 = very good), subjective alleviation of complaints (–3 to +3), and satisfaction with treatment (0–10).

The average intensity of the complaints was comparable in both groups (DROPsept 4.4 ±2.9; Tobrex 5.2 ±1.8; p = 0.543). The overall condition of eyes after one week of treatment (T1) was evaluated more favorably by patients in the DROPsept group (7.0 ±2.0 vs. 5.4 ±0.5; p = 0.096), who stated a more pronounced subjective improvement (average change +2.1 ±0.9 vs. +1.4 ±1.7; p = 0.440), though the differences did not reach the level of statistical significance. After one month of observation (T2), the patients in the DROPsept group evaluated the condition of their eyes at an average of 8.2 ±1.3, and in the Tobrex group 6.4 ±2.7 (p = 0.101). A statistically significant difference was recorded in the evaluation of satisfaction with therapy: the patients in the DROPsept group were markedly more satisfied than in the Tobrex group (9.2 ±1.4 vs. 6.6 ±2.8; p = 0.013).

As regards tolerance, two patients in the Tobrex group stated adverse effects immediately after application of the eye drops (burning, temporary deterioration of vision); in one patient from this group allergy contributed to the discomfort. One adverse effect was recorded in the DROPsept group (temporary pressure upon application of warming mask). No patient in either group stated any serious adverse reaction requiring suspension of treatment or medical intervention. In the verbal evaluation, patients from the DROPsept group most frequently stated rapid relief from complaints and general satisfaction with treatment.

DISCUSSION

The results of the study show that DROPsept achieved a more rapid improvement of the clinical blepharitis severity score (BSS) at T1 in comparison with Tobrex. After one week of active treatment, the average BSS score in the DROPsept group was 1.34 points lower than in the Tobrex group; the difference was statistically significant (p = 0.033). At T2 (1 month), the DROPsept remained slightly more favorable (2.22 vs. 2.67; p = 0.689), though the difference did not reach the level of statistical significance, probably as a consequence of the reduced number of included patients at T2.

Subjective patient evaluation was consistent with the objective clinical results. Patients in the DROPsept group evaluated the condition of their eyes after T1 and T2 more favorably, and stated a more pronounced subjective improvement, although the differences did not reach the level of statistical significance. Satisfaction with the drops was statistically significantly higher in the DROPsept group (9.2 ±1.4 vs. 6.6 ±2.8; p = 0.013). This result is clinically relevant, since a higher rate of compliance and satisfaction with treatment are key factors in the success of long-term treatment of chronic diseases.

The results of the microbiological swabs present interesting findings. In patients with an initially positive baseline cultivation, there was a higher proportion of negative results of swabs after one week of treatment in the DROPsept group in comparison with the Tobrex group (73% vs. 57%). The persistent positive finding at T1 consisted exclusively of Staphylococcus species strains, which are coagulase-

negative staphylococci with lower virulence, whose clinical significance in blepharitis is questionable. The higher proportion of positive baseline cultivations in the DROPsept group (55% vs. 35%) is probably due to the small number of patients, and does not necessarily reflect the actual difference between the groups. Chlorhexidine as an antiseptic agent acts on the bacterial cell wall without the risk of developing resistance, in which its effect on the biofilm of the Meibomian glands may be clinically relevant [6]. Tobrex (tobramycin) as an aminoglycoside antibiotic has a bactericidal effect by binding to ribosomes, although it does not act primarily on the biofilm, and repeated use entails the risk of resistance [5].

The results of our study are in accordance with the data from the study conducted by Romano et al. (2024), who demonstrated a significant reduction of bacterial colonization on the ocular surface after three-day application of DROPsept before cataract extraction, and its markedly better tolerance in comparison with povidone-iodine 0.6% [8]. Within the context of cataract surgery in patients with chronic blepharitis, prophylactic application of DROPsept could represent a viable alternative to antibiotic prophylaxis with respect to reducing the risk of developing resistance, while maintaining patient comfort.

A limitation of our study is the relatively small cohort of patients (n = 40) and the fact that it was not double-blind. The study was an open, quasi-randomized clinical evaluation with inclusion of patients, which is not fully equivalent to actual randomization. The loss of patients at T2 (8 out of 40, i.e. 20%) places a limitation on the statistical strength of the results at this point in time. A further limitation of the study is the lack of a BSS value for one patient at the follow-up at T1 and T2, which was addressed by analyzing the available data. Another limitation is the fact that both groups applied eyelid hygiene, warming and Meibomian gland massage concurrently with treatment with eye drops, which makes it impossible to differentiate the effect of the drops themselves from non-pharmacological therapy. Our work serves as a pilot study. In order to formulate definitive conclusions, a more extensive, prospective randomized and placebo-controlled trial is required.

CONCLUSION

DROPsept demonstrated a statistically significantly more rapid improvement of the BSS score after one week of treatment ($p = 0.033$) and statistically significantly higher patient satisfaction with the applied treatment ($p = 0.013$). The numerically higher degree of eradication of bacterial colonization in the DROPsept group (73% vs. 57%) did not reach the level of statistical significance ($p = 0.627$), probably as a consequence of the small number of patients with a positive baseline result of the bacterial swab. The advantage of DROPsept is the reduction of the risk of developing antibiotic resistance, while maintaining a favorable safety profile. This is a pilot project in which we confirmed the better efficacy of DROPsept in chronic blepharitis in comparison with Tobrex. Nevertheless, further trials which evaluate the effect of DROPsept on a large cohort of patients are required.

REFERENCES

1. Heissigerová J et al. Oftalmologie. 3. vyd. Praha: Mladá fronta; 2021. Kapitola 4.1.2.4, Záněty okrajů víček (blefaritidy); s. 89-91.
2. Rynerson JM, Perry HD. DEBS – a unification theory for dry eye and blepharitis. Clin Ophthalmol. 2016;10:2455-2467. doi: 10.2147/OPTH.S114674
3. Tariq F, Hehar NK, Chigbu DI. The Ocular Surface Microbiome in Homeostasis and Dysbiosis. Microorganisms. 2025;13(9):1992
4. Ciulla TA, Starr MB, Masket S. Bacterial endophthalmitis prophylaxis for cataract surgery: an evidence-based update. Ophthalmology. 2002;109(1):13-26. doi: 10.1016/s0161-6420(01)00899-x
5. Asbell PA, DeCory HH. Antibiotic resistance among bacterial conjunctival pathogens collected in the Antibiotic Resistance Monitoring in Ocular Microorganisms (ARMOR) surveillance study. PLoS One. 2018;13(10):e0205814. doi: 10.1371/journal.pone.0205814
6. Caruso C, Porta A, Tosco A, et al. A Novel Vitamin E TPGS-Based Formulation Enhances Chlorhexidine Bioavailability in Corneal Layers. Pharmaceutics. 2020;12(7):642. doi: 10.3390/pharmaceutics12070642
7. Caruso C, Eletto D, Tosco A, et al. Comparative Evaluation of Antimicrobial, Antiamoebic, and Antiviral Efficacy of Ophthalmic Formulations. Microorganisms. 2022;10(6):1156. doi: 10.3390/microorganisms10061156
8. Romano V, Ferrara M, Gatti F, et al. Topical Antiseptics in Minimizing Ocular Surface Bacterial Load Before Ophthalmic Surgery: A Randomized Controlled Trial. Am J Ophthalmol. 2024;261:165-175. doi: 10.1016/j.ajo.2024.01.007