

ULTRASOUND EXAMINATION OF THE ORBIT IN PATIENTS WITH THYROID-ASSOCIATED ORBITOPATHY - EXAMINATION GUIDE AND RECOMMENDATIONS FOR EVERYDAY PRACTICE. A REVIEW

Karhanová M.^{1,2}, Čivrný J.^{3,4}, Kalitová J.¹, Schovánek J.^{5,6},
Malušková M.^{1,2}, Hrevuš M.^{1,2}, Schreiberová Z.^{1,2}

¹Department of Ophthalmology, University Hospital Olomouc, Czech Republic

²Department of Ophthalmology, Faculty of Medicine and Dentistry, Palacky University Olomouc, Czech Republic

³Department of Radiology, University Hospital Olomouc, Czech Republic

⁴Department of Radiology, Faculty of Medicine and Dentistry, Palacky University Olomouc, Czech Republic

⁵^{3rd} Department of Internal Medicine, University Hospital Olomouc – nephrology, rheumatology and endocrinology, Czech Republic

⁶^{3rd} Department of Internal Medicine, Faculty of Medicine and Dentistry, Palacky University Olomouc – nephrology, rheumatology and endocrinology, Czech Republic

The authors of the study declare that no conflict of interests exists in the compilation, theme and subsequent publication of this professional communication, and that it is not supported by any pharmaceuticals company. The authors further declare that the study has not been submitted to any other journal or printed elsewhere, with the exception of congress abstracts and recommended procedures.

Supported from the programme project of the Ministry of Health of the Czech Republic with reg. no. NU21J-01-00017. All rights reserved according to the prescriptions on the protection of intellectual property. Supported by the Ministry of Health of the Czech Republic – RVO (FNOI, 00098892).

Received: 28 November 2022

Accepted: 2 January 2023

Available on-line: 20 February 2023



Marta Karhanová, MD, PhD, FEBO
Oční klinika, Fakultní nemocnice
Olomouc
Oční klinika, Lékařská fakulta
Univerzity Palackého Olomouc
I. P. Pavlova 6
775 20 Olomouc
E-mail: marta.karhanova@fnol.cz

SUMMARY

The purpose of this study is to present the possibilities and benefits of ultrasonography (US) of the orbit in the diagnosis and treatment of thyroid-associated orbitopathy (TAO).

Methods: US examination of the orbit is a very important addition to clinical and laboratory examination in patients with TAO. Nevertheless, it is often neglected in clinical practice, or indicated only after a relatively long interval. Based on published findings and our experience with the diagnosis and treatment of TAO patients, it is our aim to highlight the clear benefit of US examination of the orbit and oculomotor muscles, not only in the timely diagnosis of TAO, but also in the monitoring of the disease over time. However, knowledge of the drawbacks and limitations of this method is also very important, as we shall point out. It is always necessary to keep in mind that US examination must be evaluated in connection with the clinical findings. A detailed recommendation for US examination of the extraocular muscles and the orbit based on our experiences with the diagnosis and treatment of TAO patients in daily practice is also included.

Conclusion: According to our experience, US examination of the orbit is an excellent and irreplaceable tool for the timely diagnosis of TAO and for further monitoring of the disease. However, considerable experience on the part of the examiner and detailed knowledge of the clinical and ultrasound manifestations of TAO is essential.

Key words: thyroid-associated orbitopathy, ultrasound, extraocular muscles, activity

Čes. a slov. Oftal., 79, 2023, No. x, p. x–x

INTRODUCTION

Thyroid-associated orbitopathy (TAO) is a serious chronic ocular pathology associated with autoimmune disorder of the thyroid gland (TG). It most commonly affects patients with Graves-Basedow disease (GB), though it may also affect patients with other types of autoimmune disorders of the thyroid gland. Even in the absence of currently detectable affliction of the TG, TAO cannot be excluded, and must be taken into consideration within the framework of differential diagnostics. Determination of the correct diagnosis may then be relatively complicated, and requires thorough knowledge of the symptoms and dynamics of TAO.

In the case of occurrence of typical subjective complaints and a clinical ophthalmological finding, determination of a diagnosis of TAO is not generally difficult, especially if it concerns a patient with a known disorder of the TG. However, diagnostic confusions frequently result due to atypical forms of TAO, TAO in combination with another pathology, and TAO in patients without a medical history of TG disorder. Even despite a carefully recorded medical history and detailed clinical examination, imaging of the extraocular muscles and other orbital tissues is necessary for confirmation of TAO.

Imaging methods play an irreplaceable role, not only in the diagnosis of TAO but also in monitoring the development of the disease and response to the applied treatment. The most frequently used imaging methods of the orbit include ultrasound examination (US), computed tomography (CT) and magnetic resonance imaging (MRI).

We focus on the benefits and limitations of MRI and CT in another study. The aim of this study is to provide readers with a clearly presented review of the current possibilities and limitations of ultrasound examination of the orbit in the diagnosis of TAO. Basic ultrasound findings are presented in brief in the Recommended Procedure for the Diagnosis and Treatment of Thyroid-Associated Orbitopathy, amendment 3/2022, which is freely available for download on the websites of the Czech Endocrinology Society and Czech Ophthalmology Society of J. E. Purkyně [1,2]. Our aim is not only to elaborate upon this issue in further detail, but in particular to highlight its benefits and limitations. On the basis of several years of experience with the diagnosis and treatment of TAO, we have progressively introduced into practice an examination algorithm for all patients with suspected and already verified TAO, an essential component of which is US examination of the orbit, which is performed at our centre by an ophthalmologist. We would also like to familiarise readers with this examination procedure.

The history of ultrasound in ophthalmology, physical principle, types of imaging

The first studies in ophthalmology on the use of ultrasound appeared in 1956 and 1957. Mund and Hughes in the USA primarily investigated the possibilities of detecting intraocular tumours with the aid of an A-scan. A contribution to the further development was then made by Oksala and

Lehtinen in Finland. In 1958 the use of a two-dimensional B-scan was also introduced in ophthalmology, thanks to the endeavours of Baum and Greenwood. In former Czechoslovakia, the development and introduction of ultrasound into practice was especially thanks to the work of Vanýšek and Preisová [3]. At present, the majority of ophthalmologists in the Czech Republic draw upon the highly successful book by Dr. Baráková as a source of fundamental information [3].

Ultrasound is a term used to designate the mechanical vibration of particles in the environment around an equilibrium rest position with frequencies higher than 20 kHz (inaudible to the human ear). The ultrasonic wave is disseminated through the material environment in the form of a longitudinal or transverse wave. It is then reflected and refracted on an acoustic interface, depending on the difference of the acoustic impedances of the environment that forms this interface. We refer to the reflected ultrasonic wave as an echo. The greater the difference in the acoustic impedances of both media, the greater the reflection of the ultrasonic wave. For diagnostic purposes in ocular medicine, ultrasonic waves with a frequency of 8 to 10 MHz are used. At these frequencies very short waves are created, shorter than 0.2 mm, which effectively penetrate ocular and orbital structures [3]. Echoes may be imaged by various different methods. In ophthalmology we most frequently encounter the following types of imaging:

A-scan is historically the oldest type of imaging. The designation A-scan is derived from the term "Amplitude modulated". It concerns a one-dimensional, linear method of imaging in the direction of the transmitted ultrasonic waves. The individual echoes are illustrated by means of consecutive vertical deviations from the baseline. The distance of the deviations corresponds to the actual distances of the individual tissue interfaces, and the height of the echo corresponds to the size of the received acoustic impulse [3,4]. The advantage of this imaging consists especially in the possibility of precise measurement of the structures by determining the distance between the relevant amplitudes. On the other hand, topographic and shape orientation is more difficult in this case. The correct performance and interpretation of the examination requires considerable experience on the part of the examiner. In ophthalmology, the use of the A-scan method is indispensable especially for biometry (measurement of the length of the eye) and for tissue differentiation. At present, A-scanning is most frequently used in combination with B-scanning.

B-scan is planar two-dimensional imaging, which utilises brightness modulation. The designation is derived from the term "Brightness modulated". Reflections from the individual structures are registered as points with various brightness (32–256 degrees of grey are used according to the type of instrument). Static B-scanning is no longer used today. Dynamic B-scanning enables the smooth, continuous monitoring of the dynamic of the observed structures. The main advantage of a dynamic B-scan in real time is its relative simplicity and the faster learning curve on the part of the examiner in comparison with A-scanning. It presents

information in particular about the position, shape and size of the investigated structure.

A speciality of ophthalmology is "standardised echography". This is a special method of ultrasound examination which was developed and introduced into ophthalmological practice by Ossoinig in 1960s. It concerns the use of an instrument with a standardised A image and a contact B image in real time. The standardised instruments are characterised by a special type of amplification – referred to as S amplification, which enables the optimal imaging of the tissue echo (as against logarithmic or linear amplification). All of this enables very precise detection, differentiation, localisation and measurement of the dimensions of the intraocular and orbital afflictions [3]. The majority of ultrasonic instruments offered in ophthalmological practice do not have this standardisation (in some cases it is possible to request it). However, this is not an essential condition for the examination of patients with TAO.

Ultrasound biomicroscopy (UBM) is used for detailed examination of the anterior segment of the eye with the aid of an immersion technique, in which ultrasonic gel is inserted in a flyleaf between the probe and the area being examined.

Doppler imaging is designated for detecting and measuring movement, primarily for measuring the velocity of blood flow in vessels. The "duplex method" is a combination of two-dimensional imaging with a pulse-Doppler module. The introduction of colour coding of blood flow has facilitated the orientation and measurement of the haemodynamic parameters in the blood vessels.

Ultrasound elastometry is a method designated for measuring the rigidity (elasticity) of tissue. In the field of ophthalmology it so far still remains the subject of further study.

Technique of ultrasound examination of the eye and orbit

Sonographic examination of the eye and orbit is performed under local anaesthesia, following the application of one drop of anaesthetic into the conjunctival sac. In the case that the examination is performed across the eyelid with good patient co-operation, it is possible to perform the examination also without local anaesthesia. The patient is usually examined in a lying position, examinati-

on in a sitting position is performed only in exceptional cases. For examination of the posterior segment of the eye and orbit we use a contact method of examination, in which we apply the ultrasonic probe directly onto the eye or eyelid. For examination with a B-probe we use a special ultrasound gel as a binding acoustic medium.

Certain recommended procedures and principles apply for the examination of the eye and orbit, in which we differentiate between basic and special examination techniques. In basic US examination of the eyeball and eye socket we perform a B-scan and A-scan simultaneously. In practice we perform the examination by placing the ultrasonic probe on the eyelids (transpalpebral application). This procedure is more comfortable for the patient, though during it the ultrasonic signal is weakened upon the passage of the ultrasonic waves through the tissues of the eyelid. The examiner also does not have direct control over the position of the eye. The application of an ultrasonic probe to the conjunctiva is less pleasant for the patient, but on the other hand it is more conclusive for the examiner. We perform ultrasound examination of the orbit either by the transocular (Fig. 1) or paraocular method (Fig. 2). The transocular approach is used especially for examination of the middle and posterior part of the orbit, including its apex. The paraocular approach is more suitable for examination of the anterior part of the orbit.

In our experience, in the majority of cases transpalpebral examination is sufficient for the examination of patients with TAO, and prior local anaesthesia is not even required for patients who co-operate well. However, we must caution the patient of the necessity to keep the eyes closed throughout the entire duration, and before opening the eyes to carefully wipe away the ultrasound gel from the eyelids. We perform the examination by the transocular method, as described above.

In the transocular approach (similarly as upon examination of the eyeball) we distinguish between three basic echographic images – transverse, longitudinal and axial (Fig. 3). In the transverse image we apply the probe to the eye parallel to the corneal limbus in individual hours on the clock face. According to the position of the probe mark, we differentiate between a horizontal, ver-

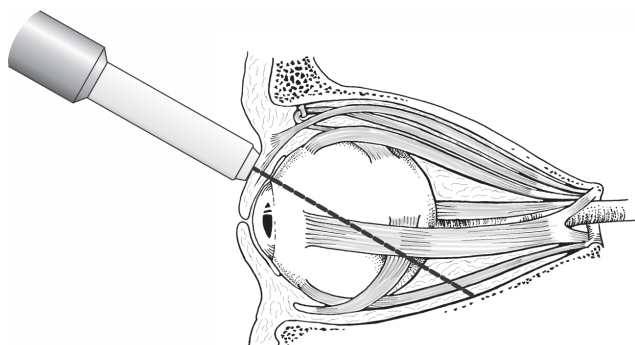


Fig. 1. Ultrasound examination of orbit: schematic representation of transocular method of examination of orbit

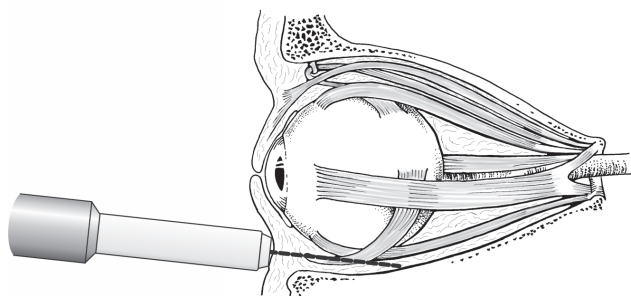


Fig. 2. Ultrasound examination of orbit: schematic representation of paraocular method of examination of orbit

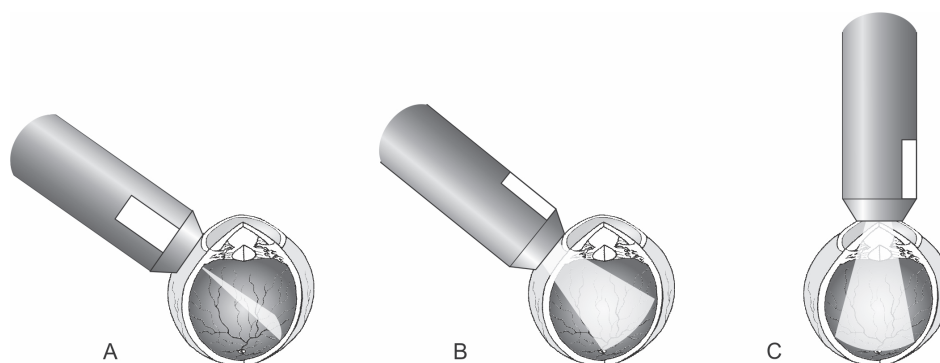


Fig. 3. Basic positions of B-probe during transocular UZ imaging: **(A)** transverse, **(B)** longitudinal, **(C)** axial

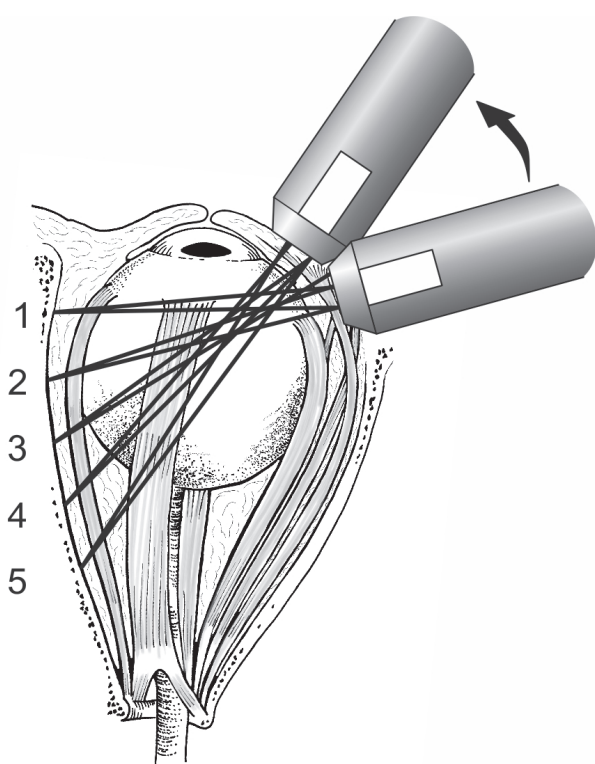


Fig. 4. Probe position in dynamic B-scan imaging when examining rectus muscle from its attachment (1) to orbital apex (5) – transverse image

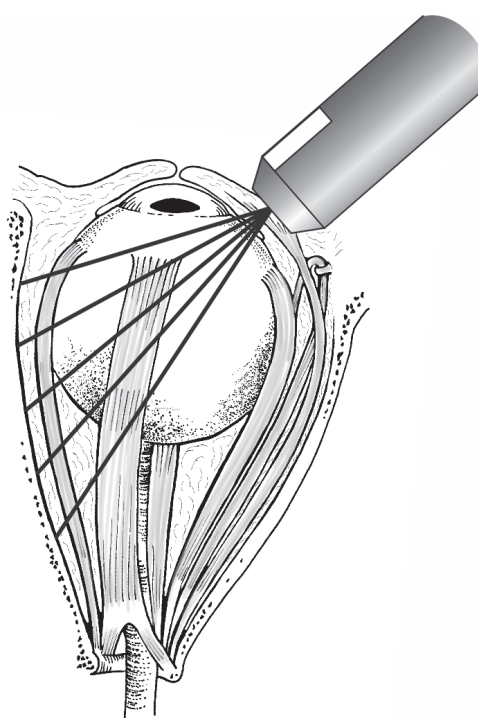


Fig. 5. B-scan of musculus rectus in transverse image – the muscle is shown in cross-section as a round slice of hypoechoic structure in the orbital echogram

tical and diagonal transverse image. The probe is always placed against the meridian which is being examined. Upon application of the probe in meridian 6 and 12 the probe mark is oriented nasally, in other cases the probe mark faces upwards. In the longitudinal image we apply the probe perpendicular to the corneal limbus. We thereby obtain a front-to-back cross-section through the orbit. If we apply the probe directly to the centre of the cornea, we obtain an axial image. We differentiate between axial horizontal, axial vertical and axial diagonal images.

Technique of ultrasound examination of extraocular muscles

Sonography of the extraocular muscles is a beneficial examination method for the detection of changes of their thickness. Its contribution consists in examination upon suspicion of thyroid-associated orbitopathy, myositis, tumour (e.g. metastatic carcinoma) and haematoma of the muscle [4]. We examine the muscles in the primary position of the eyeball, and we always compare the findings laterally. We are able to examine all the extraocular rectus muscles, though examination of the extraocular

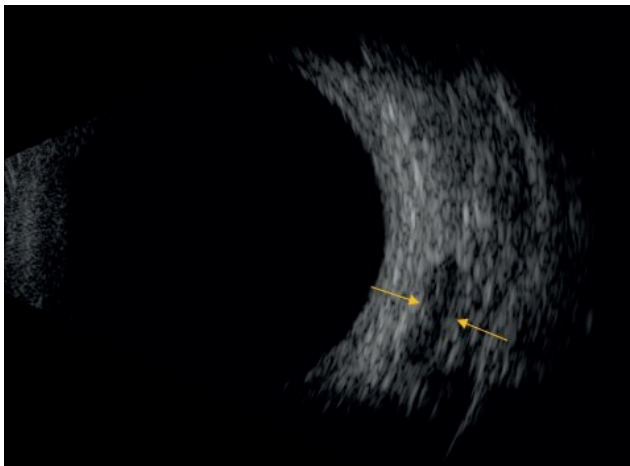


Fig. 6. Probe position in B-scan, longitudinal view – when examining the rectus muscle, the probe mark points towards the cornea

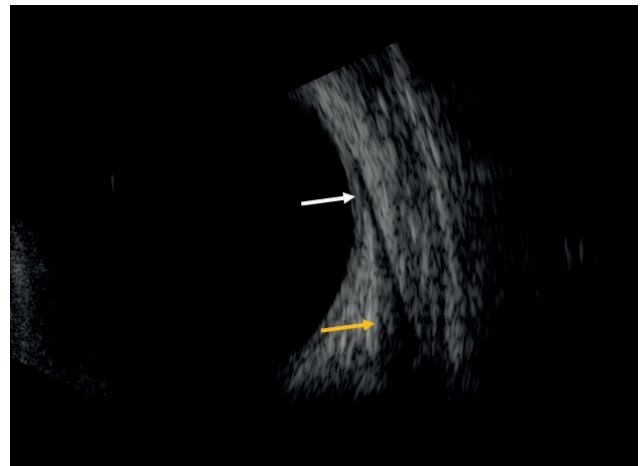


Fig. 7. B-scan of rectus muscle in longitudinal view, in the upper part of the echogram the insertion of the muscle is visible (white arrow), in the lower part the muscle belly (yellow arrow)

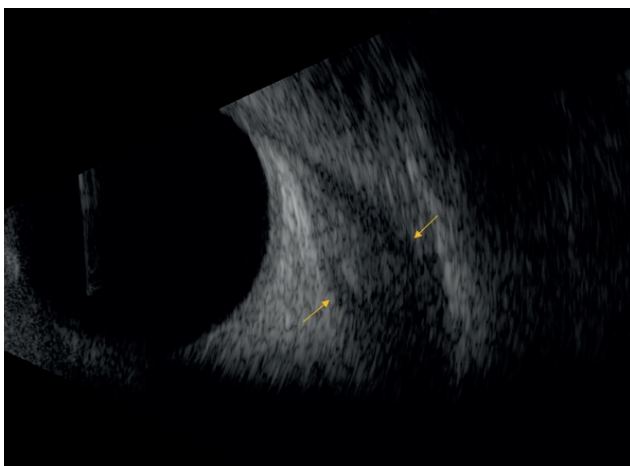


Fig. 8. Enlargement of rectus muscle in patient with thyroid-associated orbitopathy in active phase of disease during treatment (muscle is still edematous) in view B, longitudinal view

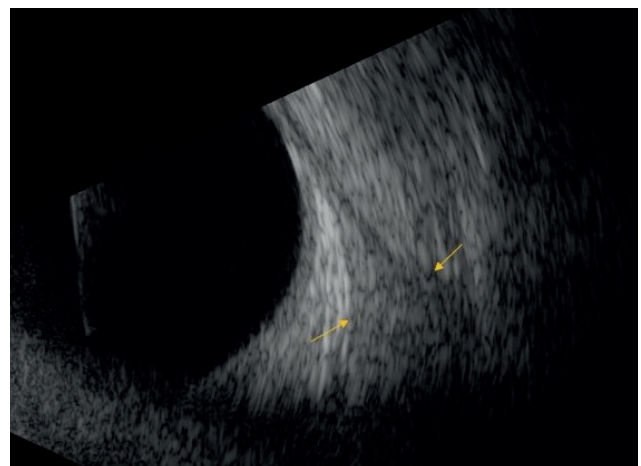


Fig. 9. Enlargement of rectus muscle in patient with thyroid-associated orbitopathy in inactive phase of disease (muscle is fibrotic) in view B, longitudinal view

oblique muscles requires a special examination procedure, and is not routinely performed in practice.

In A-scanning the muscle is shown as a depression of echoes in the complex of high orbital echoes. The muscle fascia is highly reflective, whereas the muscle itself is homogeneous, with regular medium reflectivity. During the examination we apply the probe to the opposite side of the eyeball from that of the muscle being examined, in the place of the equator so that the ultrasonic waves impact perpendicularly onto the muscle. On the echogram we thus obtain two high echoes, which represent the anterior and posterior bordering of the muscle. We examine the muscle from its ligament in a direction towards the muscle cone. We measure the width of the muscle in its widest point, in the case of thyroid-associated orbitopathy on the interface of the second and final third of the muscle.

In B-scanning we examine the extraocular muscles

mostly in medium values of intensity of the ultrasonic signal. However, we frequently begin by first of all setting the highest intensity, which we progressively reduce until we attain a clear image of the muscle. We place the probe on the opposite point in relation to the muscle under examination, on the equator of the eyeball (Fig. 4 and 5). In the transverse image the muscle is shown in a transverse cross-section as a rounded or oval section of a hypoechogenic structure in the orbital echogram (Fig. 6). By its ligament it appears only as a narrow defect in the orbital echogram in the vicinity of the sclera. Upon motion of the probe in a backwards direction (we examine the belly of the muscle), the echogram of the muscle progressively widens. In the longitudinal image we direct the probe mark always in the direction towards the cornea. The muscle is shown in its length from the equator to the muscle cone. Upon this procedure, its ligament is visible in the upper part of

the screen, with the wider muscle belly in the lower part of the screen (Fig. 7). Higher echogeneity is evident by the muscle ligament. However, the region of the orbital apex cannot be displayed by a 10 MHz probe.

Ultrasound findings in thyroid-associated orbitopathy

The indications for imaging methods (as well as the advantages and disadvantages of the individual methods) for patients with TAO can be found in summary form in the Recommended Procedure for the Diagnosis and Treatment of Thyroid-Associated Orbitopathy, amendment 3/2022, which is freely available for download on the websites of the Czech Endocrinology Society and Czech Ophthalmology Society of J. E. Purkyně [1]. However, we would like to elaborate on this issue in further detail.

Changes in TAO may be shown in the ultrasound image in the form of a **change of the thickness of the extraocular muscles, and in a change of their structure and reflectivity**. Another sign may be the expansion of the orbital echogram in the case of edema of the soft orbital tissues.

Changes in the extraocular muscles in the first phase of the disease are manifested in their loaf-like swelling in the orbital part of the muscle, in particular in the central and posterior third. In this phase the muscles can still

be well differentiated with regard to their hypoechogenic surrounding area (Fig. 8). In the further course of the pathology there is a gradual merging of the reflectivity of the individual parts of the muscle, in which their reflectivity increases, becoming iso- to hyperechogenic, until they virtually merge with the orbital fat (Fig. 9). The muscles then become difficult to differentiate from the orbital fat, and measurement of their width becomes complicated.

Assessment of changes in the reflectivity of orbital fat, which has been described in the literature, requires considerable experience on the part of the examiner. Ultrasonic demonstration of the potential compression of the optic nerve in TAO consists in the measurement of its dural and arachnoid parameter, and also requires considerable experience. Other potential ultrasound findings in TAO also include thickening of the periorbit and enlargement of the lachrymal gland.

In most cases, expansion of the extraocular muscles in TAO has a characteristic image in ultrasound examination. Nevertheless, upon a finding of an enlarged extraocular muscle (or a number of muscles), it is necessary also to consider other causes in differential diagnostics. The most common typical sonographic findings in various different pathologies, which cause an expansion of the extraocular muscles, are presented in Table 1 [4].

Whereas in healthy individuals the extraocular muscles

Table 1. The most common typical echographic findings of disorders causing enlargement of the extraocular muscles [4]

Disorder	Reflectivity	Internal structures	Insertions
Thyroid-associated orbitopathy	Medium-high	Irregular	Normal
Myositis	Low	Regular	Thickened
Tumors	Low-medium	Regular	Normal
Venous congestion	Medium-high	Variable	Normal
Hematoma	Low-medium	Regular	Variable

Table 2. Normal extraocular muscle values, Byrne et al. [4]. However, the values reported in the literature can vary significantly

Superior rectus/levator complex	3.9–6.8 mm
Lateral rectus	2.2–3.8 mm
Inferior rectus	1.6–3.6 mm
Medialis rectus	2.3–4.7 mm

Table 3. Indications for ultrasound examination of the orbit and extraocular muscles in patients with thyroid-associated orbitopathy (TAO)

- Initial evaluation of a patient with TAO
- Assessment of the activity on the extraocular muscles – decision about systemic immunosuppression
- Evaluation of the extinction of activity (degree of fibrotization) on the extraocular muscles – before strabismus surgery
- Tracking the findings over time (monitoring the treatment effect)

Table 4. Advantages and disadvantages of echographic examination of the orbits in patients with thyroid-associated orbitopathy

Advantages	Disadvantages
<ul style="list-style-type: none"> • financially undemanding • relatively quick examination • enables evaluation of changes in the anterior 2/3 of the orbit • B-scan visualizes the condition of the oculomotor muscles well • no radiation exposure • possible re-examination of patients and monitoring of responses to treatment 	<ul style="list-style-type: none"> • does not show the status in the back part of the orbit • does not allow the clear exclusion of other pathology in the orbit • possible measurement inaccuracy • measurement results depend on the examiner and his experience • poor standardization of examinations • difficult to visualize the vertical oculomotor muscles

are typified by their ellipsoid shape, in patients with TAO they become “rounded” – i.e. there is an enlargement of their short diameter with a maximum in the central and posterior third of the muscle. Upon evaluation of the width of the extraocular muscles, it is therefore recommended that their shorter diameter is evaluated. Another typical sign of TAO is an unaffected muscle ligament. This sign is considered fundamental in differential diagnostics between TAO and orbital myositis. In the majority of cases, we find bilateral asymmetrical affliction of the extraocular rectus muscles. A difference of more than 0.5 mm in the maximum width of the muscle between the same muscles of both orbits attests to a diagnosis of TAO. Another criterion is expansion of the extraocular muscles beyond 95 percent. The norms for the width of the extraocular muscles differ markedly in the published literature. Table 2 presents an overview of the norms according to Byrne et al. [4], which we take as our referential basis at our centre. Also typical of TAO is variability of the finding, also in short time intervals. We therefore always recommend ultrasound monitoring of the patient over time.

In routine practice, in addition to a complete ophthalmological examination of the anterior and posterior segment and rigorous examination of motility and measurement of the degree of exophthalmos, for all patients with TAO we also perform US examination of the orbit, and we evaluate the finding on the extraocular muscles. US examination of the vertical extraocular muscles is frequently complicated (anatomical relations, opaque US finding). For these reasons, in routine daily practice often only the horizontal extraocular muscles are examined [5]. At our centre we always examine the internal and external extraocular rectus muscle, and in the case of suspicion of affliction of the inferior rectus muscle we also attempt to examine this muscle. However, we are aware of the relative imprecision of measurement, and in these cases we almost always indicate a supplementary imaging method (most commonly MRI, in which it is also possible to evaluate the activity of the pathology).

Another disadvantage of US examination of the width of the extraocular muscles is the relatively large interindividual variability and the burden caused by subjective error. This disadvantage has been highlighted also by numerous studies focusing on the correlation of individual imaging methods for the measurement of the extraocular muscles, the results of which are not consistent [6–9]. There are several possible explanations for this. Sonographic measurement of the maximum width of the extraocular muscle is dependent upon the position of the probe, and the examiner is not always capable of ensuring that the ultrasonic waves impact entirely perpendicular to the muscle under examination in the place of its widest diameter. Even an expanded extraocular muscle afflicted by TAO is still rather of an oval shape, and it is therefore necessary to pay close attention also to the position of the probe mark. At our centre we therefore always attempt to adhere to the principle that over the course of time the patient is always examined only by a single examiner, and as a result the comparison of the results of measurement, in particular suspected pro-

gression or regression of the finding should therefore be subject to a smaller burden of error.

We also must not forget the fact that US examination of the orbit in patients with TAO must always be evaluated in connection with the clinical picture. The US image enables us to evaluate not only the width of the extraocular muscles, but also the activity of the process (edema or fibrotisation in the muscles). We always check the finding on the extraocular muscles also on patients in whom we record an elevation of intraocular pressure (IOP). In clinical practice we have recorded repeated cases in which it was precisely an elevation of IOP (in particular upon stable exophthalmos) that was a sign of progression of the finding on the extraocular muscles. We subsequently confirmed this observation in a published study [10]. It is therefore always a considerable advantage if US examination is performed by the ophthalmologist himself/herself. If the US examination is performed by an endocrinologist or radiologist, this doctor should have the ophthalmological finding at their disposal, as well as the possibility of consulting the ophthalmologist who referred the patient concerning the result of the examination.

The indications for performance of US examination in patients with TAO are presented in summary in Table 3. The advantages and disadvantages of US examination are presented in summary in Table 4.

Colour Doppler imaging is only rarely used in routine practice for this diagnosis. However, it has been demonstrated that measurement of blood flow in the central retinal artery, the central retinal vein and the ophthalmic artery correlates with the width of the extraocular muscles [11]. Reduction of blood flow through the ophthalmic vein is a possible sign of severe orbitopathy, and may indicate the danger of neuropathy [12]. This method should be of benefit also for differentiation between the active and inactive phase of the disease [13].

The clinical significance of ultrasound elastometry for the diagnosis of changes in the muscles upon a background of TAO also so far still remains the subject of further study [14].

CONCLUSION

US of the orbit, in particular the width and structure of the extraocular muscles, has an indispensable place within the diagnosis of TAO. However, it is always necessary to evaluate the US finding in connection with the clinical finding. This method is very useful also when monitoring a patient with TAO over time, although in this case we recommend that all the examinations are performed by a single examiner. With regard to the fact that a large number of ophthalmological centres now have a US instrument at their disposal, it would be of significant benefit if this examination were performed as standard for every patient with suspicion of TAO. However, we must not forget the limitations of this method, and in indicated cases it is always necessary to perform one of the other imaging methods of the orbit (MRI, CT).

REFERENCES

1. Jiskra J, Gabalec F, Diblík P et al. Doporučený postup pro diagnostiku a léčbu endokrinní orbitopatie, NOVELIZACE 3/2022 n.d.
2. Česká oftalmologická společnost ČLS JEP. Doporučený postup pro diagnostiku a léčbu endokrinní orbitopatie [internet]. Available from: www.oftalmologie.com/cs/doporučene-postupy/doporučeny-postup-pro-diagnostiku-a-lecbu-endokrinni-orbitopatie.html Czech. n.d.
3. Baráková D. Echografie v oftalmologii. Kamil Mařík – Professional Publishing 2001, p.152.
4. Byrne SF, Green RL. Ultrasound of the eye and the orbit. St. Louis, Missouri, Mosby 2002, p.505
5. Fledelius, C., Zimmermann-Bielsing, T., Feldt-Rasmussen, U. Ultrasonically measured horizontal eye muscle thickness in thyroid associated orbitopathy: cross-sectional and longitudinal aspects in a Danish series. *Acta Ophthalmol Scand.* 2003;81:143-150.
6. Vlainich AR, Romaldini JH, Pedro AB et al. Ultrasonography compared to magnetic resonance imaging in thyroid-associated Graves' ophthalmopathy. *Arq Bras Endocrinol Metabol.* 2011;55(3):184-188.
7. Lennerstrand G, Tiam S, Isberg B et al. Magnetic resonance imaging and ultrasound measurements of extraocular muscles in thyroid-associated ophthalmopathy at different stages of the disease. *Acta Ophthalmol Scand.* 2007;85:192-201.
8. Nagy EV, Toth J, Kaldi I et al. Graves' ophthalmopathy: eye muscle involvement in patients with diplopia. *Eur J Endocrinol.* 2000;142(6):591-597.
9. Karhanova M, Kovar R, Frysak Z. et al. Correlation between magnetic resonance imaging and ultrasound measurement of eye muscle thickness in thyroid-associated orbitopathy. *Biomedical Papers.* 2015;159(2):307-312.
10. Karhanová M, Kalitová J, Kovář R et al. Ocular hypertension in patients with active thyroid-associated orbitopathy: a predictor of disease severity, particularly of extraocular muscle enlargement. *Graefes Arch Clin Exp Ophthalmol.* 2022 Jul 14. doi: 10.1007/s00417-022-05760-0. Epub ahead of print
11. Alp MA, Ozgen A, Can I et al. Colour Doppler imaging of the orbital vasculature in Graves' disease with computed tomographic correlation. *Br J Ophthalmol.* 2000;84(9):1027-1030.
12. Monteiro ML, Moritz RB, Angotti Neto H et al. Color Doppler imaging of the superior ophthalmic vein in patients with Graves' orbitopathy before and after treatment of congestive disease. *Clinics (Sao Paulo).* 2011;66(8):1329-1334.
13. Walasik-Szemplińska D, Pauk-Domańska M, Sanocka U, Sudół-Szopińska I. Doppler imaging of orbital vessels in the assessment of the activity and severity of thyroid-associated orbitopathy. *J Ultrasound.* 2015;15(63):388-397.
14. Yuksel N, Unal O, Mutlu M, Ergeldi G, Caglayan M. Real-time ultrasound elastographic evaluation of extraocular muscle involvement in Graves' ophthalmopathy. *Orbit.* 2020;39(3):160-164.