

BENEFITS AND NEGATIVES OF CORTICOSTEROID THERAPY IN CORNEAL PATIENTS

SUMMARY

BENEFITS AND NEGATIVES OF CORTICOSTEROID THERAPY IN CORNEAL PATHOLOGIES

Introduction: Corticosteroid therapy is very beneficial in many types of eye diseases. Corticosteroids are used in the treatment of inflammatory and immunological diseases of the eye.

Purpose: The aim is to present basic informations about effects of steroids in tissues, their side effects and treatment strategy.

Methods and results: Authors process overview of local and systemic steroids and their dosage forms. They refer to the most common problems associated with corticosteroid therapy.

Conclusion: Although corticosteroids include medicine across to one of the most frequently prescribed drugs at all, it is always necessary to treat very carefully indicate any corticosteroid preparation and prior to its administration to eliminate all infectious diseases, take a thorough anamnesis and complete examine the patient.

Key words: cornea, corneal healing, inflammatory cascade, corticosteroids

Čes. a slov. Oftal., 73, 2017, No. 2, p. 69–77

INTRODUCTION

The cornea is an avascular tissue, in which the absence of blood vessels in the cornea is a fundamental condition for its transparency. The cornea has a slow metabolism and healing, and has no lymphatic drainage. Nutrition of the cornea is not supplied through blood (the cornea is an avascular, bradytrophic tissue, similarly to the sclera, lens and vitreous body), but by three different systems: diffusion of nutrients from the capillaries of the limbus, diffusion and active transport from the chamber fluid (primarily glucose) and diffusion from the pre-corneal lachrymal film (primarily oxygen) (7).


Histologically the cornea is composed of six layers: the epithelium, Bowman's membrane, stroma, Dua's layer, Descemet's membrane and the endothelium (fig. 1). The corneal epithelium forms 10% of its thickness and is composed of 5-6 layers of non-keratinising, non-secreting cells – the basal layer of cubic to lowly cylindrical cells, which are capable of division and progressively migrate to the surface of the epithelium, two layers of polyhedral (polygonal, wing) cells, which are also capable of division, and where the nerve endings are located, and on the surface 2-3 layers of flat (squamous) cells, which have microvilli on the application side, which enables adherence of mucin to the lachrymal film. Epithelial cells are programmed to die, decaying cells imbricatively separate into the lachrymal film. The corneal epithelium is a permeable barrier for small molecules, water and ions, and is a barrier against the entry of pathogens. The epithelium constantly regenerates every 7-10 days (thanks to the limbal cells). The lachrymal film (7 µm) on the surface of the cornea forms an important refractive environment, and protects the surface of the epithelium (mechanical and immunological protec-

tion). The Bowman's membrane (lamina limitans anterior) has a thickness of 8-12 µm, and concerns a homogeneous, acellular, sharply bordered layer. It is composed of thin and randomly crossing collagen fibrils and condensed interfibrillar substance. The Bowman's membrane shares in ensuring the rigidity of the cornea, and upon injury does not have the capacity for regeneration, after breaching it forms scars, and if it is damaged by infection an ulcer always forms. The stroma (= substantia propria) represents 90% of the corneal thickness. It is composed of regularly arranged collagen fibrils, the extracellular matrix (amorphous substance from proteoglycans, glycosaminoglycans and hyaluronic acid) and cells known as keratocytes (modified fibroblasts located between the fibrils, producing collagen fibrils and the extracellular matrix). Occasionally lymphocytes, macrophages and polymorphonuclear leukocytes are trapped in the stroma. The transparency of the cornea is due to the regular distance of the fibrils and their identical thickness. Hydration of the stroma must be constant, if the water content increases the individual fibrils are squeezed by the swelling of the mucopolysaccharides, edema is generated and the cornea becomes turbid. The stroma has a very low capacity for regeneration. The Dua's layer is a newly discovered layer between the stroma and the Descemet's membrane, with a thickness of 15 µm, it is very rigid and acellular. It has recently been determined that it plays a role in the etiopathogenesis of ectatic pathologies, corneal dystrophies, upon descemetocoele or acute hydrops of the cornea. It was discovered by the British doctor Harinder Dua, who confirmed its existence between the Descemet's membrane and the stroma with the aid of experiments with air bubbles, upon careful observation of the cornea through an electron microscope. Its discovery enables eye surgeons to proceed with greater precision upon corneal transplants

Zemanová M., Matušková V.

Department of Ophthalmology, University Hospital and Faculty of Medicine, Masaryk University Brno, Head prof. MUDr. Eva Vlková, CSc.

The authors of the study declare that no conflict of interest exists in the compilation, theme and subsequent publication of this professional communication, and that it is not supported by any pharmaceuticals company.



MUDr. Markéta Zemanová
Oční klinika FN a LF MU Brno
Jihlavská 20, 625 00 Brno
e-mail: marketa.zemanova@fnbrno.cz

(3). The Descemet's membrane (= lamina limitans posterior) is the basal membrane of the endothelium, produced by endothelial cells, and is relatively rigid. With increasing age this membrane thickens (the posterior 2/3 of the membrane develops after birth). It is composed of bundles of collagen (collagen type IV) and elastic fibrils. The Descemet's membrane is rich in glycoproteins (laminin), thanks to which it adheres firmly to the endothelium, prevents the penetration of leukocytes into the corneal stroma, in the periphery passes into the trabecula of the iris-corneal angle and ends in the Schwalbe ring. It is highly resistant to injury and infections, and has the capacity for regeneration (thanks to the functions of the endothelial cells). The Endothelium is composed of one row of flat and regularly hexagonal cells, and has a thickness of 4-6 μm . The endothelium lines the posterior surface of the cornea and the iris-corneal angle, from where it passes into the anterior surface of the iris. The normal number of endothelial cells at birth is 4000-5000 cells/mm², in adulthood the average density is 2700 cells/mm², upon a decrease of the number of cells below 500/mm² a breakdown of hydration of the cornea occurs and edema forms, with reduction of corneal transparency. The endothelium does not regenerate (cells have a limited capacity of mitosis), reparation of the endothelium takes place by means of enlargement (=hypertrophy) and migration of existing cells. The endothelium is responsible for constant hydration and transparency of the cornea, and thereby maintains constant optical robustness, it has a

barrier function (prevents the penetration of chamber fluid into the stroma) and a function of a metabolic pump (active transport thanks to Na/K ATPase) (6, 7).

The cornea is very abundantly innervated, with the largest number of sensitive nerve endings per mm² of all the tissues in the body. Sensitive innervation is ensured by the first branch of the trigeminal nerve (n. trigeminus), via the n. ophthalmicus, n. nasociliaris and nn. ciliares breves. These nerves enter by a circular route in a number of 12-16 into the area of the corneo-scleral limbus, upon passing from the limbus the nerves lose their myelin sheath. In the cornea the end branch then divides into two plexuses: the subepithelial and subbasal plexus (the strongest are the stromal fibres). Together with sensitive innervation, sympathetic (autonomous) innervation enters the cornea by means of the ganglion cervicale superior (7).

The cornea is immunologically privileged tissue thanks to its avascularity, lack of lymphatic drainage and low content of antigen presenting cells. The immune response of the cornea is divided into two components. The non-specific response is composed of the humoral component (i.e. complement system) and the cellular component – cells capable of phagocytosis (leukocytes and dendritic cells). The specific immune response is again composed of the humoral component (B-lymphocytes, cytokines) and the cellular component (T-lymphocytes, Langerhans cells, stromal keratocytes, epithelial and endothelial cells) (11).

Healing of cornea: Regeneration of the epithelium requires the participation of several factors, and is characterised by three phases. The first phase is the phase of migration, which commences 4-5 hours after trauma, and involves interaction between cells. After 24-30 hours there then follows the phase of proliferation, and the last is the phase of differentiation – adhesion. Upon affliction of the cornea, the cells move around the perimeter. The limbal epithelial stem cells are located in the basal layers of the epithelium, in the transitional zone of the cornea and conjunctiva ("limbal palisades of Vogt"), and their daughter cells move to the central regions of the cornea in order to heal the defect. They always first of all heal the defect on the limbus before the central defect of the cornea. During damage to the epithelium (by inflammation, infection or trauma), a proliferation and differentiation of basal cells occurs. IL-1 α is released from the damaged epithelium into the stroma, directly beneath the epithelial defect. In certain keratocytes beneath the location of wound, this indicates apoptosis, in others it causes proliferation and transition from a passive to an activated stage. The activated keratocytes further independently produce L-1 α and remodel the extracellular matrix. Damaged epithelial cells also produce TGF- β 2 (transforming growth factor) into the adjacent stroma, inducing the sub-population of keratocytes to convert to myofibroblasts. Myofibroblasts are produced by components of the extracellular matrix. The help maintain a healthy corneal epithelium and corneal nerves thanks to the release of soluble trophic factors. Above all the neurotransmitter Substance P (SP) is important, acting in synergy with other growth factors (including nerve growth factor – NGF) for the purpose of accelerating healing of the corneal epithelium, migration of keratocytes into the breached area and their proliferation during the course of healing and regeneration. According

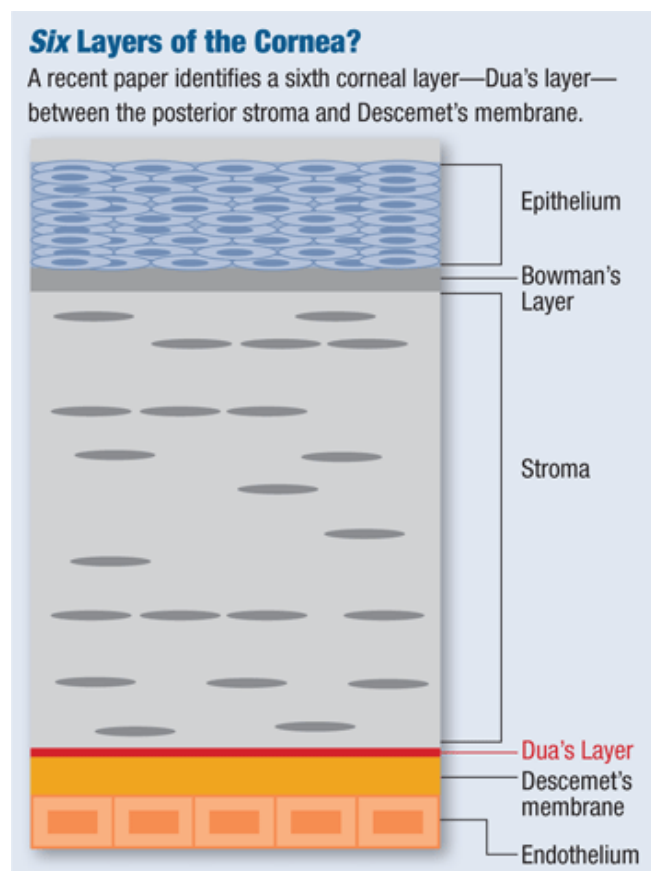


Fig. 1 Cornea - Histology
Source: www.google.com

to clinical studies it is demonstrated that the expression and secretion of SP in human keratocytes increases as a response to trauma *in vitro* (5, 8).

Corticosteroids (CS) are divided into endogenous and synthetic. Endogenous CS are steroid hormones synthesised from cholesterol, produced by the adrenal cortex, the secretion of which is controlled by adrenocorticotrophic hormone (ACTH), produced by adenohypophysis. They are divided into glucocorticoids (cortisol, corticosterone), which regulate the sugar and protein metabolism, mineralocorticoids (aldosterone), which influence the metabolism of water and minerals in the body, and above all control the maintenance of normal levels of sodium (Na) and potassium (K) in blood plasma, as well as the volume of extracellular fluid, and androgens (testosterone), which control the development and maintenance of masculine characteristics, and are precursors for oestrogens. Endogenous corticosteroids influence the majority of physiological functions of the organism, enable overcoming of stress reactions, regulate the immune system, induce natural immunosuppression, control inflammatory reaction and prevent its pathological development. Synthetic CS are generated artificially on the basis of a structural analogy, they have a wide range of therapeutic uses, and can be differentiated into four generations. According to their chemical structure, glucocorticoids are divided into fluorinated and non-fluorinated. Non-fluorinated = non-halogenated (1st generation) include cortisone, hydrocortisone acetate and prednisolone. Fluorinated = halogenated (2nd and 3rd generations) include dexamethasone, fluorometholone and betamethasone. Fluorinated CS contain a halogen molecule in their chemical structure (F-, Cl-), manifesting several times higher therapeutic effectiveness, they have an enhanced anti-inflammatory effect, high anti-proliferative effect and thereby also a higher incidence of adverse effects. The 4th generation includes hydrocortisone 17-butyrate, methylprednisolone acetate and prednicarbate. These steroids do not contain halogens, but on the basis of a certain substitution in the carbon molecules (C-17 and C-21 position) have a high anti-inflammatory activity but only a weaker anti-proliferative effect than the 2nd and 3rd generation, as a result of which they have a reduced risk of adverse effects. In practice a very broad range of pharmaceuticals from the group of corticosteroids is used, depending on the predominant mechanism of effect of the individual substances. Possible forms of application of corticosteroids include local application in the form of eye drops or ointments. Ocular pharmaceutical forms manifest a rapid, highly anti-inflammatory effect and good penetration into the anterior segment of the eye. Solutions penetrate better through the cornea than suspensions or ointments. Another option for administration is periocular application in the form of subconjunctival, sub-Tenon's or parabulbar injections. Another application form is intraocular application in the form of depot intraocular implants (Dexamethasone – Ozurdex, Fluocinolone acetonide – Iluvien, Retisert) and intravitreal injections (Triamcinolone acetonide 4 mg in 0.1 ml). A frequent form of application is systemic administration perorally (Prednisone tbl., Medrol tbl.), inhaled or parenteral (methylprednisolone – Solu-Medrol). Systemic administration may be accompanied by a whole range of adverse effects (see below), the incidence

of which increases depending on the duration, frequency and intensity of treatment. These substances must not be applied in the case of active systemic infection (2, 4, 9).

Corticosteroids have anti-inflammatory, anti-allergic, immunosuppressant and anti-edematous effects. The anti-inflammatory and immunosuppressant effect of corticosteroids is non-specific. They influence all types of inflammatory reactions, regardless of the cause, and act in the acute and chronic phase of inflammation. Corticosteroids manifest strong anti-inflammatory effects, because they directly intervene into the inflammatory and coagulation cascade (fig. 2). Inflammation is a protective reaction of the organism, the aim of which is to destroy or displace the stimulus causing the inflammatory reaction. Upon inflammation a range of chemical substances are released into circulation from the damaged tissue cells, such as histamine, bradykinin, proteolytic enzymes, prostaglandins and leukotrienes, with a range of inflammatory mediators (TNF α , IFN γ , IL-1, PAF, LTB $_4$), as well as components of complement (C3a, C5a), which initiate inflammatory reaction, pain is generated (dolor) and also increased temperature (calor). Inflammation mediators increase the through-flow of blood as a consequence of vasodilation, upon the generation of erythema (rubor), and also increase the escape of plasma into the damaged area by increasing capillary permeability upon the generation of edema (tumor). Inflammation mediators increase the expression of adhesive molecules on the surface of phagocytes and vascular endothelial cells, leading to a slowing of blood flow and the function of the tissue is damaged (functio laesa). The damaged area is then infiltrated by leukocytes, which migrate from the micro-circulation and accumulate in the place of inflammation. After a number of days the fibrous tissue grows, and the damaged tissue heals. Through the inhibition of phospholipase A2 (PL A2), corticosteroids prevent the biosynthesis of arachidonic acid, and subsequently also the formation of prostacyclin, prostaglandins and leukotrienes. They prevent the formation of anti-inflammatory transcription factors, and this effect is referred to as non-genomic trans-repressive. The anti-inflammatory effects are non-specific (independently of whether the etiology is allergic, traumatic or infectious). Corticosteroids further reduce the proliferation of fibroblasts and the amount of collagen deposition, and thereby influence the regeneration and repair of tissues. They reduce permeability of capillaries and thus have an anti-edematous effect. The anti-allergic effect is due to the reduced release of histamine from the basophils, which is induced by class IgE antibodies, dependent upon the generating stimulus. The immunosuppressive effects are also non-specific. The cytoplasmic receptor for corticosteroids (CSR) is universal for all types of cells in the organism, and as a result the same mechanism of effect applies in all application pathways. Corticosteroid penetrates across the cytoplasmic cell membrane, binds to the cytoplasmic corticosteroid receptor (CSR) and forms the complex CS-CSR. The receptor is transported directly to the core of the cell, where it acts. We refer to these effects as genomic trans-activation. In the target cells (lymphocytes) they induce controlled cell death ("apoptosis") by the direct effect of the CS-CSR complex in the core of the cell, thanks to the activation of proapoptotic genes ("lympholytic effect"). In the macro-phases they block the

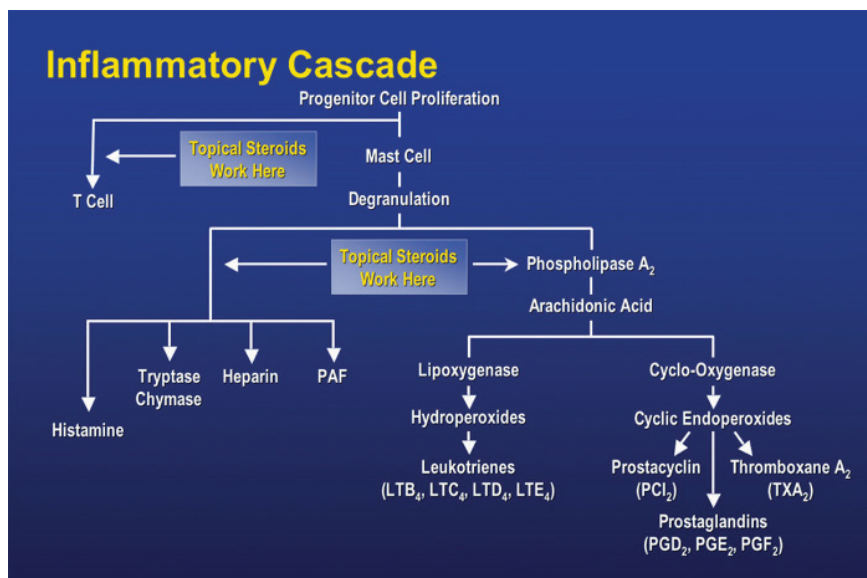
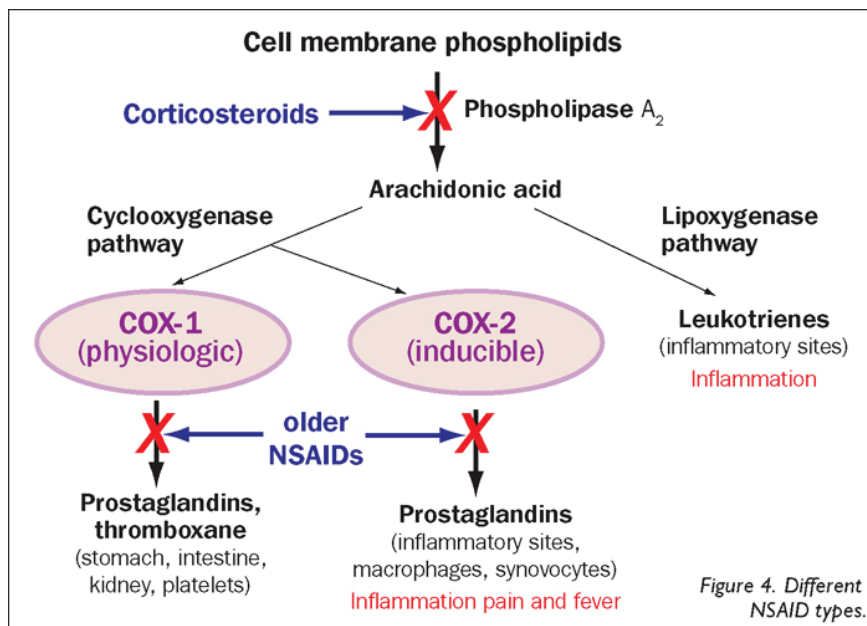


Fig. 2 The inflammatory cascade

Source: www.google.com

production of pro-inflammatory interleukines 1 and 6 (IL-1 and IL-6). They halt the migration of antigen-presenting cells and cells of phagocytosis into the place of inflammation (9, 10, 11).

The type and severity of the adverse effects of corticosteroids depends on the pharmaceutical substance, the length and frequency of its administration, the dose and pharmaceutical form in which it is adapted. Adverse effects are in connection with the metabolic and endocrine effects of corticosteroids. Even short-term application of very high doses of corticosteroids may result in serious, even life-threatening adverse effects. Systemic adverse effects include mineralocorticoid effects such as increase of blood pressure, retention of fluids and sodium, depletion of potassium, hypokalaemic acidosis, negative nitrogen balance, fatal heart chamber arrhythmia. Systemic effects also include glucocorticoid (metabolic) effects, which incorporate stimulation of gluconeogenesis, reduction of use of glucose cells, increased concentration of glucose in blood (malfunction of glucose tolerance to

manifestation of diabetes mellitus), osteoporosis, myopathy, Cushing's syndrome, centripetal obesity, hyperlipidaemia, reduction of cellular proteins (outside of liver tissue), ulcerous gastroduodenal pathology, support for the growth of skeletal muscles (anabolic effect), increased risk of infection, reactivation of latent infection to outbreak of sepsis, retarded healing of wounds, constriction to atrophy and fragility of skin, rash (flash), psychiatric disorders (trembling, depression, euphoria, hyperactivity), disorders of menstruation, inhibited growth in children, acute pancreatitis. Corticosteroids reduce the activation and migration of leukocytes, block the migration of neutrophils into the extracellular area, have a lympholytic effect, slightly increase the number of red blood cells, increase blood coagulation, the administration of large doses causes significant atrophy of all lymphoid tissue within the organism. Frequent local adverse effects include cataract (most commonly posterior subcapsular) and steroid glaucoma. Steroid glaucoma is a form of secondary open-angle glaucoma.

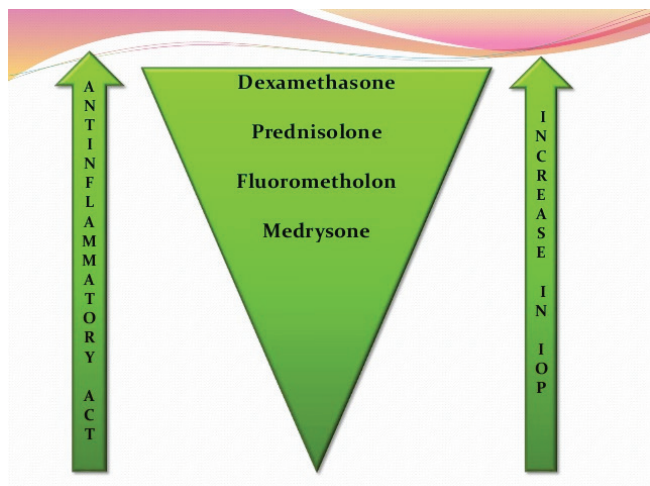


Fig. 3 Local corticosteroids – comparison of effect
Source: (9)

It is caused by an accumulation of glycosaminoglycans in the trabecular meshwork. In genetically predisposed individuals an elevation of intraocular pressure takes place upon repeated use ("steroid responder"). Here a role is played by the individual perception of the patient, the duration, strength, frequency of treatment and the properties of the used preparation (table 1, fig. 3). Secondary glaucoma almost never occurs during the period of duration of corticosteroid therapy for less than 5 days, and rarely occurs after less than 2 weeks. It is usually reversible following discontinuation of treatment, unless a medication has been used for longer than one year. Further local adverse effects include exacerbation of bacterial and viral infections, less frequently transitional ocular discomfort, atrophy of eyelids, blepharoptosis (caused by inhibition of sympathetic innervation), constriction of the sclera, deposit of calcium in the cornea, retarded healing of

Table 1 Secondary glaucoma – influence of individual local preparations on increasing intraocular pressure

Preparation	Average increase of IOP (mmHg)
Dexamethasone 0.1%	22.0 ± 2.9
Prednisolone 1.0%	10.0 ± 1.7
Dexamethasone 0.005%	8.2 ± 1.7
Fluorometholone 0.1%	6.1 ± 1.4
Hydrocortisone 0.5%	3.2 ± 1.0

Source: www.google.com

Table 2 Corticosteroids overall – overview

Preparation	Specification, effects	Application
Prednisone	<ul style="list-style-type: none"> - synthetic steroid hormone - pronounced glucocorticoid effects - low mineralocorticoid effects - suppresses effects of pharmaceuticals reducing blood coagulation, glycaemia and blood pressure - sulfonamides and HAK increase its effectiveness 	<ul style="list-style-type: none"> - p.o. (initial dose 0.5-1.5 mg/kg/day; maintenance dose 5-10 mg/day) <p>Note: 5 mg prednisone = 4 mg methylprednisolone! = 20 mg hydrocortisone!</p>
Methylprednisolone Medrol, Methylprednisolone, Solu-Medrol	<ul style="list-style-type: none"> - pronounced glucocorticoid - low mineralocorticoid effects 	<ul style="list-style-type: none"> - p.o. (aggressive dose 0.8 mg/kg/day; maintenance dose 4-8 mg/day) - i.v. (500-1000 mg/day inf.)
Hydrocortisone	<ul style="list-style-type: none"> - soluble salt of natural human hydrocortisone - balanced glucocorticoid and mineralocorticoid effects 	<ul style="list-style-type: none"> - locally - i.v. - i.m. (doses individual 200-400 mg)
Dexamethasone	<ul style="list-style-type: none"> - pronounced anti-edematous effects 	<ul style="list-style-type: none"> - local - periocular - intraocular
Betamethasone Diprophos inj. sus.	<ul style="list-style-type: none"> - pronounced glucocorticoid effects - low mineralocorticoid effects <p>= soluble sodium salt betamethasone phosphate + slightly soluble crystalline suspension of betamethasone dipropionate</p>	<ul style="list-style-type: none"> - local - i.d. - deep i.m. (never administer i.v. or s.c.!) - periocular <p>Note: for local and depot (3-4 weeks) of therapy! low doses are sufficient – reduction of side effects</p>

Source: www.aislp.cz (AISLP – automated information system of pharmaceutical preparations)

Table 3 Local corticosteroids – overview

Pharmaceutical substance	Anti-inflammatory/ anti-allergic effect	Onset of effect, absorption	Biological and chemical properties	Preparation, concentration
Hydrocortisoni acetat = non-halogenated glucocorticoid	Very weak	relatively slow - minimal absorption after application to conjunctival sac	- practically insoluble in water - difficult solubility in ethanol and dichloromethane - biological availability 96% - chemical formula C ₂₃ H ₃₂ O ₆	- white/off-white crystalline powder
Prednisolonum = non-halogenated glucocorticoid synthetic analogue of main glucocorticoid (cortisole or hydrocortisone)	weak	- rapid - after application to conjunctival sac 7-15% of dose is absorbed - penetrates well into interior of eye – same effect in inflammations of exterior i.i.o.	- prednisolone acetate 1% is not registered in CZ! - usually considered the most effective anti-inflammatory preparation for inflammations of the anterior segment and as standard according to which all other topic ocular CCS are compared – has highest effectiveness!	- available concentration: 0.5% suspension of prednisolone acetate 0.5% ointment prednisolone pivalate Dexamethasonum
Dexamethasonum = halogenated (fluorinated) glucocorticoid structurally similar to cortisole	Strong	- rapid - good penetration into chamber fluid - after application into conjunctival sac 4-15% of dose is absorbed	- available as alcohol and phosphate derivate Note: alcohol derivates are more active than phosphate - resistant to metabolic conversion following penetration into chamber fluid - maximum tendency to increase IOP of all topic corticosteroids – use for short-term intensive therapy - after long-term application risk of damage n. II., thinning of cornea or perforation of bulb	- available concentration: 0.1% suspension
Fluorometholonum = halogenated (fluori- nated) glucocorticoid structurally similar to progesterone	Strong X relatively weak effect on risk of increase of IOP - pharmaceutical of choice for patients with anamnesis of increase of IOP and glaucoma patients	- rapid - good penetration into chamber fluid - after application into conjunctival sac less than 10% of dose is absorbed	- available as alcohol and acetate derivate	available concentration: 0.1% suspension of water-free (alcohol) fluorometholone 0.1% suspension of fluorometholone acetate

Source: www.asilp.cz (AISLP – automated information system of pharmaceutical preparations)

the corneal epithelium, thinning to lysis (“melting”) of the cornea, mydriasis (increase of pupillary diameter by approximately 1 mm), in rare cases occurrence of central serous chorioretinopathy (CSCR). Corticosteroids mask typical clinical symptoms of fungal and viral infections (4, 10).

Upon long-term systemic administration of high doses of corticosteroids, a suppression of the adrenal cortex occurs due to the suppression of secretion of adrenocorticotrophic hormone (ACTH). The mechanism of negative feedback to the axis hypophthalmos – adenohipophysis – adrenal glands leads to an inhibition of its function, both upon use of a large dose

for a number of days, and for smaller doses over more than 2 weeks. Doses of glucocorticoids must therefore be reduced always smoothly and carefully, the speed of termination of therapy depends on the length of previous therapy and on the used dose. Sudden discontinuation of therapy is inadmissible, due to the danger of adrenocortical insufficiency. During treatment we must always begin with a large dose, which we then gradually reduce, in which the dose should be as low as possible in order to prevent general side effects. Upon general peroral therapy, the largest part of the daily dose must be administered in the morning, the remainder at lunchtime, with no dose in the

Table 4 Local combined corticosteroids with antibiotic – overview

KS/ATB	Derivate of KS Effect of ATB	Form	Concentration of CS
Hydrocortisone / Neomycin / Bactitracin zineum Bactericide	Ointment	0,5 %
Dexamethasone / Gentamicinum Bactericide	Ointment	0,03 %
Dexamethasone / Tobramycin	Phosphate Bactericide	Suspension Ointment	0,1 %
Dexamethasone natrii phosphas / Chloramfenicolum	Phosphate Bactericide	Solution	0,1 %
Dexamethasone / Neomycin sulfas / Polymyxin B	Acetate Bactericide	Suspension Ointment	0,1 %

Source: www.aislp.cz (AISLP – automated information system of pharmaceutical preparations)

Table 5 Corticosteroids – management of use

Topical CS	Systemic CS
Effective on pathologies of the anterior segment	Effective on pathologies of the posterior segment
Simple application	Obtížnější aplikace Relativně vysoká cena
Relatively low economic costs	More difficult application
Relatively high price	Systémové komplikace přítomné
Dosing differs according to severity of disorder	Generally one dose per day
Absence of systemic complications	Systemic complications present

Source: [9]

evening. It is necessary to retain high doses until the effect of treatment is perceptible, and then slowly discontinue therapy over a number of weeks in order to prevent reactivation or recurrence of the pathology, and in order to provide the adrenal glands with time for recuperation in order to return to their usual secretion. The usual reason for failure of treatment is due to unsuitable dosing (4, 9, 10).

General corticosteroids. In practice a very broad range of pharmaceuticals from the group of corticosteroids are used, and their use is dependent on the predominant mechanism of effect of the individual substances. An overview of general corticosteroids is presented in table 2.

Local corticosteroids. Local application of corticosteroids is effective in the case of inflammations of the anterior segment, but does not reach sufficient therapeutic levels in the case of inflammations of the vitreous body, retina or choroidea, and as a result in the case of inflammations of the posterior segment the effect is potentiated by periocular and general administration. A detailed overview of local corticosteroids is presented in table 3.

The effect of local corticosteroids combines in the magisterial of pharmaceutical preparations with an antibiotic effect, both bacteriostatic, which halts the reproduction of bacteria, and bactericide, which kills bacteria. These local combined preparations are in the form of ointments, suspensions or solutions. An overview of combined corticosteroids is presented in table 4.

Biological availability of topical corticosteroids: Biological availability is defined as the proportion of the unaltered medication which attains systemic circulation. This depends on

its capacity to penetrate the cornea. Penetration depends on the type of pharmaceutical and method of administration. Knowledge of penetration is obtained from trials on healthy tissues, and the data is available in the literature (9).

An ideal steroid in ophthalmology should have “**two-phase solubility**”:

1. soluble in lipid (hydrophobic) layers of the epithelium and endothelium.

2. Soluble in water (hydrophilic) layers of the stroma. Derivates of acetate and alcohol are more lipophilic or soluble in fats. By contrast, sodium phosphate and hydrochloride derivatives are more hydrophilic, or better soluble in water.

In an intact epithelium there is greater penetration of lipophilic molecules (derivates of acetate and alcohol). On the other hand, in a breached epithelium there is greater penetration of phosphates (hydrophilic derivatives). It ensues from this that in suppression of inflammation of the cornea, derivatives of alcohol and acetate are more effective than phosphate derivatives, both in the presence and in the absence of the corneal epithelium (9).

Upon indication of topical corticosteroids, it is important as to whether or not the corneal epithelium is intact. In the case of an intact epithelium we apply corticosteroids in the form of eye drops or ointments, in the case of a non-intact epithelium periocular application is required (parabulbar injection), with regard to its capacity for inhibition of corneal re-epithelisation.

Management of use of corticosteroids is presented in

Table 6 Corticosteroids – indications

Topical CS	Systemic CS
Corneal transplantation (fundamental significance in suppression of immunological response) Herpes zoster disciform keratitis and uveitis Marginal corneal infiltrates Superficial keratitis (punctata) Thygeson's keratitis Keratitis upon acne rosacea Keratitis within framework of systemic (RA) and autoimmune pathologies Blepharitis, contact dermatitis Interstitial keratitis (suppression of fibroplastic processes) Bullous keratopathy (anti-edematous effects, support for migration of endothelial cells upon closure of defects) Severe dry eye syndrome Phlycten, viral inflammations of the conjunctiva Pingueculitis, inflammatory irritation of the pterygium Non-infectious inflammations of the eye: allergic conjunctivitis and keratitis, vernal conjunctivitis, oversensitivity Anterior uveitis Scleritis, episcleritis Posterior uveitis (including periocular, intravitreal and general application) Cystoid macular edema (CME) Proliferative vitreoretinopathy (PVR) Conditions following intraocular surgery Postoperative inflammations Ocular traumas: chemical injuries (corrosion, burns), mechanical injuries (contusion) Neonatal haemangioma Mucocutaneous lesions of the conjunctiva	Transplantology Posterior uveitis Scleritis Neuritis, chorioretinitis Endophthalmitis (not in myotic!) Sympathetic ophthalmia Papillitis, neuritis n. II, retrobulbar neuritis Anterior ischaemic optic neuropathy (AION) Haemorrhagic glaucoma Retinal vasculitis Temporal arteritis Ocular myasthenia gravis Malignant exophthalmos due to endocrine orbitopathy Orbital pseudotumour Ocular traumas

Source: [2, 9]

table 5.

Corticosteroids represent an important benefit in the treatment of several types of ocular pathologies. A detailed overview of the indications for local and systemic corticosteroids in the treatment of ocular pathologies is presented in table 6.

Ocular contraindications (hereinafter referred to as CI) include bacterial conjunctivitis, bacterial keratitis and corneal ulcers (in the initial phase of the pathology, by contrast during the healing process corticosteroids have an essential influence), herpetic keratitis (upon use of corticosteroids there is a risk of perforation of the cornea). Relative ocular CI include glaucoma. General CI include chronic renal failure, congestive heart failure, systemic hypertension, infectious diseases, diabetes mellitus, peptic ulcer, osteoporosis and psychosis (2, 9).

DISCUSSION

Thanks to their non-specific immunosuppressant effects, corticosteroids have a significant and irreplaceable position in corneal transplantology. With regard to their non-specific anti-inflammatory effect, and therefore the suppression of complex inflammatory cascades, they occupy an important place in the therapy of chemical injuries, non-infectious and allergic inflammations, as well as a whole range of autoimmune and systemic pathologies.

Topical steroids reduce the number of inflammatory cells (leukocytes) in the infiltrated corneal stroma, and thus assist the process of re-epithelisation. If corticosteroid therapy is termi-

nated prematurely and inappropriately, the cells of the immune system proliferate, immature cells produce a large quantity of antibodies against residual antigens in the ocular tissue, and the resulting reaction of the antigen-antibody (Ag-PL) is followed by a massive polymorphonuclear leukocyte reaction. Unless this sequence of events is immediately interrupted, it may lead to recurring and seriously necrotising inflammations. As a result, topical corticosteroid therapy, depending on the response and used doses, should be gradually reduced over the course of a number of days to weeks. Corticosteroids play an important role in chemical injury to the cornea, because they inhibit the production of collagenase and thereby reduce collagen synthesis, which leads to a retarding of the development of uncontrollable and frequently very serious scarring. They prevent the formation of permanent scars. Corticosteroids retard the healing of wounds by slowing the migration of cells, and through the reconstruction of the cytoskeleton of epithelial cells (9).

Treatment with glucocorticoids improves the organisation of tight-junctions of proteins of the epithelium and increases the epithelial barrier function of the cornea. Studies have demonstrated that cells of the corneal epithelium express the functional glucocorticoid receptor (GR), which following local application of dexamethasone is substantially regulated after only 6 hours of treatment. A remodelling of the cytoskeleton takes place, with a reduction of permeability of the epithelium, increased proliferation of cells, as well as induced apoptosis in cultivated corneal epithelial cells and in any used concentration. The cells of the corneal epithelium proliferate in response to stimulation

by dexamethasone. Glucocorticoids alter the gene expression of the corneal epithelium and thereby influence healing of wounds and the barrier function of the epithelial cells (1).

In a further experiment referred to in the literature (2), it was demonstrated that during in vitro injury to the cornea, cortisone inhibits the formation of fibrous coagulations, cellular infiltration and regeneration of the endothelium. Ashton and Cool (1951) succeeded in preventing healing of the cornea by sufficiently large doses of corticosteroids. Cook and MacDonald (1951) demonstrated that cortisone reduces increased permeability of ocular capillaries in the case of inflammation, and confirmed that cortisone has no influence on the permeability of healthy capillaries. After discontinuation of treatment permeability again increases (2).

We must not forget the fact that we can use corticosteroids locally upon an intact epithelium, but that by contrast in the case of an impaired epithelium they are not suitable (an exception is severe chemical burns and traumas).

In the case of failure of therapy it is better to increase the concentration of the pharmaceutical than to increase the number of doses.

Counterproductivity

Corticosteroids inhibit the re-epithelisation of the cornea, and as a result must not be administered locally upon epithelial lesions. Also, as has been mentioned, they inhibit collagen synthesis, which upon uncontrolled and unbalanced application may cause lysis of the cornea (in perforating keratoplasty even to a "washing out" of the transplant). Corticosteroids mask the clinical symptoms of pathology due to suppressing manifestations of inflammation, and as a result it is necessary to exercise considerable caution in the use in the initial phases of inflammation unless we know the etiological agent. Corticosteroids support the invasion of saprophytic organisms. They inhibit chemotaxis and functions of phagocytes, block degranulation and reduce the production of phagocytes. They potentiate fungal pathologies and fungal ulcers. They facilitate penetration of the cornea for herpes viruses, and support

their replication. In the case of adenoviral inflammations they prolong the infectious period of the patient, while they do not reduce the duration of inflammation. We should not apply corticosteroids where we do not expect the therapeutic benefit of treatment to exceed the risks of administration.

CONCLUSION

Therapy using corticosteroids is of considerable benefit in several types of ocular pathologies, and is used in the treatment of inflammatory and immunological pathologies of the eye. Corticosteroids manifest strong anti-inflammatory effects, since they intervene directly in the inflammatory and coagulation cascade. The anti-inflammatory and immunosuppressant effect of corticosteroids is non-specific and is determined by their lymphatic action, inhibiting the formation of prostaglandins and leukotrienes, and suppressing the production of interleukin 2 and other cytokines.

The dangers of steroids are widely recognised, whether these concern adverse ocular effects in the form of cataract or steroid glaucoma, or general adverse effects of treatment. Although corticosteroids rank as one of the most frequently prescribed medicaments whatsoever across the whole of medicine, it is always necessary to exercise great caution in indicating treatment by any corticosteroid preparation, and before administration to exclude all infectious diseases, take a thorough anamnesis and examine the patient carefully. Ill-considered prescription of corticosteroids may alter the clinical picture, complicate the diagnostic-therapeutic balance and frequently prolong or complicate the treatment of the patient. In general corticosteroids should not be used where the therapeutic benefit does not significantly exceed the risk of administration. On the other hand, correctly and timely indicated corticosteroid therapy, the correct pharmaceutical form, dose, frequency, strength and type of preparation prevents the loss of visual functions, and returns the patient to normal, fully active life.

Corticosteroids play an irreplaceable role in a whole range of corneal pathologies and in transplantology.

LITERATURE

1. **Bourcier, T., Forgez, P., Borderie, V. et al.:** Regulation of Human Corneal Epithelial Cell Proliferation and Apoptosis by Dexamethasone. *Invest. Ophthalmol Vis Sci*, 2000, 41(13): 4133–4141.
2. **Dinning, W. J.:** Steroids and the eye – indications and complications. *Postgrad Med J* 1976 Oct; 52(612): 634–638.
3. **Dua, H. S., Faraj, L. A., Said, D. G. et al.:** Human corneal anatomy redefined: a novel pre-Descemet's layer (Dua's layer). *Ophthalmology*, 2013, 120(9): 1778–1785.
4. **Jirásková, N.:** Přehled léčby zánětů oka. In Rozsival, P. (Ed), *Infekce oka*, Praha: Grada Publishing a.s., 2003, s. 65–67.
5. **Kadmiel, M., Janoshazi, A., Xu, X. et al.:** Glucocorticoid action in human corneal epithelial cells establishes roles for corticosteroids in wound healing and barrier function of the eye. *Exp Eye Res*. 2016 Nov, 152:10–33. doi: 10.1016/j.exer.2016.08.020.
6. **Kanski, J.J.:** Clinical Ophthalmology: A systematic Approach / Edition 6. Edinburgh: Butterworth-Heinemann/Elsevier, 2007, p. 250
7. **Kuchynka, P. a kol.:** Oční lékařství. 2. doplněné a přepracované vydání. Praha: Grada Publishing a.s., 2016. s. 283–285.
8. **Słoniecka, M., Le Roux, S., Zhou, Q. et al.:** Substance P enhances keratocyte migration and neutrophil recruitment through interleukin-8. *Mol Pharmacol*. 2016 Feb, 89(2): 215–225. doi: 10.1124/mol.115.101014.
9. **Suraj, Ch.:** Ocular steroid. 16th batch [online]. 2015. [cit. 2016-11-7]. Dostupné na: <http://www.slideshare.net/surajkc5832/steroid-suraj>.
10. **Toušková, M., Jirásková, N.:** Imunosuprese v oftalmologii. In Rozsival, P. (Ed), *Infekce oka*, Praha: Grada Publishing a.s., 2003, s. 39–40.
11. **Vlková, E., Hlinomazová, Z.:** Riziková keratoplastika. *Sborník prací lékařské fakulty* 118. Masarykova Univerzita Brno, 1999, s. 18–20.