

# TRAUMA-RELATED ACUTE MACULAR NEURORETINOPATHY. A CASE REPORT

Hasani H., Sheikhghomi S., Ojani M.

Alborz University of Medical Sciences, Department of Ophthalmology, Madani Medical Center, School of Medicine, Karaj, Iran

*The authors of the study declare that no conflict of interest exists in the compilation, theme and subsequent publication of this professional communication, and that it is not supported by any pharmaceutical company. The study has not been submitted to another journal and is not printed elsewhere, with the exception of congress summaries and recommended procedures.*

*The authors declare that they have NO affiliations with or involvement in any organization or entity with any financial interest in the subject matter or materials discussed in this manuscript.*

Received: December 7, 2022

Accepted: January 10, 2023

Available on-line: March 30, 2023



First author:  
Hamidreza Hasani, MD

Corresponding author:  
Sima Sheikhghomi, MD  
Department of Ophthalmology,  
Faculty of Medicine  
Alborz University of Medical  
Sciences  
Karaj  
3149779453 Iran  
E-mail: sshaiikhghomi@yahoo.com

## SUMMARY

**Aims:** To introduce a case report and review the literature on trauma-related acute macular neuroretinopathy as an unusual etiology of acute macular neuroretinopathy.

**Material and Methods:** A 24-year-old man presented with unilateral paracentral scotoma following non-ocular trauma in a car accident. The relative afferent pupillary defect was negative and the best corrected visual acuities of both eyes were 10/10 (by the Snellen chart scale). Results: Retinoscopy revealed a reduced foveal reflex, along with a small pre-retinal hemorrhage over the mid-pathway of the supranasal arteriole. OCT images showed an obvious ellipsoid zone (EZ) layer disruption in the macula of the left eye. The infrared fundus photograph of the same eye revealed a distinct hyporeflexive area involving the macula. On fundus angiography, no macular vascular lesion was detected. The scotoma persisted after 3 months follow-up.

**Conclusion:** Non-ocular trauma including head or chest trauma without direct ocular injury accounts for most cases of trauma-related acute macular neuroretinopathy. It is important to distinguish this entity, given that there are also unremarkable findings in the retinal examination of these patients. Indeed, proper clinical suspicion leads to further suitable investigations and impedes other extraordinary images, which are the basic rules in the management of traumatic patients suffering multiple injuries and incurring medical expenses.

**Key words:** trauma, macula, scotoma, injury

Čes. a slov. Oftal., 79, 2023, No. 2, p. 102–106

## INTRODUCTION

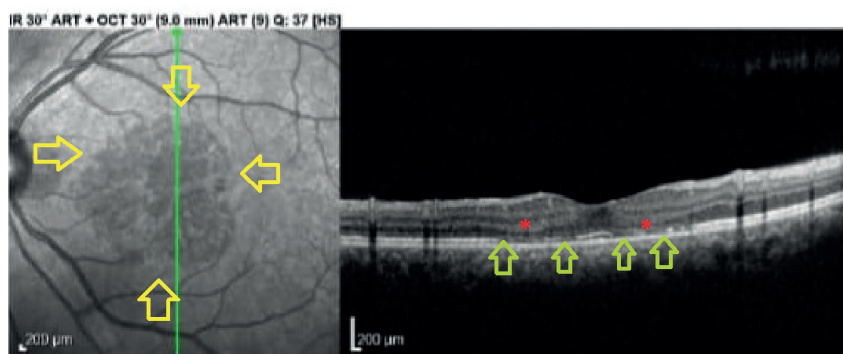
Acute macular neuroretinopathy (AMN) is defined as the acute ischemia of deep retinal layers which is limited to the macular region. The major triggers identified for this rare condition include systemic hypotension, infections, intravenous contrast, thrombotic conditions, pre-eclampsia, caffeine consumption and the use of some drugs with sympathomimetic effects, such as ephedrine, epinephrine, etc. and those with hyper-coagulation effects, such as oral contraceptive pills (OCPs) [1-4].

The main clinical presentation of these patients is sudden onset paracentral scotomas which occur most-

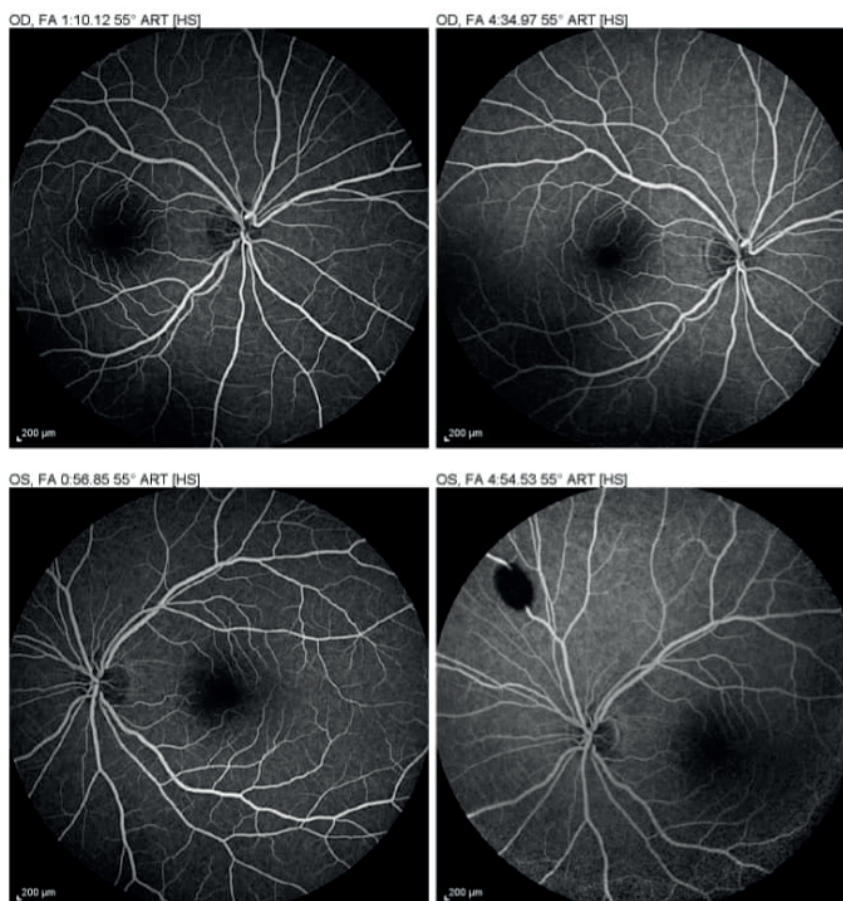
ly unilaterally. Other symptoms including reduced central vision or metamorphopsia may coexist, depending on the foveal involvement. Eye examination including funduscopic examination usually reveals no visible lesions, except for some perifoveal teardrop-shaped preretinal or intraretinal hemorrhages which may be found in some patients. The macular changes can be detected as hyporeflexive lesions in infrared or near infrared reflectance (IR or NIR, respectively) fundus photography, as well as spectral domain Optical Coherence Tomography (SD-OCT) in which outer retinal hyper-reflectivity or atrophy, depending on the duration after the onset of the disease, and ellipsoid zone disruptions are evident [3].

Despite good visual acuity in most patients, the prognosis of scotomas varies among patients and usually persists even after long-term follow-up, often with outer nuclear atrophies in their OCTs [1-4].

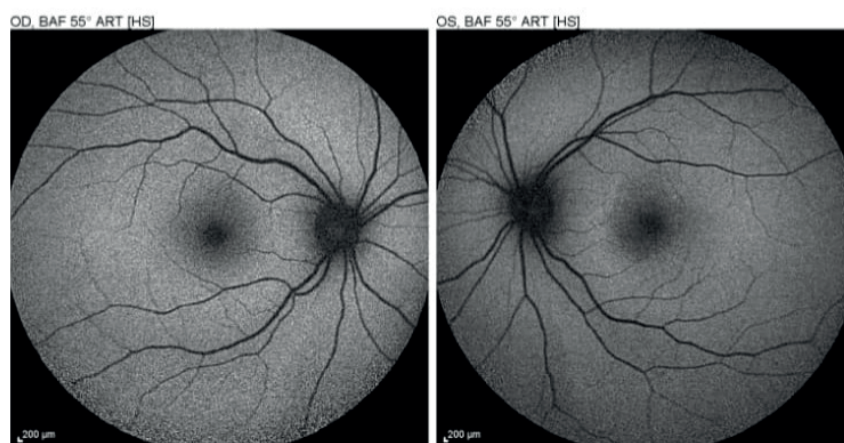
In this article, we present a rare case and a literature review of trauma-related AMN, an association which is seldom discussed in the literature, but needs to be reported as a reminder in encountering trauma patients who develop scotoma.



**Figure 1.** Right: Infrared Reflectance imaging's (IR) shows a well-defined hyporeflectant macular lesion (surrounded by yellow arrows). Left: Spectral domain Optical Coherence Tomographies (SD-OCT) showing a central outer nuclear layer atrophy (red asterisks) and multiple ellipsoid and inner segment/outer segment junction disruptions (green arrows)



**Figure 2.** Top: Fluorescein Angiography (FA) of the right eye showing no vascular lesion. Bottom: Fluorescein Angiography (FA) of the left eye showing a localized blockage of fluorescein due to pre-retinal hemorrhage over the supranasal arteriole. No vascular abnormalities are seen in the macular region



**Figure 3.** Autofluorescence (AF) of both eyes have normal appearance

### Case presentation

A 24-year-old male was transferred to our hospital following a car accident while driving. The patient was unconscious immediately after the accident, but became alert a few hours after admission. He remained in hospital due to his head, chest and limb injuries. Nevertheless, the injuries were minor and the patient was discharged without the need for surgical intervention. However, from the first day of admission, the patient complained of reduced vision in his left eye. In this regard, the patient was very agitated and claimed that he could see nothing with his left eye on the straight position and had to gaze slightly laterally to see faces well. On gross examination of his eyes, no pathologies in favor of ocular trauma were detected. The relative afferent pupillary defect was negative and the best corrected visual acuities of both eyes were 10/10 (by the Snellen chart scale).

On slit-lamp examination, the anterior segment of the left eye was normal. Retinoscopy revealed a reduced foveal reflex, along with a small pre-retinal hemorrhage over the mid-pathway of the supranasal arteriole. Other components of the posterior segments seemed intact. The examination of the right eye was totally normal.

After three weeks, no improvement in visual field impairment was reported by the patient. On OCT imaging, an obvious ellipsoid zone (EZ) layer disruption and outer retinal thinning was detected in the macula of the left eye. The IR photograph of the same eye revealed a distinct hyporeflective lesion in the same location (Figure 1). On fundus angiography, no abnormality was distinguished, apart from a localized blockage of fluorescein due to the pre-retinal hemorrhage over the supranasal arteriole (Figure 2). Autofluorescence imaging also showed unremarkable findings (Figure 3). By integrating the clinical manifestation and paraclinical findings of the patient, the diagnosis of traumatic acute macular neuroretinopathy was confirmed and the patient was observed. Unfortunately, after 3 months' follow-up, no improvement occurred.

### DISCUSSION AND CONCLUSIONS

Trauma-related acute macular neuroretinopathy is an inadequately described disease in patients with impaired vision following trauma. To date, 18 cases of trauma-associated AMN have been reported in the literature. The demographic, clinical features and prognoses of these patients are all summarized in Table 1. As shown in this Table, acute macular neuroretinopathy usually occurs following non-ocular trauma in most patients. It is assumed that the raised intrathoracic pressure in non-ocular injuries may develop an ischemic retinal vasculopathy similar to Purtscher retinopathy or Valsalva retinopathy [5-8]. In addition, our patient developed a localized oval-shaped pre-retinal hemorrhage over the supranasal arteriole – a finding similar to Valsalva retinopathy – which could support this hypothesis. Therefore, it is not unexpected to see isolated or multiple retinal hemorrhages beyond the macular region in these patients.

Regarding the diagnostic modalities, both IR and OCT images are the most informative modalities for detecting macular changes in almost all patients, particularly if done in the acute phase of the disease. Over time, the involved outer retina atrophies and the dark lesions found in the infrared imaging may fade and become less distinct. Instead, reduced amplitudes revealed in the multifocal electroretinogram (mfERG) of the involved eyes may be more durable in the long term. Generally, other modalities including fluorescein angiography (FA) or autofluorescence (AF) do not identify the lesions [4-5, 9], although OCT angiography (OCTA) may show hypoperfusion of choriocapillaries, deep or superficial capillary plexus [6].

Non-ocular trauma, including head or chest trauma without direct ocular injury, accounts for nearly all cases of trauma-related acute macular neuroretinopathy [5-11]. Therefore it seems more reasonable that the term “traumatic maculopathy”, which inclu-

**Table 1.** Summary of clinical and paraclinical features of all the reported patient with traumatic AMN in the literature

No	Age	Gender	Type of injury	Symptom	Funduscopy	OCT	IR or red-free	FA	Follow up	Author (year)
1	61	male	Non-ocular trauma	unilateral reduced vision and contralateral paracentral scotoma	intraretinal hemorrhage, CWS, ill-defined dark foveal lesion	Hyperreflective retinal thickening, EZ disruption	Dark lesion	-	Partial improvement of vision, complete improvement of scotoma	Gediz <sup>5</sup> (2019)
2	49	male	Non-ocular trauma	unilateral Paracentral scotoma	perifoveal petaloid lesion, CWS, RH	EZ disruption	-	unremarkable	Near complete improvement	Kuriakose <sup>7</sup> (2019)
3	69	male	Non-ocular trauma	unilateral Paracentral scotoma	unremarkable	EZ disruption	Dark lesion	-	Partial improvement	Kim <sup>8</sup> (2016)
4	50	male	Non-ocular trauma	unilateral reduced vision	blunted foveal reflex	Hyperreflective thickening of outer retina, intraretinal and subretinal fluid	Dark lesion	unremarkable	Persistent scotoma, improved vision	Wubben <sup>11</sup> (2016)
5	68	male	Non-ocular trauma	unilateral reduced vision / Paracentral scotoma	ill-defined macular lesion	EZ disruption	Dark lesion	unremarkable	Improved vision/ persistent scotoma	Nentwich <sup>9</sup> (2015)
6	48	female	Non-ocular trauma	unilateral reduced vision / Paracentral scotoma	parafoveal hemorrhage	EZ disruption	Dark lesion	unremarkable	Improved vision/ persistent scotoma	Nentwich <sup>9</sup> (2015)
7	21	female	Non-ocular trauma	unilateral Paracentral scotoma	unremarkable	EZ disruption	Dark lesion	unremarkable	Persistent scotoma	Nentwich <sup>9</sup> (2015)
8	45	male	Non-ocular trauma	unilateral Paracentral scotoma	unremarkable	Poor resolution	Dark lesion	unremarkable	Persistent scotoma	Nentwich <sup>9</sup> (2015)
9	30	male	Non-ocular trauma	unilateral Paracentral scotoma	unremarkable	EZ disruption	Dark lesion	unremarkable	Persistent scotoma	Nentwich <sup>9</sup> (2015)
10	23	male	Non-ocular trauma	unilateral Paracentral scotoma	subtle reddish parafoveal lesion	EZ attenuation ONL thinning	-	-	Missed follow-up	Chinskey <sup>10</sup> (2014)
11	51	female	Non-ocular trauma	unilateral Paracentral scotoma	unremarkable	Hyperreflective outer retina/ EZ disruption	Initial translucent lesion / later dark lesion	unremarkable	Partial improvement of scotoma	Chinskey <sup>10</sup> (2014)
12	49	male	Non-ocular trauma	unilateral Paracentral scotoma	subtle translucent paracentral lesion	Hyperreflective outer retina/ EZ disruption	Initial translucent lesion / later dark lesion	unremarkable	Persistent scotoma	Chinskey <sup>10</sup> (2014)
13	49	male	Non-ocular trauma	unilateral Paracentral scotoma	reddish parafoveal lesion	Outer retina atrophy/ EZ disruption	-	unremarkable	Persistent scotoma	Chinskey <sup>10</sup> (2014)
14	23	female	Non-ocular trauma	unilateral reduced vision / Paracentral scotoma	subtle translucent paracentral lesion	Hyperreflective outer retina/ EZ disruption	Dark lesion	unremarkable	Improved vision/ persistent scotoma	Chinskey <sup>10</sup> (2014)



15	45	male	Non-ocular trauma	unilateral Paracentral scotoma	unremarkable	-	Dark lesion	unremarkable	Near complete improvement	Gillies <sup>5</sup> (1997)
16	17	male	Non-ocular trauma	unilateral Paracentral scotoma	unremarkable	-	Dark lesion	unremarkable	Partial improvement	Gillies <sup>5</sup> (1997)
17	33	male	Non-ocular trauma	unilateral Paracentral scotoma	macular edema & hemorrhage	-	Dark lesion	unremarkable	Partial improvement	Gillies <sup>5</sup> (1997)
18	53	male	Non-ocular trauma	bilateral Paracentral scotoma	unremarkable	-	Dark lesion	unremarkable	Partial improvement	Gillies <sup>5</sup> (1997)

*EZ – ellipsoid disruption, FA – fluorescein angiography, IR – infrared reflectance, OCT – optical coherence tomography*

des a wide range of macular changes including macular hole, choroidal rupture, etc., be used for direct ocular injuries.

It is important to distinguish trauma-related AMN, given that there are also unremarkable findings in the retinal examination of these patients. Indeed, proper clinical suspicion leads to further suitable investigations and

impedes other extraordinary images, which are the basic rules for the management of trauma patients suffering multiple injuries and incurring medical expenses. Moreover, the legal issues created by motor vehicle accidents may put the physician in a diagnostic dilemma, where it is not easy to differentiate from malingering due to the normal retinal examination.

## REFERENCES

1. Turbeville SD, Cowan LD, Gass JD. Acute macular neuroretinopathy: a review of the literature. *Surv Ophthalmol*. 2003 Jan;48(1):1-1. [https://doi.org/10.1016/S0039-6257\(02\)00398-3](https://doi.org/10.1016/S0039-6257(02)00398-3)
2. Bhavsar KV, Lin S, Rahimy E, et al. Acute macular neuroretinopathy: a comprehensive review of the literature. *Surv Ophthalmol*. 2016 Sep;61(5):538-565. <https://doi.org/10.1016/j.survophthal.2016.03.003>
3. Rodman JA, Shechtman DL, Haines K. Acute macular neuroretinopathy: the evolution of the disease through the use of newer diagnostic modalities. *Clin Exp Optom*. 2014 Sep;97(5):463-467. <https://doi.org/10.1111/cxo.12161>
4. Fawzi AA, Pappuru RR, Sarraf D, et al. Acute macular neuroretinopathy: long-term insights revealed by multimodal imaging. *Retina*. 2012 Sep;32(8):1500-1513. <https://doi.org/10.1097/IAE.0b013e318263d0c3>
5. Gillies M, Sarks J, Dunlop C, Mitchell P. Traumatic retinopathy resembling acute macular neuroretinopathy. *Aust N Z J Ophthalmol*. 1997 May;25:207-210. <https://doi.org/10.1111/j.1442-9071.1997.tb01393.x>
6. Gediz BŞ. Acute Macular Neuroretinopathy in Purtscher Retinopathy. *Turk J Ophthalmol*. 2020 Apr;50(2):123.
7. Kuriakose RK, Chin EK, Almeida DR. An atypical presentation of acute macular neuroretinopathy after non-ocular trauma. *Case Rep Ophthalmol*. 2019;10(1):1-4. <https://doi.org/10.1159/000496144>
8. Kim SE, Lee SE, Kim YY. A Case of Acute Macular Neuroretinopathy after Non-ocular Trauma. *J Korean Ophthalmol Soc*. 2016 Dec;57(12):1970-1975. <https://doi.org/10.3341/jkos.2016.57.12.1970>
9. Nentwich MM, Leys A, Cramer A, Ulbig MW. Traumatic retinopathy presenting as acute macular neuroretinopathy. *Br J Ophthalmol*. 2013 Oct;7(10):1268-1272. <http://dx.doi.org/10.1136/bjophthalmol-2013-303354>
10. Chinskey ND, Johnson MW. Acute Macular Neuroretinopathy Following Trauma. *Invest Ophthalmol Vis Sci*. 2014 Apr;55(13):5940.
11. Wubben TJ, Dedania VS, Besirli CG. Acute macular neuroretinopathy with transient intraretinal and subretinal fluid following non-ocular trauma. *JAMA Ophthalmol*. 2016 Dec;134(12):1443-1445. <http://doi:10.1001/jamaophthalmol.2016.4109>