

ACUTE RETINAL NECROSIS AFTER DEXAMETHASONE INTRAVITREAL IMPLANTATION. A CASE REPORT

Šulavíková Z.¹, Anwarzai J.¹, Krásnik V.²

¹Department of Ophthalmology, Faculty Hospital Trenčín, Slovakia

²Department of Ophthalmology, Comenius University and University Hospital, Bratislava, Slovakia

The authors of the publication declare that the formation and the topic of the scientific output and its publication are not in conflict of interest and are not supported by any pharmaceutical company. They further declare that the paper has not been submitted to any other journal, nor has it been published, except as a congress abstract.

Received: 20 October 2021

Accepted: 20 February 2022

Available on-line: 19 May 2022



MUDr. Zuzana Šulavíková

Očná klinika

Fakultná nemocnica Trenčín

Legionárska 28

911 71 Trenčín

E-mail: zuzana.sulavik@gmail.com

SUMMARY

ACUTE RETINAL NECROSIS AFTER INTRAVITREAL DEXAMETHASONE IMPLANT. A CASE REPORT

Introduction: Ozurdex® (Allergan Pharmaceuticals, Castlebar Road, Westport, Ireland) is an intravitreal implant containing 0.7 mg dexamethasone. It is indicated in adult patients for the treatment of diabetic macular edema, cystoid macular edema due to central retinal vein occlusion, and in patients with non-infectious uveitis. Common complications after Ozurdex® administration include an increase in intraocular pressure, cataract progression or conjunctival suffusion. Acute retinal necrosis after Ozurdex® administration is a very rare and serious complication. According to our current research, this is the fourth published case. Extreme caution must be exercised when treating immunosuppressed patients with Ozurdex®.

Case Report: This is a case report on an immunosuppressed 68-year-old patient with diabetic macular edema, who developed acute retinal necrosis 74 days after Ozurdex® implantation. He suffers from chronic myeloid leukemia and takes 400 mg cytostatic imatinib once per day. Urgent pars plana vitrectomy (PPV) with silicone oil instillation was performed and antiherpetic drugs were initiated intravenously. Serological examination confirmed an active infection of cytomegalovirus etiology (CMV).

Conclusion: Acute retinal necrosis is a rare necrotizing retinitis. Corticosteroids administered intravitreally reduce the local immune response, which may cause a primary infection or reactivation of a latent viral infection.

Key words: diabetic macular edema, chronic myeloid leukemia, dexamethasone, acute retinal necrosis, imatinib, immunosuppression

Čes. a slov. Oftal., 78, 2022, No. 3, p. 144–148

INTRODUCTION

Ozurdex® is a single-use intravitreal implant containing 0.7 mg dexamethasone in a dispenser made of solid polymer. It is a biodegradable, sustained-release drug and is effective for approximately 2–6 months [1,2]. The implant is approximately 6 mm long and 0.46 mm wide. Ozurdex® is indicated in adult patients for the treatment of diabetic macular edema (DME), cystoid macular edema developed due to central retinal vein occlusion (RVO), and in patients suffering from non-infectious uveitis. Due to the absence of clinical trials for bilateral administration, concomitant administration in both eyes is not recommended [2]. Kapoor et al. tried injecting 24 patients with the Ozurdex® implant bilaterally, on the same day. There were no ocular or general complications following bilateral administration [3].

This medicinal product is suitable for patients at high cardiovascular risk or for patients who experienced an inadequate response to anti-growth factor (anti-VEGF) therapy. Common complications after Ozurdex® administration include an increase in intraocular pressure, cataract progression or conjunctival suffusion. Rare complications associated with the application include migration of the implant into the anterior chamber, implant entrapment in the sclera, retinal detachment, central serous chorioretinopathy, reactivation of toxoplasmosis, endophthalmitis, and acute retinal necrosis (ARN). Corticosteroids administered intravitreally reduce the local immune response [1–5].

In this article, we present the case of an immunosuppressed patient with diabetic macular edema, who developed an acute retinal necrosis 74 days after Ozurdex® administration.

CASE REPORT

The 68-year-old patient had been followed up at our Department since 2006 for non-proliferative diabetic retinopathy. He was diagnosed with DME in both eyes in May 2020. He is being treated for type 2 diabetes mellitus, arterial hypertension, hyperlipidemia, and gastric ulcer disease. In February 2021, he overcame a moderate course of COVID-19 without the need for oxygen therapy. He lost weight and felt unwell after this illness and was admitted to the Oncology and Hematology Clinic in Bratislava in April 2021 because of suspected leukemia. On April 19, 2021, he was diagnosed with BCR/ABL-positive chronic myeloid leukemia (CML). Consequently, the treatment with imatinib, an oral cytostatic drug, was started, at a dose of 400 mg once daily. The patient did not inform us about this fact.

The patient is a non-responder to anti-VEGF therapy. The patient received 6 applications of bevacizumab, 1 application of triamcinolone and 5 applications of aflibercept in both eyes. The patient underwent a single session of macular grid laser photocoagulation and several sessions of peripheral laser photocoagulation. Despite this treatment, chronic DME persisted with a long-lasting decline in visual acuity. With a best-corrected visual acuity (BCVA) corresponding to a score of 63 and 60 ETDRS letters for the patient's right eye and left eye, respectively, and with a central retinal thickness (CRT) of 543 and 521 μm , respectively, derived from Optical Coherence Tomography (OCT) scans, we opted for Ozurdex® treatment in both eyes. The patient has phakic eyes and was scheduled for cataract surgery.

Ozurdex® was administered into his right eye at the end of July 2021. On the day of implantation, he was able to read 65 ETDRS letters and the OCT derived macular thickness was 523 μm . The patient was taking ofloxacin 5 times daily for 2 days before and 5 days after the injection. One month later, Ozurdex® was also administered into his left eye (62 ETDRS letters, 505 μm). The patient came for a scheduled follow-up visit one month after the administration into his left eye. He was satisfied with his ocular and general health. At the follow-up visit, he was able to read 66 and 65 ETDRS letters, CRT was 327/335 μm , and intraocular pressure was 20 mmHg bilaterally. There was a reduction in macular edema; and other ocular findings were unchanged bilaterally, compared to the findings before Ozurdex® administration. There was no evidence of inflammation, and in addition, the patient underwent bilateral treatment with peripheral focal laser photocoagulation. Approximately 3 and a half months (74 days, to be precise) after administration into the right eye, the patient came for a consultation due to a 10-day-long painless decrease of visual acuity in the right eye. He described slightly blurred vision and was able to read 60 ETDRS letters. Imaging of the anterior segment showed the presence of granulomatous uveitis (Figure 1). In the vitreous cavity, imaging revealed flares caused by inflammatory cells, as well as formed opacities. On the ocular

fundus, we could see the blurred optic nerve, occlusive retinal vasculitis, and in the periphery in the temporal quadrant, a yellow-white relatively sharply circumscribed necrotic lesion (Figure 2). An OCT scan showed a discrete macular edema, as well as clumps of hyperdense material on the surface of the retina and posterior hyaloid membrane (Figure 3).

An ultrasound scan showed dense echogenities of li-near and fluffy appearance in the vitreous, without the presence of echoes caused by retinal detachment (Figure 4). The patient was admitted acutely for panuveitis and, on the same day, we performed a pars plana vitrectomy (PPV) with cataract surgery and silicone oil instillation into the vitreous cavity. During surgery, we found a patch of acute retinal necrosis in the temporal quadrant, as well as occluded vessels. However, we did not find the dexamethasone implant. Vitreous humor

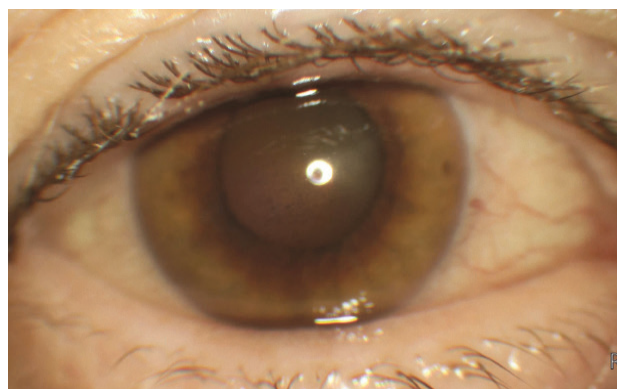


Figure 1. Anterior segment photography with granulomatous anterior uveitis without red reflex

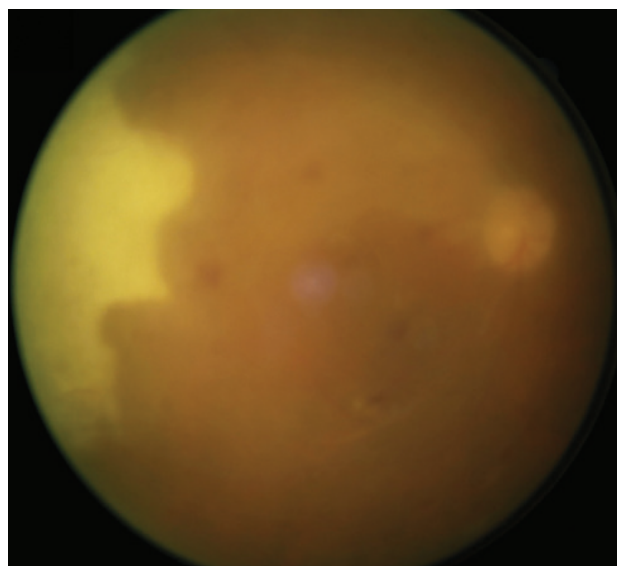


Figure 2. Fundus photography of right eye with vitreous inflammation, occlusive vasculitis and retinal necrosis

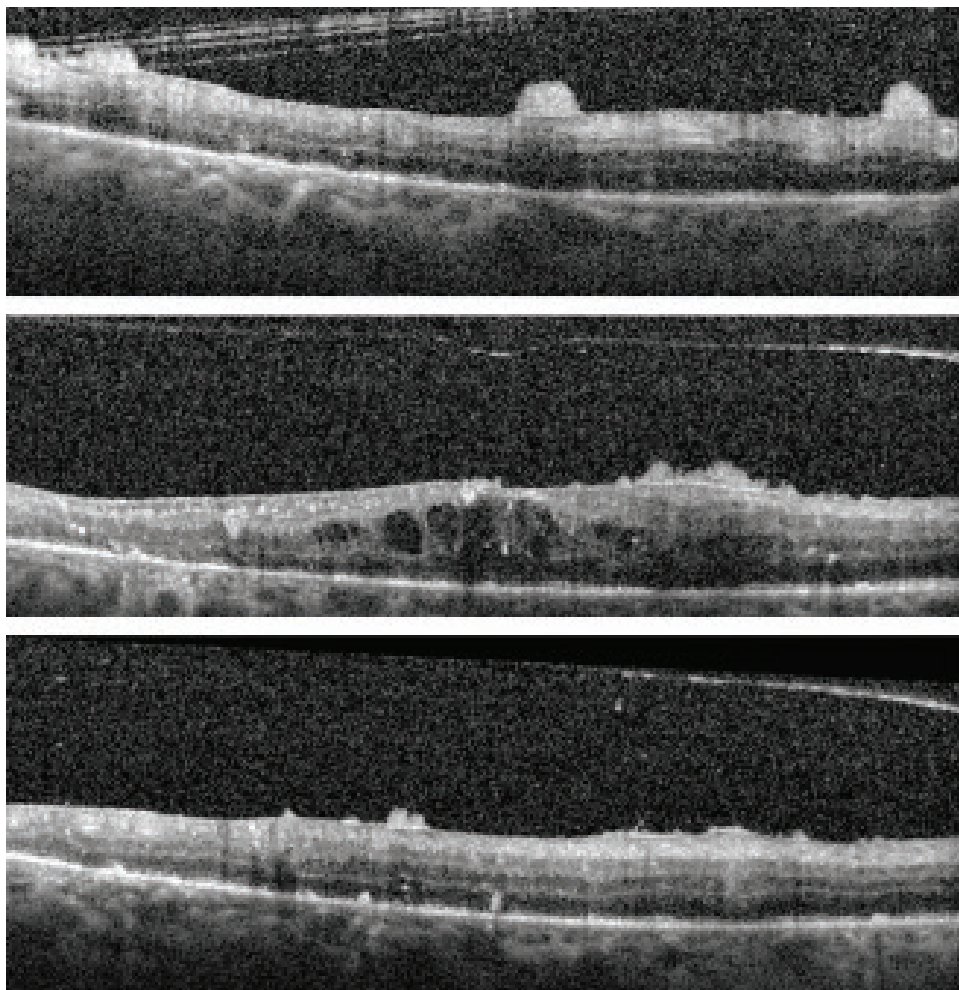


Figure 3. Macular horizontal OCT scans of right eye with macular edema and hyperdense material on retinal surface

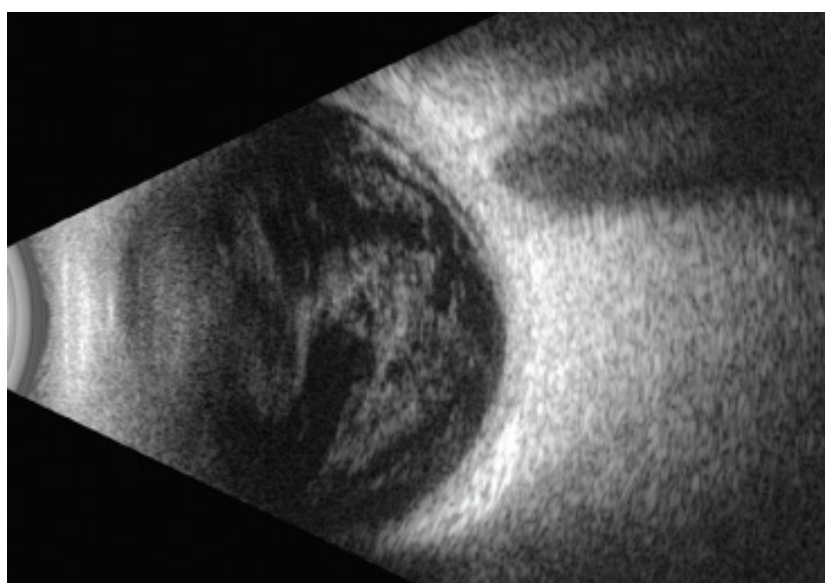


Figure 4. USG B-scan with hyperechogenicities in corpus vitreum

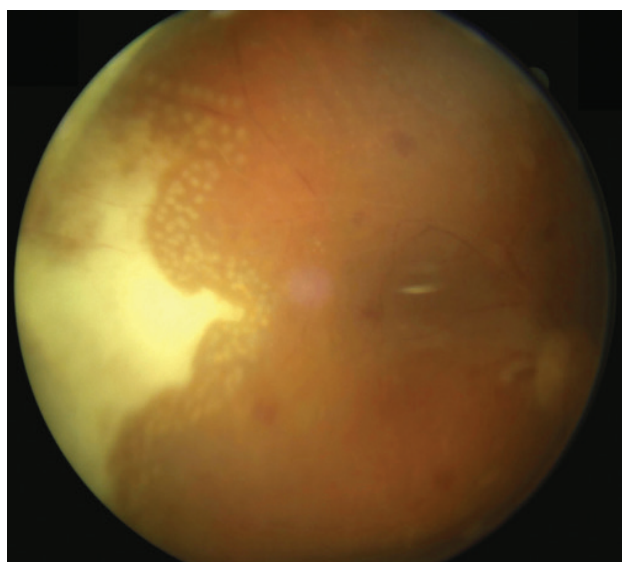


Figure 5. Fundus photography of right eye one month after pars plana vitrectomy

samples were collected for microbiological examination, and aqueous humor samples for herpes simplex viruses' detection through the polymerase chain reaction (PCR) technique. The patient started treatment, consisting of a double combination of antibiotics, antifungals and anti-herpetics administered intravenously. The level of C-reactive protein (CRP) was 1.12 mg/l and the white blood cell (WBC) count was at the lower limit of normal. Serological examination confirmed an active cytomegalovirus (CMV) infection. The culture of vitreous humor samples was negative. The examination of aqueous humor samples could not be evaluated due to technical reasons. A careful review of the patient's medical records revealed the findings of a hematological examination, leading to the diagnosis of CML treated with an oral cytostatic drug – imatinib 400 mg.

Based on the patient's medical history, clinical findings, laboratory test results, and comparison with the literature, we concluded that the patient's condition was an acute retinal necrosis due to insertion of a dexamethasone implant in a CML patient. The patient is currently one-month post-op and the BCVA in the right eye is 40 ETDRS letters. There has been a reduction in inflammatory activity and an improvement in visual functions. The edges of retinal necrosis were treated with laser and the patient continues with acyclovir 400 mg 5 times daily (Figure 5). The Ozurdex® implant is still present in the left eye, with a reduction in DME. The vitreous and retina of the left eye do not show signs of inflammation.

DISCUSSION

Common complications following the administration of a sustained-release corticosteroid implant include an increase in intraocular pressure, cataract progression or conjunctival suffusion. Such complications are transient

and easily manageable [2,7]. Rarely, more serious complications can occur and, in general, they are related to the administration or action of the medicinal product. Such complications include, among others, retinal trauma after a previous PPV due to the absence of vitreous [6]. Another complication can be the migration of the implant into the anterior chamber in aphakic eyes or, in the case of a broken posterior lens capsule or a large iridectomy [1,7]. A bacterial endophthalmitis is characterized by eye pain with decreased vision; these symptoms usually occur 2–10 days after administration [5].

Acute retinal necrosis after Ozurdex® injection is a very rare complication. According to our current research, this is the fourth published case. The first case is a 52-year-old female patient with rheumatoid arthritis, who was taking azathioprine 150 mg/day and was treated with Ozurdex® for posterior uveitis. One month after administration, the patient developed ARN and examinations detected the presence of varicella zoster virus (VZV) in the vitreous and anterior chamber [8].

The second published case concerns a 60-year-old patient with DME, after kidney transplantation for chronic kidney failure, treated with a combination of azathioprine 150 mg/day and tacrolimus 6 mg/day. Two months after cataract surgery with Ozurdex® administration, the patient developed ARN with the presence of CMV [9].

The last case is a 45-year-old immunocompetent female patient with a history of herpes simplex encephalitis (HSE). The patient had 2 implants administered over a 6-month period for macular edema developed due to RVO. Three months after the second implant was injected, she developed ARN with etiology attributed to a herpes simplex virus (HSV) [10].

Acute retinal necrosis (ARN) is a rare necrotizing retinitis. Clinically, ARN is manifested by circumscribed necrotizing patches in the peripheral retina, spreading from the periphery to the center. Other symptoms include occlusive vasculopathy, strong inflammatory response in the vitreous and anterior chamber. ARN can be caused by VZV, HSV-1 and/or HSV-2, CMV, and Epstein-Barr virus (EBV). The early and targeted treatment is important for successful acute management of the infection. In later stages, laser retinopexy can be used to reduce the risk of retinal tears and retinal detachment. Once ARN is overcome, the visual acuity usually remains impaired, with a poor visual outcome. Serious ocular complications (such as retinal detachment, epiretinal membrane formation, macular damage, or ischemic retinal vasculitis) are common. Approximately 60% of post-ARN patients have a BCVA worse than 0.1; and only 20.8% have visual acuity above 0.5. The outcome depends on how many quadrants are affected and on the early administration of targeted treatment [11].

In contrast, we found an article describing 2 post-ARN patients who developed a cystoid macular edema. These patients were injected with Ozurdex® and their macular edema was fully resolved, without recurrence of viral retinitis [12].

Cases of acute retinal necrosis have been described in patients after administration of a triamcinolone intravitreal or intracameral implant. Viral retinitis due to a triamcinolone treatment occurs in 0.41 % of patients. The incidence is higher in immunosuppressed patients, patients suffering from diabetes, and patients with a history of viral retinitis. Viral retinitis symptoms commonly begin with a slow onset, from 1 to 4 months after administration [13-15].

CONCLUSION

The efficacy and safety of Ozurdex® have been proven both in clinical trials and real-world studies. In the MEAD registration trial evaluating the safety and efficacy of Ozur-

dex® in the treatment of DME, no signs of inflammation or infectious retinitis were reported [2]. In our Department, this medicinal product is used to treat macular edema developed due to RVO and non-infectious uveitis. Ozurdex® was given on an exempt basis for the treatment of patients with DME until July 2019, but is now fully reimbursed. Despite this unpleasant experience, we continue to use Ozurdex® due to its excellent morphological and functional outcomes. Our article presents a case report of a CML patient treated with imatinib (a cytostatic drug), who developed ARN despite normal WBC counts. We consider his condition to be the reactivation of a latent infection due to local and systemic immunosuppression. Increased caution and frequent monitoring are required in all immunocompromised patients injected with Ozurdex®.

REFERENCES

1. Zafar A, Aslanides I, Selimis V et al. Uneventful Anterior Migration of Intravitreal Ozurdex implant in a patient with iris-sutured intraocular lens and descemet stripping automated endothelial keratoplasty. *Case Rep Ophthalmol*. 2018;9:143-148.
2. Summary of Product Characteristics of Ozurdex® [Internet]. Date of revision: 19.6.2018. [cited 2021 Dec 1]. Available from: https://www.ema.europa.eu/en/documents/product-information/ozurdex-epar-product-information_sk.pdf
3. Kapoor K, Colchao J. Safety of consecutive same-day bilateral intravitreal dexamethasone implant (Ozurdex). *Retin Cases Brief Rep*. 2020;14:200-202.
4. Olson D, Parhiz A, Wirthlin R. Reactivation of Latent Toxoplasmosis Following Dexamethasone Implant Injection. *Ophthalmic Surg Lasers Imaging Retina*. 2016;47:1050-1052.
5. Goel N. Acute bacterial endophthalmitis following intravitreal dexamethasone implant: A case report and review of literature. *Saudi Journal of Ophthalmology*. 2017;31:51-54.
6. Lee S, Jung JW, Park SW, Lee JE, Byon IS. Retinal injury following intravitreal injection of a dexamethasone implant in a vitrectomized eye. *Int J Ophthalmol*. 2017;10:1019-1020.
7. Celik N, Khoramnia R, Auffarth G, Sel S, Mayer S. Complications of dexamethasone implants: risk factors, prevention and clinical management. *Int J Ophthalmol*. 2020;13:1613-1620.
8. Kucukcilioglu M, Eren M, Yolcu U, Sobaci G. Acute retinal necrosis following intravitreal dexamethasone (Ozurdex) implant. *Arq Bras Oftalmol*. 2015;78:118-119.
9. Dogra M, Rohilla V, Dogra M, Singh R. Macular cytomegalovirus retinitis following dexamethasone intravitreal implant combined with phacoemulsification. *Indian J Ophthalmol*. 2018;66:1361-1363.
10. Zhang Z, Liu X, Jiang T. Acute retinal necrosis following dexamethasone intravitreal implant (Ozurdex®) administration in an immunocompetent adult with a history of HSV encephalitis: a case report. *BMC Ophthalmology*. 2020;20:1-7.
11. Hillenkamp J, Nolle B, Bruns C, Rautenberg P, Fickenscher H, Roeder J. Acute retinal necrosis: clinical features, early vitrectomy, and outcomes. *Ophthalmology*. 2009;116:1971-1975.
12. Majumder P, Biswas J, Ambreen A et al. Intravitreal dexamethasone implant for the treatment of cystoid macular oedema associated with acute retinal necrosis. *J Ophthalm Inflamm*. 2016;6:1-4.
13. Chang S, Weissgold D, Singer J, Sobrin L. Acute retinal necrosis following intraocular Triamcinolone acetonide injection. *Retin Cases Brief Rep*. 2010;4:306-308.
14. Han J, Ahn J, Park KH, Woo SJ. Presumed necrotizing viral retinitis after intravitreal triamcinole injection: case report. *Korean J Ophthalmol*. 2011;25:451-454.
15. Shah AM, Oster SF, Freeman WR. Viral retinitis after intravitreal triamcinolone injection in patients with predisposing medical comorbidities. *Am J Ophthalmol*. 2010;149:433-440.