Evaluation of the Effects of Intravitreal Application of an Ozurdex Implant in Patients with Macular Edema due to Retinal Vein Occlusion

Lada Martin, Ženíšková Renata, Hradcová Zuzana, Schützová Jana, Tesař Jan, Grygar Jan, Havlík Jan, Šín Martin

Department of Ophthalmology 1st Faculty of Medicine of Charles University and Military University Hospital Prague, Czech Republic

Submitted to the editorial board: July 4, 2025
Accepted for publication: December 5, 2025
Available on-line: February 18, 2026

The authors of the study declare that no conflict of interests exists in the compilation, subject and subsequent publication of this professional communication, and that it is not supported by any pharmaceuticals company. The study has not been submitted to any other journal or printed elsewhere.

MUDr. Martin Lada

Correspondence address:
Oční klinika 1. LF a ÚVN, Praha
U vojenské nemocnice 1200
169 00 Praha 6, Czech Republic
E-mail: lada.martin@uvn.cz

SUMMARY

Aims: A retrospective evaluation of the outcomes and safety of the Ozurdex implant in patients with cystoid macular edema (CME) due to retinal vein occlusion (RVO).

Material and Methods: A retrospective analysis of 14 eyes (10 male patients, 4 female patients) treated with the Ozurdex implant at the application center of the Department of Ophthalmology at the Military University Hospital, with the indication of RVO.

The period of monitored applications was from 2022 to 2024. Patients were followed up every two months for at least one year after the first application. The primary efficacy parameters assessed were: Best-corrected visual acuity (BCVA), Central retinal thickness (CRT), Intraocular pressure (IOP), Changes in the diameter of intraretinal cysts (IR), as the main OCT biomarker.

Results: At the first follow-up, two months after Ozurdex application, there was a statistically significant functional improvement, with an average increase of 4.7 letters ETDRS letters ($p = 0.042$). Six months after application, the average BCVA reached 58 letters ETDRS letters. CRT decreased by an average of 100 µm two months after the initial DEX implant. The highest and statistically significant increase in IOP ($p = 0.008$) was recorded two months after the application (with an average value of 20.9 mmHg).

Conclusion: Our results indicate that Ozurdex is a safe and effective second-line treatment for macular edema (ME) due to RVO. In our group, the best functional and anatomical results were achieved two months after application. By the fourth month, a decline in BCVA and an increase in CRT were observed. Between the fifth and sixth month, retreatment was necessary in some patients. Additionally, we confirmed that the greatest rise in IOP occurred two months post-application, which resolved spontaneously by the sixth month.

In four patients, IOP values above 30 mmHg were recorded during follow-up, and the intraocular pressure was managed with medication.

Key words: Ozurdex, dexamethasone (DEX), macular edema (ME), retinal vein occlusion (RVO), central retinal vein occlusion (CRVO), branch retinal vein occlusion (BRVO)

Čes. a slov. Oftal., 82, 2026, No. 5, p. 263–270

INTRODUCTION

Retinal vein occlusion (RVO) is the second most common cause of deterioration of sight in connection with vascular issues in developed countries, after diabetic retinopathy. This pathology typically occurs in people aged over 50 years, with an equal incidence in both sexes.

From 11 clinical trials it ensues that the prevalence of RVO is 5.2 cases per 1000 people. In 4.42 cases this concerned branch retinal vein occlusion (BRVO) and in 0.8 cases central retinal vein occlusion (CRVO) [1]. The main causes of occurrence are associated with cardiovascular diseases such as arterial hypertension, hyperlipidemia and diabetes mellitus [2]. Of the rarer risk factors it is necessary to mention myeloproliferative disorders (lymphoma, leukemia), the incidence of which is 1% in patients with RVO [3]. It is necessary to examine younger patients for hyperhomocysteinemia, and to focus on blood coagulation parameters in order to exclude thrombophilic conditions [3].

Very frequent complications of RVO include the occurrence of cystoid macular edema (CME). A key role in the pathophysiology of origin of CME in RVO is played by excess production of VEGF factor [4]. As the first-line treatment we use anti-VEGF preparations [5] which are currently approved for use by the FDA and EMA: Ranibizumab, Aflibercept and Faricimab [4]. In the case of nonresponse and transition of edema to chronicity, the second-line method of treatment is depot Dexamethasone, which we use due to its capacity to influence the level of VEGF in the vitreous cavity and suppress inflammatory reactions [4].

The Ozurdex (AbbVie)® implant is a biodegradable corticosteroid (CS), which contains 700 micrograms of depot Dexamethasone (DEX). DEX was approved by the American FDA in June 2009 for the treatment of CME upon a background of BRVO. This approval took place on the basis of the results of the third GENEVA study (Global Evaluation of implantable Dexamethasone in retinal Vein occlusion with macular edema) [6]. One of the main properties of CSs is controlling inflammatory reaction, to which a significant role is attributed in vitreoretinal pathologies, covering wet form age-related macular degeneration (AMD), CRVO, BRVO, diabetic macular edema (DME) as the main complication of diabetic retinopathy, and CME upon a background of posterior uveitis [7], which is the main manifestation of retinal and uveal inflammation. This edema of the tissues is manifested predominantly intracellularly, primarily affecting the Müller cells and retinal neurons [7]. Although extracellular edema is evident upon angiographic examination, histological processing of samples of eyes from donors under electron microscope has demonstrated a predominance of edema located intracellularly [7]. The main substances of inflammation which directly influence the occurrence of edema are above all prostaglandins, leukotrienes and cytokines. The dominant element in the pathogenesis is VEGF--A. One of the main aspects of inflammatory reaction is an organized process referred to as leukostasis. Stasis of leukocytes is an organized process in which retardation and adherence of leukocytes to the vascular wall takes place before they are discharged from the vascular lumen into the tissue. The entire mechanism is influenced by two fundamental types of molecules, selectins and integrins. CSs in different steps block the above-mentioned process and bring about downregulation of integrin and selectin [7].

Another process that takes place upon inflammation is the intracellular signaling process, in which arachidonic acid is a precursor for the synthesis of eicosanoids. These are substances which produce a strong effect in the body, including prostaglandins, leukotrienes, and prostacyclins [8]. CSs may enter a cell and are capable of inhibiting phospholipase 2, thereby blocking the intracellular signaling process, leading to the formation of inflammatory mediators [7]. Another significant element leading to edematization is the presence of aquaporin-4 antibodies in the Müller cells of the retina.

If inflammation and swelling occurs, the level of aquaporin-4 rises, thereby increasing the number of cellular channels by which fluids flow through the cellular wall. CSs reduce the expression of this protein of the water channel. The fact that corticosteroids act on several paths of origin of inflammation is also illustrated by the fact that they influence the structural integrity of cellular tight junctions [7].

The surgical procedures applied in the treatment of RVO include pars plana vitrectomy, i.e. surgical removal of the vitreous, which increases the proportion of oxygenated blood in the venous channel [9].

MATERIAL AND METHODS

Design of study and characteristics of cohort

A retrospective analysis was conducted on the effect of treatment with an intravitreal Ozurdex implant in patients with RVO who had undergone treatment at the Department of Ophthalmology at the Military University Hospital from January 2022, the observation of whom continued for a period of one year at minimum until December 2024.

If nonresponse to the preparation in question or transition to chronicity was determined during treatment with anti-VEGF, the preparation was switched to the drug of second choice, namely Ozurdex.

The criteria for inclusion in the retrospective observation were as follows: minimum of one application of DEX, regular follow-up examinations every 2 months and length of observation of at least one year. The exclusion criteria were length of observation of less than one year, inadequate interval of follow-up examinations failing to comply with the frequency of 2 months, presence of macular edema upon a background of an ocular pathology other than AMD, DME, uveitis and presence of choroidal neovascular membrane. If a patient had not undergone treatment with another intravitreal preparation before the first application of DEX, the patient was defined as treatment-naive.

A total of 14 patients were included in the observation (10 men, 4 women) aged 44 to 88 years. The basic characteristics of the cohort are summarized in Table 1. In the cohort patients with BRVO (8 patients) predominate over CRVO (6 patients).

Intravitreal application of DEX took place under aseptic conditions, according to the current standards of healthcare at our center. Before application all the patients were examined by a doctor, their current condition of health was evaluated and they were indicated for intravitreal application of DEX. Every patient signed an informed consent form on the day of application. The study protocol was in accordance with the Helsinki principles.

Method

A general and ocular medical history of the patients was recorded before the actual commencement of treatment. The interval of follow-up examinations was set at every 2 months for a period of at least one year from the first application of DEX. Seven patients from the cohort were excluded before the analysis was conducted due to failure to abide by the frequency of follow-up examinations, or an observation period shorter than one year. At the follow-up examinations all patients were examined for BCVA with the aid of ETDRS charts, and CRT and IOP values were measured. OCT (Spectralis Domain, Heidelberg Engineering, Germany) was routinely performed on all patients.

Analysis of OCT scans

The analysis of the scans was conducted by a single ophthalmologist. The main observation parameter in the cohort was CRT measured in units of µm with the aid of automatic analysis software. Of the other observation parameters we measured patients for the presence and evaluation of intraretinal cysts and changes thereof 2

Tabule 1. File specifications

	patient	percent
total number	14	100%
men	10	71.4%
woman	4	28.6%
IOL	9	64%
phakic lens	5	36%
naive patient	4	28.6%
Stp. Anti-VEGF therapy	10	71.4%
CRVO	6	42.8%
BRVO	8	57.2%
Stp. Micropulse laser therapy	5	35.7%
Stp. PRP	8	64.3%
elevation IOP	5	35.7%

IOL – intra ocular lens, VEGF -vascular endothelial factor, CRVO – central retinal vein occlusion, BRVO – branch retinal vein occlusion, PRFK – panretinal photocoagulation

months after the first application of DEX. The measurement was conducted manually by caliper software of the OCT instrument within the region of the fovea, in which the criterion was a minimum diameter of the cyst of > 250 µm upon the first application. The subsequent assessment of reduction or disappearance of the cyst was conducted 2 months after the first application of DEX.

Statistical analysis

The normality of distribution was tested with a Shapiro-Wilk test, and two data files were compared with paired t-tests. The analysis of subgroups was conducted post hoc. The data are assessed as mean ± standard deviation, a difference of $p < 0.05$ was considered statistically significant.

RESULTS

On the day of application of DEX, the mean value of BCVA was 54.3 letters of the ETDRS optotype. It is evident from Graph 1 that a statistically significant improvement of BCVA occurred during the first 2 months after application of DEX, by an average of 4.7 EDTRS letters ($p = 0.042$). At six months after application the mean value was 58 ETDRS letters. These results are in accordance with the GENEVA study, in which the greatest response was recorded on the 60th day of the open phase of the study [10].

The average time of repetition of DEX application in our cohort was after 4–6 months, which is also in accordance with the results of the GENEVA study, when repetition took place on average 5–7 months after the initial application [10]. Graph 2, which presents the changes of CRT during the one-year observation period with 2 monthly follow-up examinations, shows that at the first follow-up a reduction of CRT was recorded by an average of 100 µm ($p = 0.090$). At the subsequent follow-ups 4 months after the initial application we see a gradual repeat increase of CRT to a mean value of 366 µm, which is an average growth by 54.9 µm over 2 months. This confirms the results of the GENEVA study, in

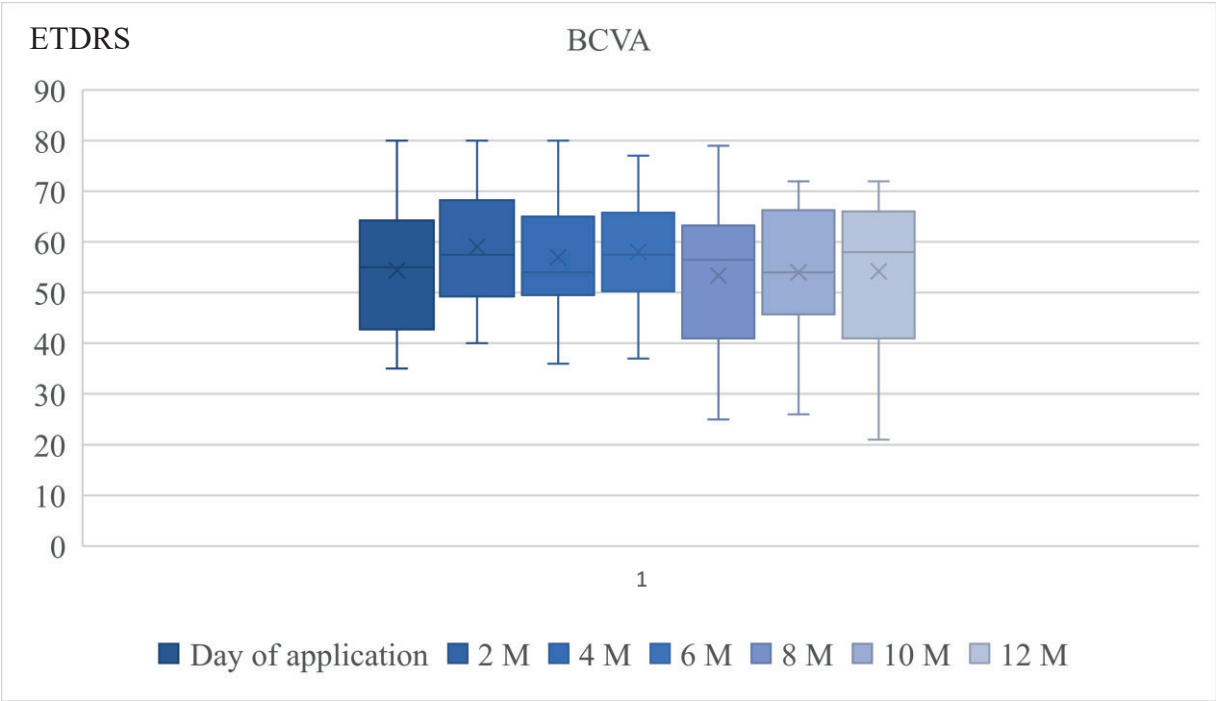

Graph 1. Best corrected visual acuity in observation period

BCVA – Best corrected visual acuity, ETDRS – early treatment diabetic retinopathy study, M – month

which re-edematization began to take place 4 months after the initial application [10]. A statistically significant anatomical change in the observed parameter of CRT took place 12 months after the initial application, in which change of CRT against the original mean value (411.7 µm) constituted a decrease by 111 µm to 300.8 µm (p = 0.013).

The highest and at the same time statistically significant (p = 0.009) increase of IOP took place 2 months after application (mean value 20.9 mmHg), as is illustrated in Table 3. Upon a comparison of the IOP values on the day of application and 4 months after application, elevation of IOP persisted on the borderline of statistical significance (p = 0.05). Six months after application a gradual stabilization and decrease of values took place, as is illustrated in Graph 3, and the same values are also documented in Table 3. We demonstrated that the highest elevation of IOP took place 30 days after application. Table 2 summarizes the mean values of BCVA in the one-year observation period with follow-up examinations every 2 months, Table 4 summarizes the mean changes of IOP values in the one-year observation period with follow-up examinations every 2 months.

OCT assessment of intraretinal cysts

At present OCT biomarkers play an essential role in the diagnosis, choice of suitable preparation and evaluation of therapeutic potential. The significance of predicting the effect of treatment with a suitable preparation is dealt with in a study conducted by Munk et al. The

Tabule 2. Best – corrected visual acuity in the monitored period at checks every two months

	Day of application	2M	4M	6M	8M	10M	12M
average BCVA (ETDRS)	54	59	57	58	53.3	54	54.2

M – month, BCVA – best corrected visual acuity, ETDRS – early treatment diabetic retinopathy study

Tabule 3. Central retinal vein thickness in the monitored period at checks every two months

	Day of application	2M	4M	6M	8M	10M	12M
average CRT (µm)	411.7	312.2	366.9	359.7	327.2	334	300.9

M – month, CRT – central retinal thickness

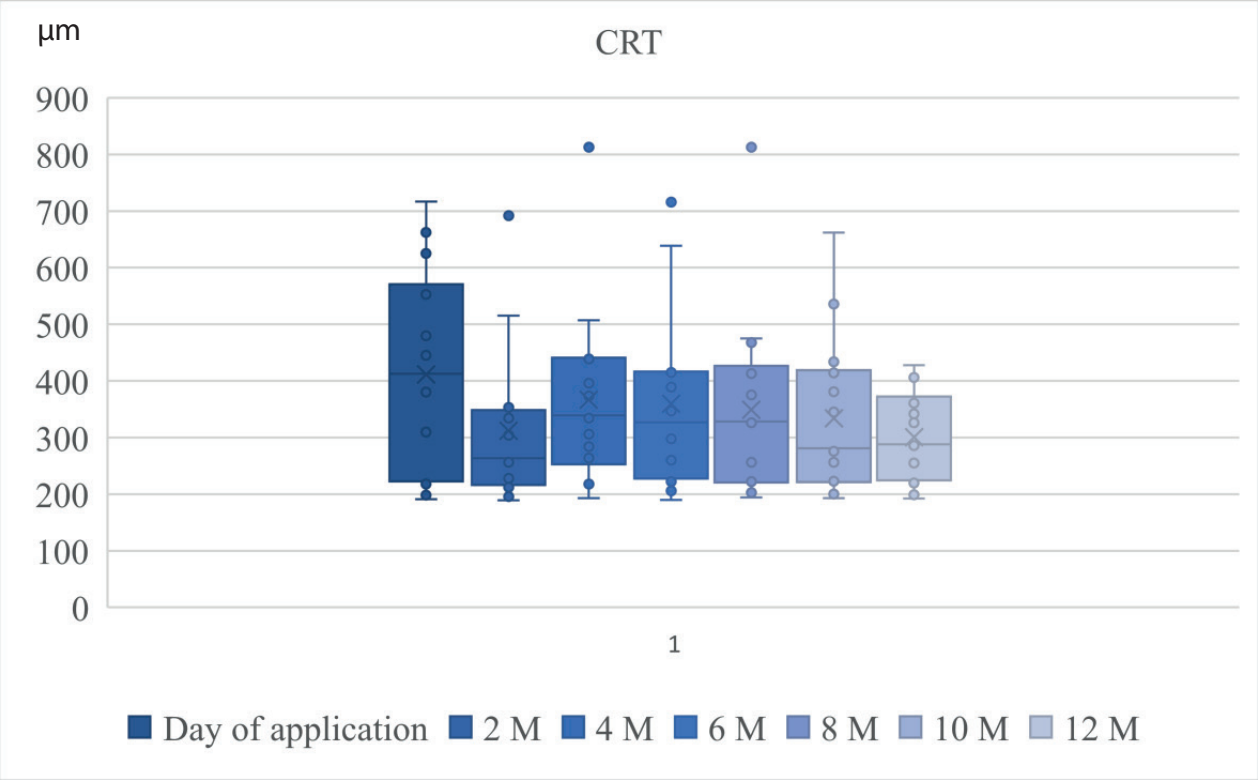

Graph 2. Central retinal thickness in observation period
CRT – central retinal thickness, M – month

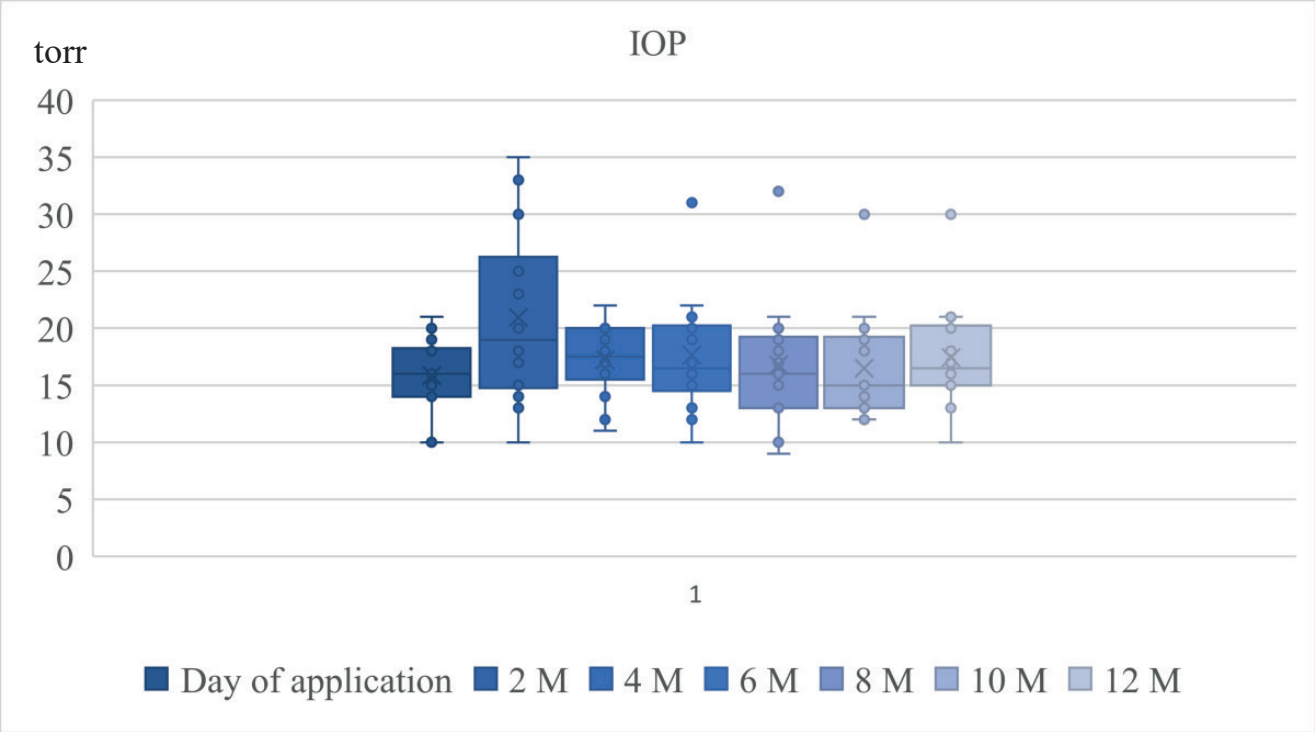

Graph 3. Intraocular pressure in observation period
IOP – intraocular pressure, M – month

Table 4. Intraocular pressure in the monitored period at checks every two months

	Day of application	2M	4M	6M	8M	10M	12M
average IOP (torr)	15.9	20.9	17.2	17.6	16.8	16.5	17.4

M – month, IOP – intraocular pressure

authors of the study state that morphological changes of OCT biomarkers in the introduction to treatment may demonstrate patient response and aid in the further therapeutic decision making and choice of preparation [16].

The evaluated biomarkers include presence of intraretinal cysts, hyperreflective foci, disorganization of the outer ellipsoid zone, DRIL – disorganization of the retinal inner layers, presence of subretinal fluid, and state of vitreoretinal environment (vitreomacular traction, vitreomacular traction syndrome etc.). In the assessment of the cohort, presence of IR cysts, their size and changes of diameter of cysts or their disappearance after the first application were selected as further evaluated parameters. At baseline IR cysts were present in 14 eyes (100%). Disappearance or reduction of the diameter of the cysts took place 2 months after the initial application in 100% of cases. Figures 1–5 document morphological changes in the region of cystoid macular edema during treatment with the Ozurdex intravitreal implant in a patient with CME upon a background of RVO. After the first application of the implant, complete disappearance of intraretinal cysts is evident at a follow-up OCT examination after 2 months (Fig. 2). At the follow-up examination 4 months after the first application re-edematization was observed, with repeat formation of small intraretinal cysts (Fig. 3). Seven months after the initial application there was a more pronounced increase of intraretinal cysts and the need to repeat the application (Fig. 4). The effect of the second application is documented by Fig. 5. The incisions were made on one level of the raster scan in the place of the highest edema, with incidence of large subfoveal IR cysts.

Safety analysis

An elevation of IOP was recorded in 5 patients (35.7%) following application of DEX. In all cases normalization of IOP was achieved through the application of local antiglaucoma therapy, without the need for surgical intervention. No further complications were recorded.

DISCUSSION

The presented results confirm that application of DEX represents a safe and effective method of treating CME in patients with RVO. At the first follow-up examination two months after the initial application a statistically significant improvement of BCVA was recorded, accompanied by a significant regression of IR cysts and a decrease of CRT. These findings are in accordance with the previously published studies evaluating the effectiveness of DEX [11].

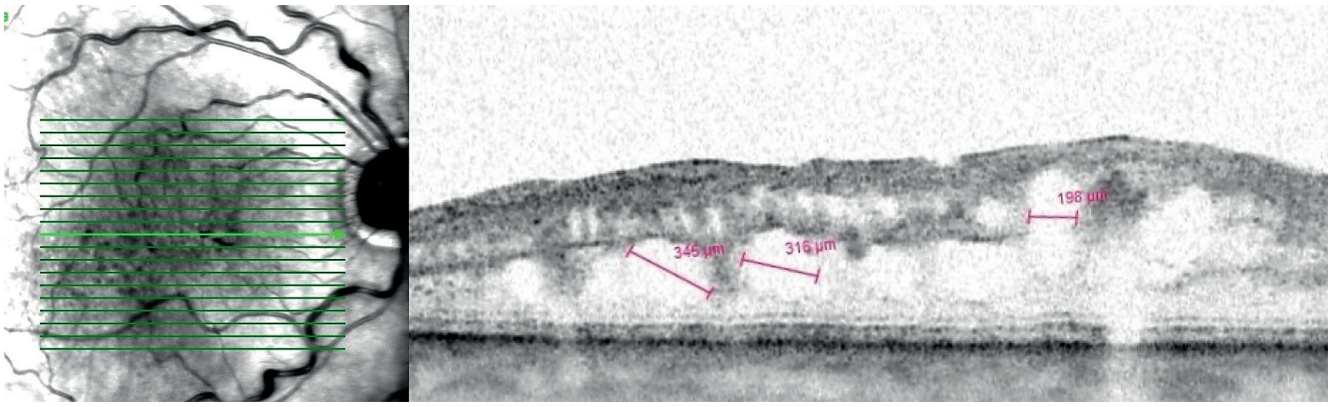

Figure 1. Chronic cystoid macular edema secondary to CRVO (Heidelberg Spectralis OCT). Fibrotic proliferation on the retinal surface, disorganization of the inner retinal layers, presence of intraretinal cysts and macrocysts exceeding 300 µm in diameter, with disruption of the continuity of the ellipsoid zone

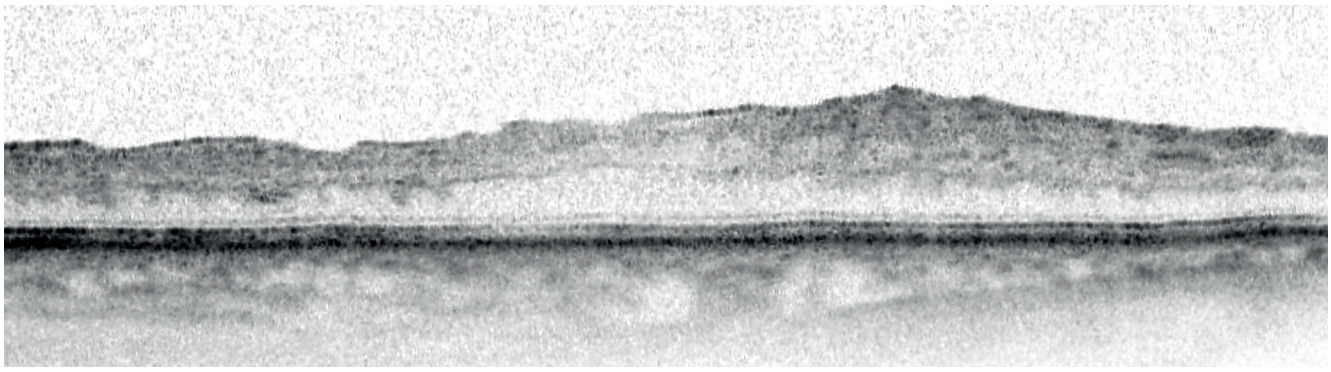

Figure 2. Resolution of cystoid spaces and reduction of macular edema two months after Ozurdex® implantation

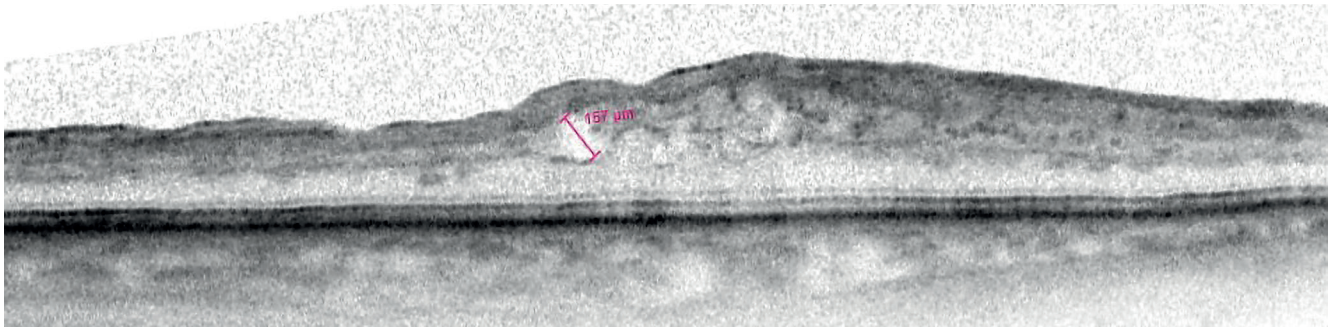

Figure 3. Recurrent disease activity with reappearance of intraretinal cysts and renewed fluid

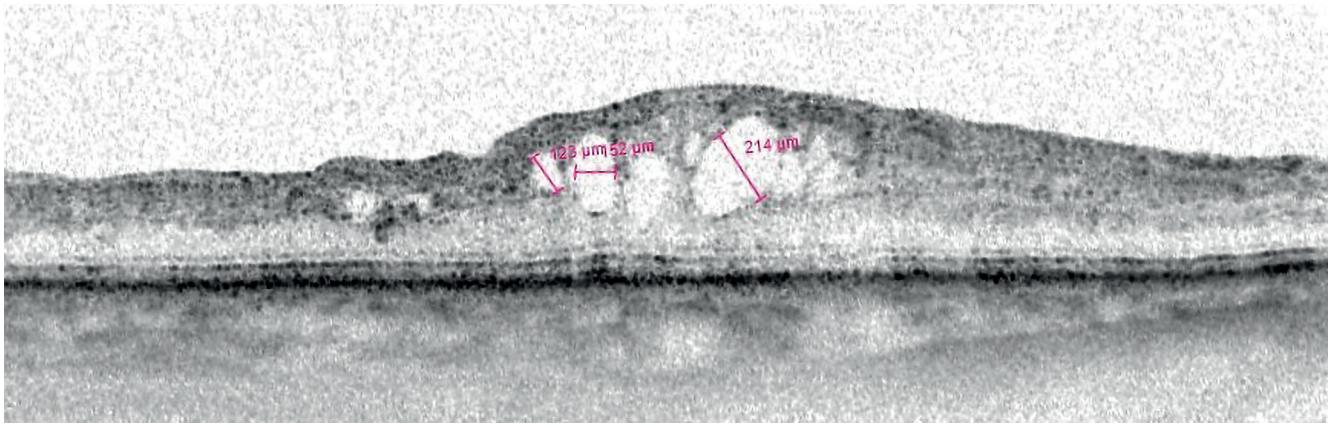

Figure 4. Cystoid macular edema at seven-month follow-up after Ozurdex® implantation, showing an increase in intraretinal cysts

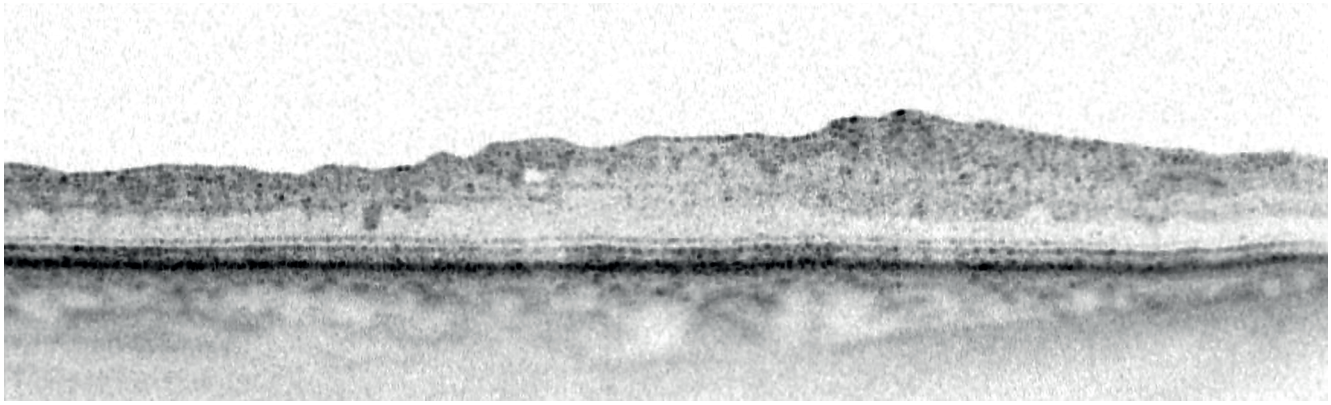

Figure 5. Complete resolution of intraretinal edema and reduction of hyperreflective foci two months after the second Ozurdex®

The highest functional response was observed two months after the initial application, when an increase of BCVA by an average of 4.7 ETDRS letters was recorded ($p = 0.042$). In the sixth month after application the mean BCVA value was 58.1 ETDRS letters, which represents an average improvement by 3.6 letters as against the baseline values. From this it ensues that a functional and anatomical improvement takes place between the 2nd and 6th month after application, which is in accordance with the conclusions of other authors [12]. Liang et al. state that the most pronounced functional improvement takes place on average within 64 days of application of DEX.

By contrast, at the follow-up examinations after 8, 10 and 12 months the functional results were no longer statistically significant, and the mean BCVA values remained stable (see Table 2). Anatomically a repeat growth of CRT was observed after 4 months, which is confirmed by the mean values presented in Table 3. The highest CRT value was recorded at 4 months after application, which corresponds with the conclusions of Garweg et al., who in their study refer to the need to repeat the application of DEX approximately 4–5 months after treatment.

According to the conclusions of the large multicentric retrospective clinical trial Shasta, the appropriate interval for repeating application is between 5 and 6 months (Garweg et al.). It is essential to abide by the finding of OCT and CVA. This is confirmed by our cohort (14 eyes), when in the one-year observation period the beginning of edematization was evident at 4 months after the initial application, with the need for repeat application between 5 and 6 months. The highest pharmacokinetic effect can be expected 2 months after application, which is also evident from Graph 2, where we see a pronounced decrease of CRT (by more than 100 µm).

At present OCT biomarkers represent a key tool for the evaluation of anatomical response to treatment. An ever increasing number of studies are focusing on predicting the therapeutic effect on the basis of OCT biomarkers, both in RVO and in DME treated with the Ozurdex intravitreal implant.

Mudroch et al. demonstrated a correlation between the presence of OCT markers and the functional and morphological response to DEX therapy in patients with DME. The authors demonstrated disorganization of the ellipsoid zone to be a negative prognostic biomarker, and at the same time confirmed the capacity of DEX to reduce disorganization of the retinal inner layers (DRIL) [13].

In our assessment of the anatomical response to DEX therapy we focused on anatomical changes of IR cysts as one of the assessable OCT biomarkers. Two months after application complete disappearance of IR cysts was recorded in 42% of patients, while in 58% of patients an average reduction by more than 100 µm was recorded. These results confirm the substantial anatomical effect of depot form of DEX, in accordance with the literature dealing the effect on various vascular pathologies of the retina [11].

After each application it is essential to monitor IOP. Our data confirm that the most significant elevation was recorded within 2 months of application Graph 3. These conclusions are in accordance with the study conducted by Garweg et al., in which an increase of IOP was monitored 1–2 months after application.

An elevation of intraocular pressure (IOP) was recorded in 28% of patients during the course of the observation period, and in all cases this was managed by means of conservative therapy with the aid of local antiglaucoma drugs. These results correspond with the data presented in the study by Garweg et al., where medicamentous control of IOP was essential in 27% of patients [14]. The results also confirm the conclusions of the GENEVA study, in which a transitional increase of IOP by more than 10 mmHg as against the baseline values was recorded in 28% of patients [10]. In our cohort the highest incidence of elevation of IOP of ≥ 30 mmHg was recorded 60 days after application (in 21% of patients), with spontaneous regression by 180 days without the need for surgical intervention.

CONCLUSION

Our results confirm that intravitreal application of DEX represents an effective and safe therapeutic option in the treatment of macular edema upon a background of RVO in the conditions of real clinical practice. At the first follow-up examination conducted two months after application, a statistically significant increase of BCVA by an average

of 4.7 ETDRS letters was recorded (p = 0.042), as well as a decrease of CRT by 100 µm. Nevertheless, at the same time we are aware that our cohort of 14 eyes is statistically burdened by its small size. The most pronounced anatomical and functional response was observed in the 2nd month, which is in accordance with the conclusions of extensive clinical trials. At the same time, an increase of retinal edematization was recorded during the follow-up examinations at 4 and 6 months after the first application.

It ensues from international studies that DEX is the drug of second choice, and that it is appropriate to consider its application after 3–6 injections of anti-VEGF in the case that no effect of treatment up to this point is demonstrated [6,14,15]. If we administer treatment to a patient who has recently suffered a serious cardiovascular event or is not capable of regular attendance for application in the first 6 months of treatment, we may consider DEX to be the drug of first choice.

At present the drug of first choice for ME upon a background of RVO is anti-VEGF therapy. At the same time, in a certain percentage of patients the response to this treatment is inadequate, and it is for these patients that application of DEX has considerable potential, in which it is possible to prevent the onset of chronic IR edema by means of a blockade of inflammatory mediators, inhibition of leukostasis and limiting the accumulation of fibrin [4,7].

REFERENCES

1. Studnička J, Němčanský J, Vysloužilová D, Ernest J, Veith M, Němec P. Retinal Vein Occlusion Guidelines, Cesk Slov Oftalmol. 2024;80(6):298-305.
2. Schreiberova Z, Rehak J, Babkova B, et al. Hypertension, hyperlipidaemia and thrombophilia as the most common risk factors for retinal vein occlusion in patients under 50 years. Biomed Pap Med Fac Univ Palacky Olomouc Czech Repub. 2024 Mar;168(1):44-49. Epub 2022 Aug 29. doi: 10.5507/bp.2022.036
3. Studnička J, Němčanský J, Stěpanov A. Sítnice: komplexní přehled od anatomie k chirirgické léčbě. Praha: Grada Publishing, 2023. ISBN 978-80-271-3586-8
4. Eissa M, Kalogeropoulos D, Evans W, Arora R, Lotery AJ. Efficacy of Ozurdex implants as second-line therapy for non-responders to anti-VEGF in retinal vein occlusion-associated macular edema: a retrospective cohort study. Ir J Med Sci. 2025 Apr;194(2):745-750. Epub 2025 Jan 24. doi: 10.1007/s11845-025-03881-z
5. Zou W, Du Y, Ji X, et al. Comparison of the efficiency of anti-VEGF drugs intravitreal injections treatment with or without retinal laser photocoagulation for macular edema secondary to retinal vein occlusion: A systematic review and meta-analysis. Front Pharmacol. 2022 Jul 22;13:948852. doi: 10.3389/fphar.2022.948852
6. Hattenbach LO, Feltgen N, Bertelmann T, et al. COMRADE-B Study Group. Head-to-head comparison of ranibizumab PRN versus single-dose dexamethasone for branch retinal vein occlusion (COMRADE-B). Acta Ophthalmol. 2018 Feb;96(1):e10-e18. doi: 10.1111/aos.13381
7. Whitcup SM, Cidlowski JA, Csaky KG, Ambati J. Pharmacology of Corticosteroids for Diabetic Macular Edema. Invest Ophthalmol Vis Sci. 2018 Jan 1;59(1):1-12. doi: 10.1167/iovs.17-22259
8. Giles AJ, Hutchinson MND, Sonnemann HM, et al. Dexamethasone-induced immunosuppression: mechanisms and implications for immunotherapy. J Immunother Cancer. 2018 Jun 11;6(1):51. doi: 10.1186/s40425-018-0371-5
9. Šín M, Šínová I, Chrapek O, et al. The effect of pars plan vitrectomy on oxygen saturation in retinal vessels – a pilot study. Acta Ophthalmol. 2014 Jun;92(4):328-331. Epub 2013 Jul 15. doi: 10.1111/aos.12238
10. Haller JA, Bandello F, Belfort R Jr, et al. OZURDEX GENEVA Study Group. Randomized, sham-controlled trial of dexamethasone intravitreal implant in patients with macular edema due to retinal vein occlusion. Ophthalmology. 2010 Jun;117(6):1134-1146.e3. Epub 2010 Apr 24. doi: 10.1016/j.ophtha.2010.03.032
11. Gale R, Gill C, Pikoula M, et al. Multicentre study of 4626 patients assesses the effectiveness, safety and burden of two categories of treatments for central retinal vein occlusion: intravitreal anti-vascular endothelial growth factor injections and intravitreal Ozurdex injections. Br J Ophthalmol. 2021 Nov;105(11):1571-1576. Epub 2020 Sep 22. doi: 10.1136/bjophthalmol-2020-317306
12. Liang X, Shen B, Ou Z, An H, Li L. Comparison of intravitreal ranibizumab monotherapy vs. ranibizumab combined with dexamethasone implant for macular edema secondary to retinal vein occlusion. Front Med (Lausanne). 2022 Sep 12;9:930508. doi: 10.3389/fmed.2022.930508
13. Mudroch T, Hrevuš M, Karhanová M, Řehák J, Marešová K. Intravitreal Dexamethasone Implant in the Treatment of Diabetic Macular Edema Focusing on the Role of OCT Biomarkers. Cesk Slov Oftalmol. 2025;81(1):16-23. doi: 10.31348/2024/29
14. Garweg JG, Zandi S. Retinal vein occlusion and the use of a dexamethasone intravitreal implant (Ozurdex®) in its treatment. Graefes Arch Clin Exp Ophthalmol. 2016 Jul;254(7):1257-1265. Epub 2016 May 13. doi: 10.1007/s00417-016- 3350-x
15. Hoerauf H, Feltgen N, Weiss C, et al. COMRADE-C Study Group. Clinical Efficacy and Safety of Ranibizumab Versus Dexamethasone for Central Retinal Vein Occlusion (COMRADE C): A European Label Study. Am J Ophthalmol. 2016 Sep;169:258-267. Epub 2016 May 7. doi: 10.1016/j.ajo.2016.04.020
16. Munk MR, Somfai GM, de Smet MD, et al. The Role of Intravitreal Corticosteroids in the Treatment of DME: Predictive OCT Biomarkers. Int J Mol Sci. 2022 Jul 8;23(14):7585. doi: 10.3390/ijms23147585