ORIGINAL ARTICLE

Transnasal Endoscopic Surgery Approach in Intraorbital Tumours

[1/2]Matoušek P., [2/3]Lupina R., [1]Komínek P., [3]Šmehlík P., [3]Krejčí T., [1]Syrovátka J., [1/2]Zeleník K.

[1]ORL Clinic of Faculty Hospital, Ostrava, Head of the Clinic: P. Komínek
[2]Medical Faculty Ostrava
[3]Neurosurgical Clinic of Faculty Hospital, Ostrava, Head of the Clinic: T. Paleček
[3]Ophthalmic Clinic of Faculty Hospital, Ostrava, Head of the Clinic: P. Mašek

First author:
MUDr. Karol Zeleník, PhD
ORL Clinic of Medical Hospital, Ostrava
17. listopadu 1790
708 52 Ostrava Poruba
E mail: karol. zelenik@fno.cz

SUMMARY

Transnasal Endoscopic Surgery Approach in Intraorbital Tumors

Objectives: To determine the role of transnasal endoscopic approach to orbital lesions
Methods: Retrospective case series.
Results: Three patients underwent endoscopic diagnostic surgery for orbital lesions. In all three patients was successfully finded out the diagnosis, the orbita was decompressed. In two cases it resulted to visual recovery, in one case was determine a diagnosis of metastatic adenocarcinoma. In one case the tumor was removed totally.
Conclusion: Using endoscopic approach to the orbit allowed good approach to the biopsy of orbital lesions, allowed decompression an in limited count of cases this access allowed a complete tumour removal. On the other hand, generally endoscopic approach is useful only for limited lesions (extraconal), usually it allowed only debunking, not the complete resection of orbital pathology.

Key words: orbital lesions, endoscopic approach
Čes. a slov. Oftal., 68, 2012, No. 5, p. 202-206

INTRODUCTION

Tumours localised in the orbit and in particular in the area of the apex of orbit represent a surgical problem due to the relatively narrow access corridor. Multidisciplinary co-operation between the ophthalmologist, otorhinolaryngologist and neurosurgeon brings new methods in the solution of orbital pathology.
The diagnosis of orbital lesions is founded on CT or MRI, but the definitive diagnosis is determined histologically. In addition to the two basic approaches – external (orbitotomy) and transcranial, recently the endoscopic transnasal approach has also been used. The endoscopic approach is suitable especially in the case of lesions localised in the medial part of the orbit, in its posterior part and in the area of the apex. If lesions are localised extraconally, this is an optimum condition from the perspective of the surgeon. In such cases an endoscope enables sufficient visualisation of the operation field, including enlargement. The endoscopic transnasal approach enables both the performance of excision for histological examination and also decompression of the orbit. In certain cases, in particular in the case of extraconal lesions, the approach enables even complete removal of the lesion. The main advantage of the endoscopic approach is the absence of a scar, good clarity in the area of the apex of the orbit, whilst the disadvantage is the lack of dead (air filled) spaces in the orbit [1, 2, 3, 4, 5]. The authors retrospectively present a series of three patients on whom the transnasal endoscopic approach was used in resolving an orbital lesion.

MATERIAL AND METHODS

The endoscopic transnasal approach is selected for patients with lesions in the orbit localised medially or medially and caudally, extra- or intraconally, in the central or posterior part of the orbit. The indication and suitability of the transnasal endoscopic approach was evaluated by an interdisciplinary team composed of an ophthalmologist, an otorhinolaringologist and a neurosurgeon.

Surgical technique
Preoperative ORL (Otorhinolaryngology) preparation
Two hours before the operation (usually with pre-medication), the nose is treated with decongestant causing anemia in that area (oxymetazoline), reducing the blood supply to the nasal mucous membrane. In the case of presence of symptoms of chronic allergic rhinitis, corticoids are systematically administered 3-4 days before the operation (prednisone 20 mg p.o.), which reduce the swelling of the mucous membrane, leading to an improvement of the clarity of the operating field.

Operation
After bringing the patient under general anaesthesia, the head is fixed in a Mayfield clamp, the patient is positioned (ideally with the head angled forwards at approx. 30 degrees), navigation is directed (Medtronic), and there follows disinfection of the operation field. Three strips with adrenalin at a concentration of 1:10 000 are placed bilaterally into the nose for 10 minutes.
The operation is composed of two parts – securing of the surgical approach and the actual orbital phase (extirpation of tumour).

1. Surgical approach
The operation is started by an otorhinolaryngologist with an adrenalin infiltration solution on the mucous membrane in a concentration of 1:100 000 in the posterior part of the septum and central concha, usually on the side where the nasal cavity is more capacious. 4 mm direct and 30°endoscopes are used in connection with a video link, the image is observed on the monitor.

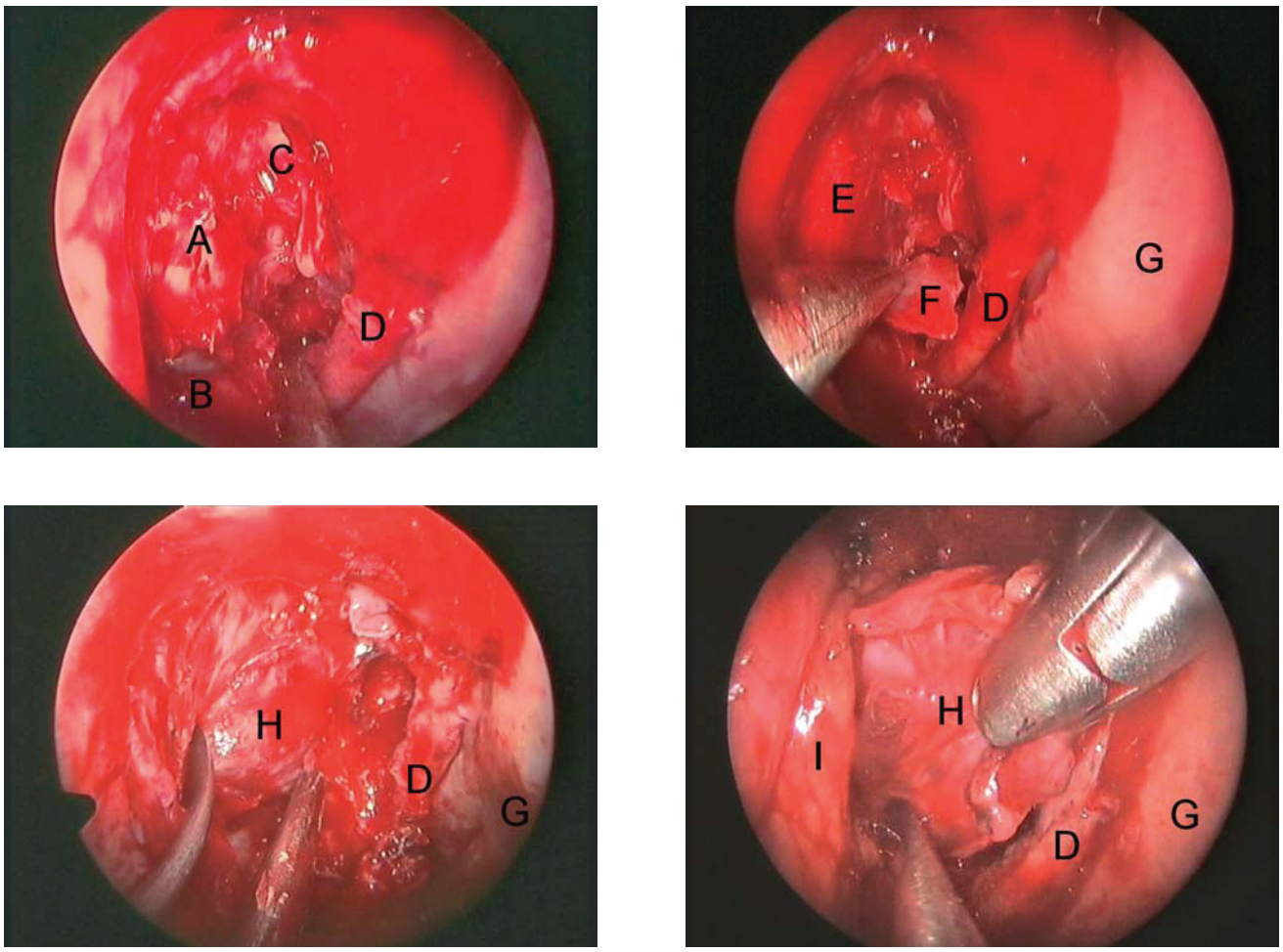

Fig. 1 Endoscopic view, 4 mm 30° endoscope, right nasal cavity 1a, 1b – sinonasal phase, 1c, 1d – orbital phase of A-lamina papyracea, B-maxillary antrum C-opend olfactory alveoli D-upper concha E-periorbita F-removed bone of lamina papyracea G-nasal septum H-tumour I-orbital fat

First of a medialisation of the central concha is performed. There follows resection of the procesus uncinatus, the mouth of the maxillary antrum is widened and anterior and posterior ethmoidectomy is performed. Subsequently the sphenoethmoidal recessus is identified with the ostium of the sphenoidal cavity, and its ostium is widened using a Kerrisonor pliers or Stammberger punch, and the anterior wall is progressively removed for clear identification of the optic nerve impression. This provides access to the lamina papyracea, which is subsequently removed from the posterior edge of the lacrimal sac up to the apex (fig. 1a, 1b). The surgical approach is usually performed by an otorhinolaryngologist with assistance from a neurosurgeon. In the case of adverse anatomical conditions it is possible to perform resection of the central concha in order to ensure a larger space in the nasal cavity.

2. Orbital phase

After the removal of the lamina papyracea (and according to requirement also the medial part of the upper wall of the maxillary antrum medially from the infraorbital nerve), the periorbita is intersected. In the case of an extraconally embedded tumour, after checking of navigations probatory excision or extirpation of the tumour is performed (fig. 1c, 1d). In the case that the lesion is localised intraconally, the medial rectus muscle is identified and according to localisation of the lesion it is extirpated either via the window between the medial and lower or medial and upper muscle. Identification of the internal rectus muscle may be facilitated by the ophthalmologist by pulling of the muscle insertion on the eye.

In the orbital phase, four-handed operation is performed. At the end of the operation light nasal tamponade is performed (Merocel).

Postoperative care

On the first day after the operation the nasal tamponade is removed, and according to requirement postoperative MR is performed in order to determine the radicality of extirpation. After removal of the tamponade, the patient performs rinsing of the nasal cavity (rinsing with salt or mineral water) in order to remove coagulum and crusts which form in the nasal cavity. On the seventh day the crusts are removed under endoscopic supervision. A further endoscopic check follows approximately one to two weeks later according to the finding.

The authors retrospectively evaluate the use this technique on three patients in the years 2009-2011.

RESULTS

Case report 1

A seventy two year old diabetic man was admitted due to refractory hemicrania of the right eye persisting for four months, with pain shooting into the eye, not responding to analgetics. For approximately three months he observed diplopia, in the last month his vision of the right eye decreased, and for approximately three weeks observed a ptosis

of the upper eyelid. An eye examination demonstrated total ophthalmoplegia of the right eye, ptosis, amaurosis. Four months ago polypectomy was performed during colonoscopy, and adenocarcinoma was histologically verified, subsequently upon repeat colonoscopy no a recurrence was found.
On MR of the orbit a large tumor, with partially cystic formation was demonstrated in the right orbit, which is localised in the posterior ocular segment, medially extra- and intraconally, with a size of 25x28x35 mm, reaching the roof of the orbit and deviating the optic nerve laterally (fig. 2).
Histological verification and decompression of the orbit was indicated. Decompression of the orbit was performed by transnasal endoscopy, with taking of a sample for histological examination.
Metastasis of the adenocarcinoma was histologically demonstrated. A further examination demonstrated a tumour of the kidney, the liver, lungs and bones metastasis,. As a primary focus was considered kidney or large intestine. The patient is in oncological care at this time.

Case report 2
A fifty nine year old man was admitted for decreased vision in the right eye persisting for a year and a half, with diplopia temporal and upward. Upon an eye examination a restriction of movement of the eye upwards and laterally was

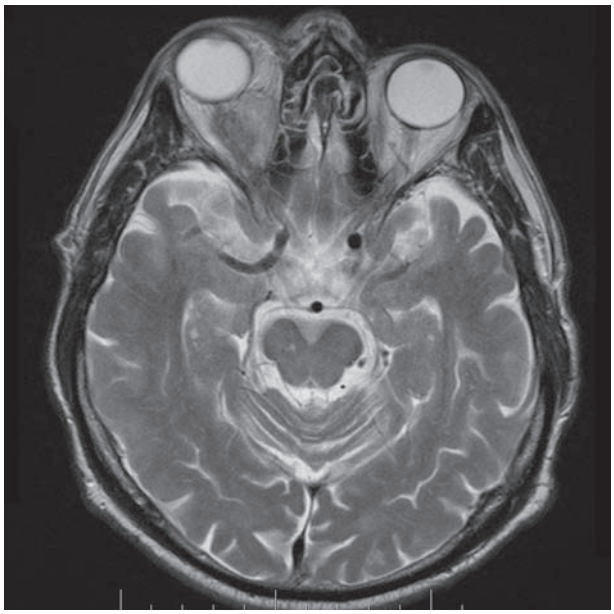

Fig. 2 MR, axial cross-section - large tumor, with partially cystic formation in the right orbit, which is localised in the posterior ocular segment, medially extra and intraconally, size of 25x28x35 mm, reaching the roof of the orbit and deviating the optic nerve laterally

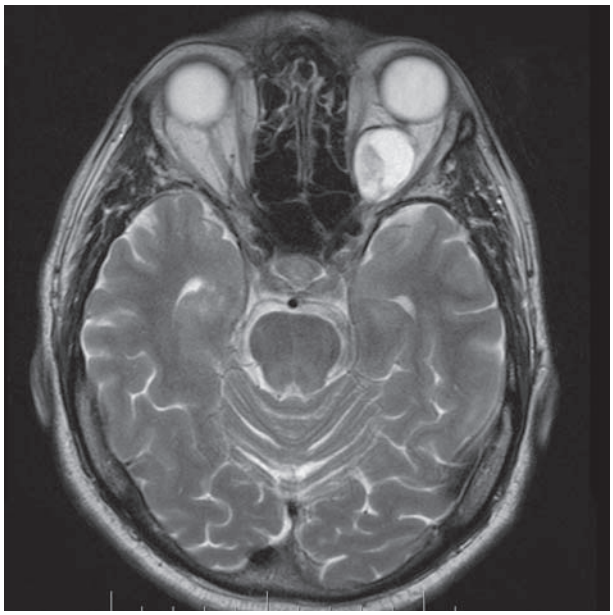

Fig. 3 MR, axial cross-section – intraconal tumour sharp circumcribed, of a predominantly cystic character was determined, with a smaller solid portion medially, with a size of 27x20x18 mm, filling the internal half of the left orbit retrobulbar with an elevation and lateral dislocation of the optic nerve and the oculomotor muscles sideways

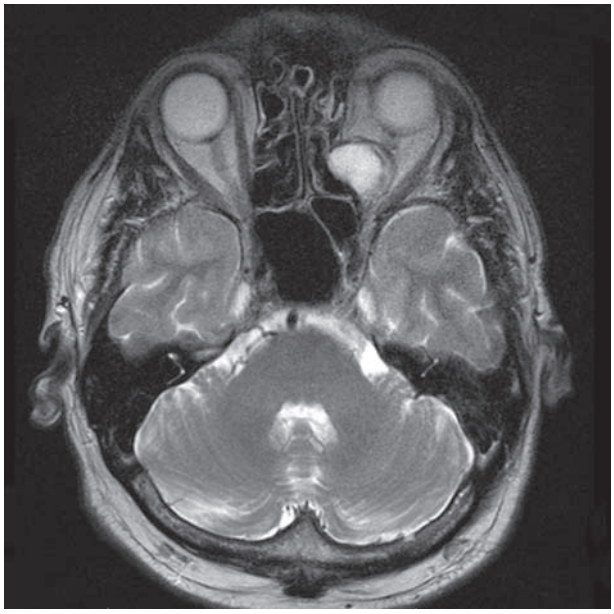

Fig. 4 MR, axial cross-section, 1st day after operation – residue of tumour, which is reduced in comparison with the preoperative finding and bulge in the direction of the olfactory alveoli



Fig. 5 MR, axial cross-section, sharp circumscribed oval, extraconally localised expansion in the medial part of the orbit, reaching from the base to the roof of the orbit. Pressure changes are present in the internal rectus muscle with a swelling, the tumour is enhancing on the MRI.

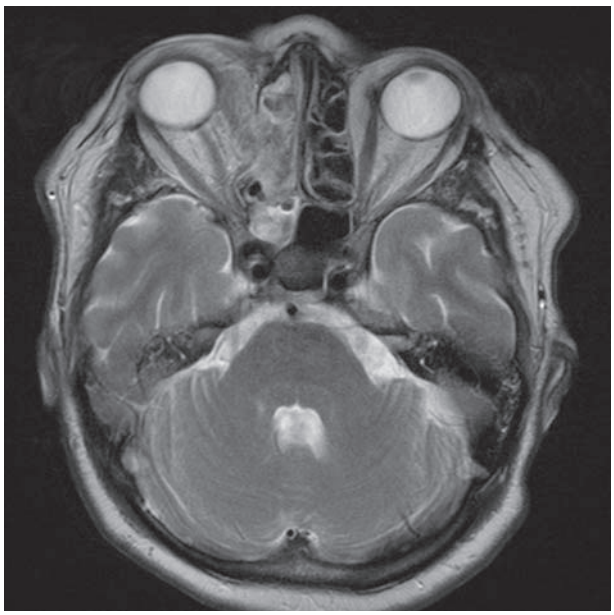

Fig. 6 MR, axial cross-section, 1st day after operation – tumour is completely removed

demonstrated, with an absence of convergence, according to the perimetr there was a visual field defect in the lower quadrants. On MR an intraconal tumour sharp circumsribed, of a predominantly cystic character was determined, with a smaller solid portion medially, with a size of 27x20x18 mm, filling the internal half of the left orbit retrobulbar with an elevation and lateral dislocation of the optic nerve and the oculomotor muscles sideways (fig. 3).
An operation solution was indicated with the aim of decompression of the orbit and obtaining a sample for histological examination. Part of the orbital fat was removed by transnasal endoscopy, after recession of the medial rectus muscle a partial extirpation of the tumour, which was partially solid and partially cystic, was performed. At the end of the operation a regression of the protrusion and mydriasis was observed. A neurofibroma with myxoid characteristics was histologically verified.
In the postoperative period there is a temporary persistence of the upper eyelid ptosis, which is progressively correcting itself, as well as an perimeter defect. Control MR demonstrates the presence of a residue of the tumour, which is reduced in comparison with the preoperative finding and bulge in the direction of the olfactory alveoluses (fig. 4).

Case report 3
A sixty seven year old female patient was admitted due to decreased of vision in the right eye persisting for one year, with diplopia (upon forward and lateral view), headache on the right side and progressively developing protrusion of the eye (the patient is currently being observed by an ophthalmologist for a cataract). An MR examination was performed with a finding an oval, sharp circumscribed extraconally localised expansion in the medial part of orbit, reaching from the base to the roof of the orbit. Pressure changes are present in the internal rectus muscle with a swelling, the tumour is enhancing on the MRI. (fig. 5).
An eye examination demonstrated a restriction of movement upwards, downwards and to adduction, and protrusion of the eye 4 mm.
Endoscopic extirpation of the tumour was indicated. The tumour was removed completely according to the postoperative control MR without the presence of residue (fig. 6). Angioleiomyoma was demonstrated histologically. Postoperative the patient has no diplopia and a normal ocular finding.

DISCUSSION

The aim of the surgical procedure in the area of the orbit is to resolve the present pathology effectively or determine the diagnosis by taking a sample for a histological examination, whilst preserving all ocular functions. The problem of surgical treatment in the orbit is above all the limited access due to the bone-border and relative incompressibility of the content of the orbit. By simple anterior orbitotomy we are able to reach tumorous lesions localised only in the anterior or central part of the orbit. For retrobulbar-localised lesions or in the area of the apex of the orbit it is necessary to select a wider approach with removal of part of the bone around the orbit (e.g. upon the lateral approach, resection of part of the zygomatic arch is necessary, thus improving the approach to the orbit), or it is necessary to select transcranial approaches.
In connection with the development of endoscopic technologies and the endeavour to ensure the minimum possible mini-invasive surgery, use of endoscopic approaches has begun also in the area of orbit surgery since the end of the 20th century. This was first used in the 1990s upon addressing inflammatory complications in the orbit (subperiostal abscesses), which were advantageously resolved transnasally and not from an exterior approach as hitherto, there then followed endoscopic decompressions of the orbit in endocrine orbitopathies (6,7). In recent years certain appropriate both extra and intraconally embedded tumorous lesions have also been dealt with by transnasal endoscopy. The latest techniques use the orbit (subperiostal corridor) as a further “access port” in multi-portal surgery of the cranial base.
Use of an endoscopic transnasal approach in the treatment of tumorous lesions in the orbit has been mentioned only very rarely to date in the international literature, concerning individual case reports, and in the Czech literature this approach has not been published (8, 9, 10, 11, 12).
The transnasal endoscopic approach is useful especially in biopsies of lesions which are localised medially and caudally, ideally extraconally, in the area of the apex of the orbit. Its advantage lies primarily in good visualisation of the pathology due to possible access of the endoscope to the pathology.
The greatest obstacle in endoscopic surgery of the orbit is the lack of dead spaces (spaces filled with air such as in the adjacent nasal cavities) caused by the presence of orbital fat and intermuscular septa, which impairs clarity into the operated field.
Advances in the technique of endoscopic operations, in particular experiences with four-handed surgery, have given the endoscopic approach a new dimension. In previous times endoscopic surgery was performed with only two hands (there was only one surgeon, who held the endoscope with one hand and operated with the other), which enables the performance of simple decompression of the orbit or performance of probatory excision in simpler operations. In operations on tumours, in particular intraconally embedded, it is not

possible to operate without four-handed surgery with the use of the classic microsurgical technique. It is an advantage to apply experiences with this technique from operations in the area of the cranial base and intracranial area (e.g. hypophysis), which is performed as standard by four-handed surgery.

Our experiences show that the use of "four-handed endoscopic surgery" is an essential condition for the successful resolution of tumorous lesions in the area of the orbit, and it is an advantage for this surgery to be performed by a team with experiences from other areas of surgery of the cranial base.

A certain problem is tangential access to the operated pathology (angle of access to the pathology is very acute), which impairs clarity and handling of the instruments. This limit can be overcome by a transseptal approach, in which we can access the lesion from the contralateral nasal cavity after implementation of an opening in the septum.

A considerable advantage of the endoscopic technique is the possibility of gaining access to the pathology and the possibility of using angled optics. The endoscopic approach may naturally be used also in combination with standard external approaches.

Although external approaches enable direct exposure of the tumour, they are significantly hampered by higher morbidity. Transnasal endoscopic approaches may offer advantages in comparison with standard open procedures. However, it is necessary to have special equipment available (drills, suction coagulation etc.), and the experience of the surgical team is equally important (2).

CONCLUSION

The use of the transnasal endoscopic technique in dealing with pathology of the orbit enables improved clarity and handling, especially in the area of the apex of the orbit, whilst maintaining minimum morbidity. The endoscopic transnasal approach is advantageous especially in resolving extraconal lesions, localised medially, whilst the surgical approach to intraconal lesions is more difficult, nevertheless this can also be used in suitable cases.

LITERATURE

1. Tsirbas, A., Kazim, M., Close, L.: Endoscopic Approach to Orbital Apex Lesions.Ophthal Plast Reconstr Surg, 2005; 21(4): 271–275.
2. Stamm, A., Nogueira, JF.: Orbital cavernous hemangioma: Transnasal endoscopic management. Otolaryngol head Neck Surg, 2009; 141: 794–795.
3. Abuzayed, B., Tanriover N., Gazioglu N., et al.: Endoscopic endonasal approach to the orbital apex and medial orbital wall: anatomic study and clinical applications. J Craniofac Surg, 2009; 20: 1594–1600.
4. Otradovec, J.: Volba chirurgického přístupu k orbitálním expanzím. Cesk Oftalmol, 1983; 39(3): 194–7.
5. Otradovec, J.: Orbitologie. Cesk Oftalmol 1983,39(2): 94–9.
6. Šlapák, I.: Endonazální přístup k abscesu orbity u dětí. Otorinolaryng a Foniat /Prague/, 1997; 46(2): 118–122.
7. Šlapák, I.: Chirurgická léčba primárních tumorů orbity. Otorinolaryng a Foniat /Prague/; 2008, 57(4): 206–209.
8. Sethi, DS., Lau, DP.: Endoscopic management of orbital apex lesions. Am J Rhinol, 1997; 11: 449–455.
9. Herman, P., Lot, G., Silhouette, B., et al.: Transnasal endoscopic removal of an orbital cavernoma. Ann Otol Rhinol Laryngál, 1999; 108: 147–150.
10. Karaki, M., Kobayashi, R., Mori, N.: Removal of an orbital apex hemangioma using an endoscopic transethmoidal approach: technical note. Neurosurgery, 2006; 59(suppl 1): 159–160.
11. Yoshimura, K., Kubo, S., Yoneda, H., et al.: Removal of a cavernous hemangioma in the orbital apex via the endoscopic transnasal approach: a case report. Minim Invasive Neurosurg 2010, 53:77-79.
12. Castelnuovo, P., Dallan, I., Locatelli, D., et al.: Endoscopic transnasal intraorbital surgery: our experience with 16 cases. Eur Arch Otorhinolaryngol, 2012; 269: 1929–1935.