Comparison of safety and efficacy of two dispersive hyaluronate OVDs used in cataract surgery

Stodůlka Pavel[1,2], Jirátková Simona[1], Klimešová Kateřina[1], Prachařová Zuzana[1], Tihelková Eva[1], Uhlářová Petra[1], Slovák Martin[1], Randárová Eva[1]

[1]Gemini Eye Clinic, Zlin, Czech Republic
[2]Ophthalmology Department, Third Faculty of Medicine, Charles University, Prague, Czech Republic



MUDr. Pavel Stodůlka, Ph.D.

Submitted to the editorial board: May 4, 2025
Accepted for publication: June 29, 2026
Available on-line: August 3, 2026
https://doi.org/10.31348/2026/29

The authors declare that in 2022 they entered into a contractual agreement with Rayner Group (UK) and received financial support for conducting the clinical study and for publication. The study was conducted in accordance with the Declaration of Helsinki. Approval was granted by the Ethics Committee of Gemini Eye Clinics, Czech Republic.

Correspondence address:
Oční klinika Gemini
U Gemini 360
760 01 Zlín
Czech Republic
E-mail: stodulka@lasik.cz

SUMMARY

Purpose: To compare safety and efficacy of ophthalmic viscosurgical devices (OVDs) – OphteisBio 3.0 (Rayner) and Healon Endocoat (J&J Vision) in phacoemulsification cataract removal surgery.
Materials and Methods: In this prospective subject/evaluator-masked post-market randomized study patients undergoing phacoemulsification were assigned to receive one of two hyaluronate-based OVDs – OphteisBio 3.0 and Healon Endocoat. The outcomes were the rate of intraocular pressure (IOP) spikes ≥ 30 mmHg at the 7-day postoperative visit, endothelial cell density changes, the surgeon acceptance rate, IOP change from baseline, rates of inflammation and rates of serious and/or device-related adverse events.
Results: The study included 293 eyes – 146 in the Ophteis group and 147 in the Healon group. No IOP spikes were noted at the 7-day postoperative visit with mean IOP of 14.5 mmHg for Ophteis group and 14.3 mmHg for the Healon group. The mean endothelial cell density loss after the surgery was 9.8% in the Ophteis group and 10.2% in the Healon group with no statistically significant difference between the two OVD groups ($p = 0.6292$). At the 7-day visit, anterior chamber flare was absent in 98% and 99% of eyes in the Ophteis and Healon group, respectively. 82% of eyes had no anterior chamber cells at 7-day visit in both groups. No adverse events were recorded during surgery and at 7-day follow up. No clinically relevant differences were found between the two OVDs.
Conclusion: Ophteis 3.0 and Healon Endocoat have comparable results following phacoemulsification surgery.
Key words: ophthalmic viscosurgical devices (OVDs), cataract surgery, sodium hyaluronate, intraocular pressure, endothelial cell density

Čes. a slov. Oftal., 82, 2026, No. x, p.

INTRODUCTION

In phacoemulsification cataract removal surgery, ophthalmic viscosurgical devices (OVDs) are indispensable tools to protect corneal endothelium and other intraocular tissues and to facilitate surgical maneuvers, e.g. capsulorhexis creation or intraocular lens implantation [1,2]. Numerous studies have compared the ability of diverse OVDs to protect corneal endothelial cells during cataract surgery, with reports ranging between 4%–18% of endothelial cell density reduction [1–14]. Dispersive OVDs based on hydrophilic polymers with shorter chains, e.g. sodium hyaluronate, exhibit lower viscosity and high coating ability compared to cohesive OVDs. Their adherence to intraocular structures enables excellent protection of the corneal endothelium, however, might prolong their evacuation at the end of the surgery. The complete removal of OVDs prevents an undesired increase in intraocular pressure (IOP) postoperatively [15,16]. Since hyaluronate is physiologically expressed in the eye, hyaluronate-based OVDs offer excellent biocompatibility compared to frequently used plant-derived hydroxypropyl methylcellulose which was reported to cause allergic reactions [17].

Originally, hyaluronate-based OVDs have been produced via animal tissue extraction, e.g. from rooster combs. Due to extensive purification protocols, ethical and environmental concerns, potential allergenicity and inconsistent quality the animal tissue extraction is being replaced by biotechnological production offering controlled, consistent production with fewer contamination risks and better biocompability [18]. The biotechnological strategy used to produce Healon Endocoat and OphteisBio 3.0 is based on the microbial fermentation using hyaluronate-producing bacteria, which increases the OVD safety [19,20].

Sodium hyaluronate is viscous at rest, but its pseudo-plastic properties enable to easily expel the solution through the cannula when pressure is applied. After instillation the viscous properties are restored. This study intends to compare the performance of two dispersive hyaluoronate-based OVDs with equivalent composition - OphteisBio 3.0 (Rayner, Worthing, UK), further referred to as Ophteis, with Healon Endocoat (J&J Vision, Santa Ana, CA, USA), further referred to as Healon. While Healon is widely used and its protective effect on corneal endothelial cells has been demonstrated in many studies [21–24], Ophteis has been recently launched to the market and has not been compared to another OVD to our best knowledge. As Healon is considered a market leader, evaluating the performance of newer OVDs against this well-accepted benchmark helps determine whether reliable clinical alternatives exist. In this study we compared the OVD effect on corneal endothelial cell density loss and IOP following phacoemulsification cataract surgery.

METHODS

Study Design

This was a prospective, multicenter, randomized, subject/evaluator-masked control study conducted at three Gemini Eye Clinics (Zlín, Vyškov, Průhonice) in Czech Republic between August 2022 and October 2023 (registered at ClinicalTrials.gov under identifier NCT05832749). This study was approved by the Ethics Committee of Gemini Eye Clinics (Etická komise oční kliniky Gemini, U Gemini 360, Zlin, Czech Republic; approval reference number: 2022-06) and adhered to the tenets of the Declaration of Helsinki. All patients provided a written informed consent before entering the trial.

The study was designed to compare two OVDs with equivalent composition– Ophteis and Healon. The characteristics of studied OVDs are summarized in Table 1. Both studied OVDs are sterile nonpyrogenic solution of highly purified sodium hyaluronate (30.0 mg/ml) with rheologically dispersive properties.

Participants

The study included patients who underwent primary cataract extraction and IOL implantation and who met all study inclusion and exclusion criteria. Patients could have one or both eyes included in the study (provided the surgeries are within the study timeframe) and any intraocular lens could be implanted.

The inclusion criteria were patients who had phacoemulsification cataract removal with intraocular lens implantation in the capsular bag and attended the 7-day postoperative IOP measurement. Exclusion criteria were 1) pupil abnormalities (non-reactive, fixed pupils, or abnormally shaped pupils); 2) recent ocular trauma or ocular surgery that is not resolved/stable or may affect visual outcomes or increase risk to the subject; 3) known steroid responder; 4) ocular hypertension of ≥ 20 mmHg, medically-controlled ocular hypertension (regardless of IOP value), or glaucomatous changes in the optic nerve; 5) patient is pregnant, plans to become pregnant, is lactating or has another condition associated with the fluctuation of hormones that could lead to refractive changes; 6) concurrent participation, or participation within 45 days prior to the preoperative visit, in any other clinical trial.

Preoperative, Intraoperative and Postoperative interventions

All eyes were assessed at least once preoperatively, including – endothelial cell density (ECD), axial length (AL), anterior chamber depth (ACD), IOP measurement and slit lamp biomicroscopy assessment of the eye. Intraoperative parameters recorded were – type of OVD used, average ultrasound power (AVE), actual phacoemulsification time (APT) and effective phacoemulsifica-

Table 1. OVD characteristics

	Ophteis	Healon
Osmolality (mOsm/kg)	300–350	320
Molar weight (kg/mol)	750	800
Viscosity at zero shear rates (mPa*s)	30 000	50 000
pH	6.8–7.6	7.0–7.5
Composition (mg/ml)		
Sodium hyaluronate	30.00	30.00
Sodium chloride	8.00	5.00
Potassium chloride		0.56
Calcium chloride		0.36
Magnesium chloride		0.22
Disodium hydrogen phosphate	0.28	0.42
Sodium dihydrogen phosphate	0.045	0.06
Sodium acetate		2.92
Sodium citrate		1.28
Water for injection	sufficient quantity	sufficient quantity
Source (sodium hyaluronate)	Biofermentation	Bacterially derived

tion time (EPT) – which is the multiplication of AVE by APT, total phacoemulsification duration, OVD removal time and total surgery time.

Any adverse events were recorded. Postoperative assessment occurred at postoperative day one and day seven with recording of IOP and ECD.

ECD was measured on the CEM-530 specular microscope by Nidek. AL and ACD were measured on the IOLMaster 500 or 700 optical biometer by ZEISS. IOP was measured using tonometer Tonoref II or III by Nidek.

Surgical Technique

All surgeries were performed as standard phacoemulsification with intracameral anesthesia through a 2.2 mm limbal corneal incision on the steep corneal axis to reduce corneal astigmatism. Preoperatively, pupil dilation was achieved using topical administration of 1% cyclopentolate (Cyclogyl™, Alcon Laboratories, Inc., USA), 10% phenylephrine (Neosynephrin™, Ursapharm, Germany), and 0.5% tropicamide (Unitropic™, Unimed Pharma, Slovakia), with each agent instilled at 10-minute intervals over a 30-minute period. At the beginning of each surgery, topical anesthesia was administered using 0.4% oxybuprocaine hydrochloride (Benoxi®, Unimed Pharma, Slovakia) and 1% tetracaine hydrochloride (magistraliter-prepared ophthalmic solution, Czech Republic). After standard cleaning and draping protocol, a 2.2 mm corneal incision was made followed by two side-port paracenteses. The dispersive OVD, either Ophteis or Healon, was injected into the anterior chamber to coat the endothelium before continuous curvilinear capsulorhexis was performed. Hydrodissection was performed followed by phacoemulsification of the nucleus and aspiration of the cortical residues. After the intraocular lens implantation into the capsular bag the injected OVD was completely removed by an anterior chamber maintainer attached to Balanced Salt Solution (BSS). Surgical wounds were hydrated with BSS and checked for leakage and potential ocular hypotony or hypertony palpably. The following topical medication was used: tobramycin/dexamethasone drops (Tobradex™, Alcon laboratories, Inc) five times a day for the first 3 post-operative days and then three times a day until the bottle was finished; diclofenacum natricum drops (Dicloabak™, Laboratoires Thea, France) three times a day until the bottle was finished.

Outcomes

The primary outcome was the occurrence of an IOP spike ≥ 30 mmHg at the 7-day postoperative follow-up. The secondary outcomes were the change in ECD from baseline to the postoperative 7-day postoperative visit and the rate of user acceptance evaluated using the surgeon questionnaire at the end of each surgical case to collect information regarding OVD perception. The questionnaire collected information regarding the overall performance, ease of injectability, acceptability of the viscosity, adherence to endothelium, anterior chamber maintenance, quantity of bubbles, transparency/visibility, tissue manipulation, ease of IOL placement and ease of removal. The surgeon evaluated each parameter of the questionnaire using a 5-point grading scale. User acceptance was defined as a value of 5 to 1, 5 being the best scoring possible and 1 the worst scoring. For analysis, score of 5 was defined as excellent, scores of 3 and 4 defined as acceptable and scores of 1 and 2 as unacceptable.

In addition, post-operative corneal edema, anterior chamber cells and anterior chamber flare grading were evaluated according to Table A and B (Supplemental material).

Sample size

The sample size of 133 eyes per OVD group is based on the primary endpoint of IOP spike rate at the 7-day postoperative visit, with a target of equivalence between the OVD groups. A sample size of 133 eyes per group provides 80% power to establish equivalence, assuming an equivalence limit of ±8.5%, an expected IOP spike rate of 8.5% in the control group and an alpha level of 0.05. It is expected that 10% of the randomized eyes will miss the 7-day postoperative IOP measurement. Therefore, a total of 148 subjects per group (296 in total) was targeted.

Randomization and blinding

A randomization list was created by the sponsor biostatistician for each investigative site. Each eye was randomly assigned to receive either Ophteis OVD or Healon OVD on a 1:1 basis. Randomization took place after the subject signed the informed consent document, met all inclusion and exclusion criteria.

In terms of randomization/blinding, the injectors were labelled with the patient number based on the randomization code. During the surgery, a nurse obscured the label and the commercial name on the syringe using sterile tape and pass the syringe to the surgeon. To mitigate bias, all surgeons were trained to follow a standardized injection and removal protocol. In addition, the study personnel performing procedures at the 7-day postoperative visit was also masked to the randomly-assigned OVD. The staff assigned to open the OVD and provide to the surgeon was not involved in the post-operative assessment.

Statistical Analysis

Descriptive statistics mean, standard deviation (SD), median, minimum (min), maximum (max) values were used to report the data. Since the Shapiro-Wilk test did not show normality of the data, nonparametric Wilcoxon signed-rank test was used to test the differences between preoperative and postoperative values, Mann-Whitney to test differences between Ophteis OVD group and control Healon OVD group and Fisher's exact test in contingency tables. A value of $p < 0.05$ was considered statistically significant. GraphPad Prism (version 10.1.0) was used to perform all statistical calculation.

The number and percentage of eyes with a user acceptance was summarized by OVD groups and analyzed using the non-inferiority approach with a non-inferiority

margin of 15%. The lower confidence interval limit of the two-sided 90% confidence interval (CI) of the difference in user acceptance rate between the Ophteis group and the Healon group was used for evaluation. In addition, each question from the investigator questionnaire was summarized using count and percentages by OVD group.

The analysis was performed at the eye level. One eye per patient was routinely included in the study; only one patient contributed both eyes. Given the negligible proportion of fellow eyes included, the potential effect of inter-eye correlation on the statistical analysis was considered minimal, and no specific statistical adjustment was applied.

RESULTS

Preoperative and intraoperative characteristics

The study included 293 eyes of 146 patients randomly assigned to one of the two OVDs, with 146 in the Ophteis group and 147 in the Healon group. The preoperative and intraoperative characteristics are summarized in Table 2. There were no statistically significant differences found between the groups in all preoperative and intraoperative variables.

Intraocular pressure

IOP within one hour after the surgery slightly decreased compared to the preoperative IOP with median of change of -2.0 mmHg and maximum IOP of 24.0 mmHg for the Ophteis group, and with median of change of -2.5 mmHg and maximum IOP of 32.3 mmHg for the Healon group (Graph 1, Table C in Supplemental material). Two eyes (2%) from the Healon group exhibited IOP ≥ 30 mmHg (32.0 and 32.3 mmHg).

At the 7-day postoperative visit no event of IOP spike ≥ 30 mmHg was noted in any group. The maximum postoperative IOP was 27.0 mmHg in the Ophteis group and 27.3 mmHg in the Healon group with median of change -1.0 mmHg in both groups compared to preoperative measurement (Figure 1, Table C in Supplemental material). No statistically significant difference in IOP was observed between the groups pre- or postoperatively.

Corneal Endothelial Cell Density

The surgery caused a significant decrease in ECD in both groups when comparing the measured values before the surgery and at the 7-day visit (Wilcoxon test, $p < 0.0001$) with median of change -88 cells/mm^2 in the Ophteis group and with median of change -76 cells/mm^2 in the Healon group, corresponding to mean cell density loss of 9.8% and 10.2%, respectively from baseline (Graph 2A, Table D in Supplemental material). However, no statistically significant difference between the two OVD groups was observed (Mann-Whitney test, $p = 0.6292$). Approximately ¾ of eyes in both groups had ECD loss at the 7-day visit within 10% compared to preoperative measurement.

Table 2. Preoperative and intraoperative characteristics

Variable	Ophteis (n = 146)	Healon (n = 147)	*p value*
Age (years) Mean ± SD Median (range)	 71.4 ±7.7 72.5 (54–89)	 71.2 ±7.9 72.0 (51–87)	 0.9115
Gender ratio (Male:Female)	60:86	59:88	0.9056
ECD (cells/mm^2) Mean ± SD Median (range)	 2566 ±337 2587 (979–3377)	 2630 ±313 2648 (1063–3426)	 0.1046
AL (mm) Mean ± SD	 23.35 ±0.97	 23.48 ±1.16	 0.5117
ACD (mm) Mean ± SD	 3.10 ±0.35	 3.13 ±0.40	 0.3915
IOP (mmHg) Mean ± SD Median (range)	 15.4 ±3.0 15.6 (8.5–23.0)	 15.0 ±2.8 15.0 (9.5–23.0)	 0.1665
US AVE (%) Mean ± SD Median (range)	 14.44 ±8.59 12.00 (1.00–43.00)	 14.35 ±9.05 11.00 (2.00–42.00)	 0.7329
APT (sec.) Mean ± SD Median (range)	 25.80 ±16.14 22.67 (1.11–116.99)	 25.12 ±15.45 24.09 (0.86–112.47)	 0.9191
EPT (sec.) Mean ± SD Median (range)	 3.99 ±2.59 3.84 (0.02–13.68)	 3.94 ±3.24 3.35 (0.05–20.72)	 0.3688

n = number of eyes; SD = standard deviation; ECD = endothelial cell density; AL = axial length; ACD = anterior chamber depth; IOP = intraocular pressure; US AVE = average ultrasound power; APT = actual phacoemulsification time; EPT = effective phacoemulsification time

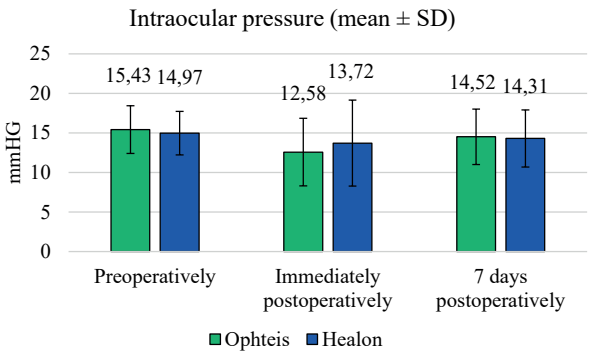

Graph 1. Intraocular pressure in the two groups – preoperatively, within one hour and 7 days after the surgery

12 eyes (9%) in the Ophteis group and 12 eyes (8%) in the Healon group lost more than 30% (Graph 2B) with the minimum endothelial cell density of 574 cells/mm² in the Ophteis group and 492 cells/mm² in the Healon group. In both cases ECD reduction was most likely caused by hard cataract and prolonged phacoemulsification time.

Slit lamp examination/complications

No serious adverse events related to the studied OVDs were reported. Overall occurrence of corneal edema (grade 1–3) at the 7-day visit was statistically insignificantly higher (p = 0.1935) in the Ophteis group (15%) compared to the Healon group (10%) but most were of grade 1 (20 out of 22 in the Ophteis group, 10 out of 14 in the Healon group) (Table E in Supplemental material).

Concerning the signs of inflammation, 82% of eyes had no anterior chamber cells at the 7-day visit in both groups (Table F in Supplemental material) and only 2% and 5% of eyes exhibited anterior chamber cells of grade 1+ or higher in the Ophteis and Healon group, respectively. At the 7-day visit, anterior chamber flare was absent in 98% and 99% of eyes in the Ophteis and Healon group, respectively.

Subjective Surgical OVD Performance

There was a statistically significant difference in ease of injectability (question 2) ($p < 0.0001$) and transparency/visibility (question 7) ($p = 0.0335$) where investigator's ratings were slightly higher in the Healon group. Other

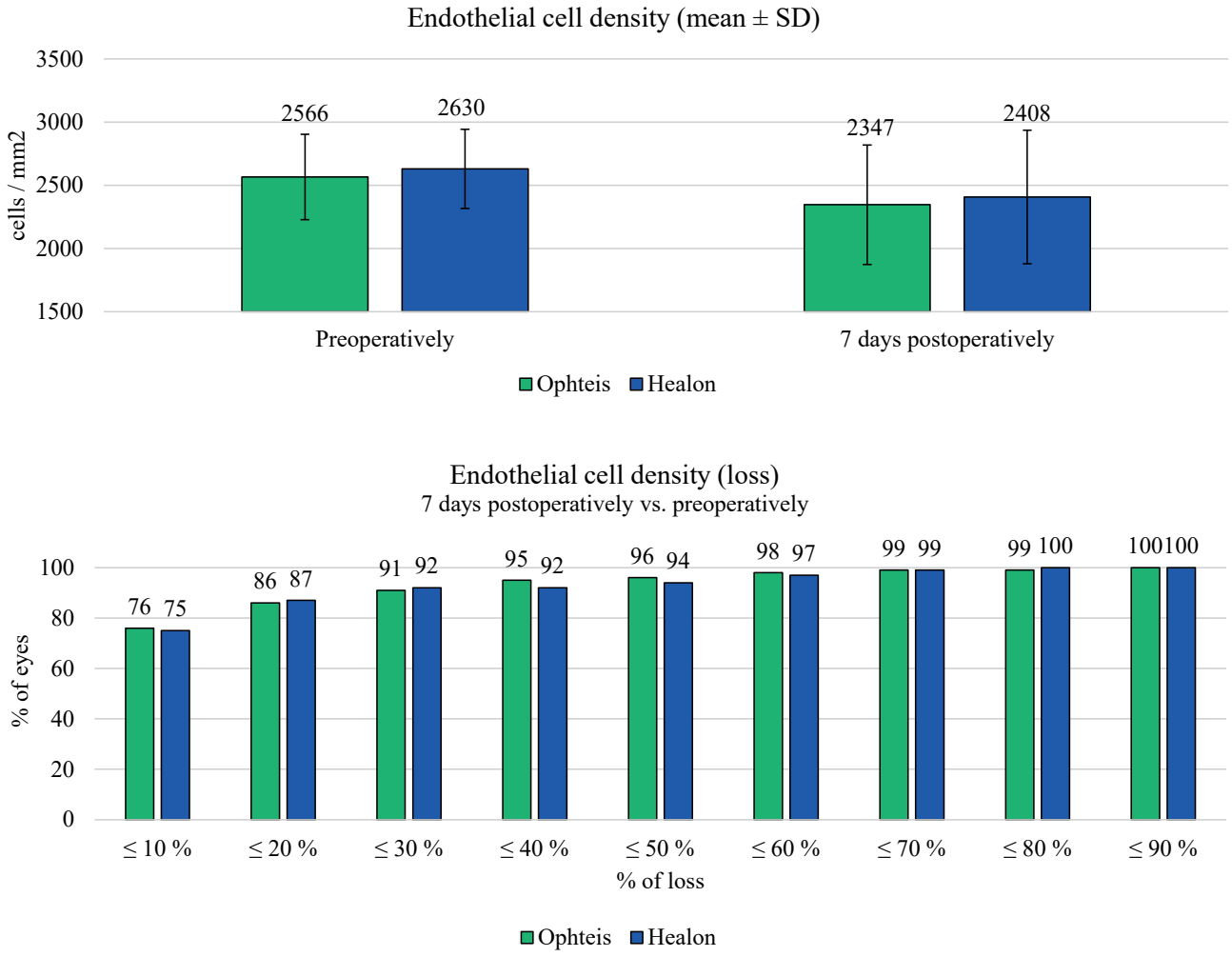

Graph 2. Endothelial cell density (cells/mm²) in the two groups – (**A**) preoperatively and on a (**B**) postoperative day 7. Histogram of endothelial cell density loss

assessed OVD parameters were comparable for both OVD groups based on investigator's answers (Graph 3).

Surgery parameters

The total surgery time was comparable in both groups. The difference in the OVD removal time in seconds (sec) was statistically significant with the mean removal time of 69 sec in the Ophteis group and 80 sec in the Healon group, however, clinically irrelevant (Table 3).

DISCUSSION

In modern phacoemulsification cataract surgery, OVDs are essential for reducing postoperative corneal trauma since the corneal endothelium, which is crucial for maintaining corneal transparency and hydration, consists of a fragile monolayer of non-regenerating cells [23]. Together with the refinement of the surgical technique OVDs have contributed to reducing of the incidence rate of inflammation and corneal trauma that often delayed postoperative visual restoration [24]. Dispersive OVDs based on sodium hyaluronate have shown excellent biocompatibility, high coating ability and superior protection of endothelial cells compared to a dispersive OVD based on hyproxypropylmethylcellulose or a cohesive hyaluronate-based OVD due to their rheological and anti-inflammatory properties [25]. This study compared two dispersive OVDs based on sodium hyaluronate with equivalent composition – 30 mg/ml of sodium hyaluronate with

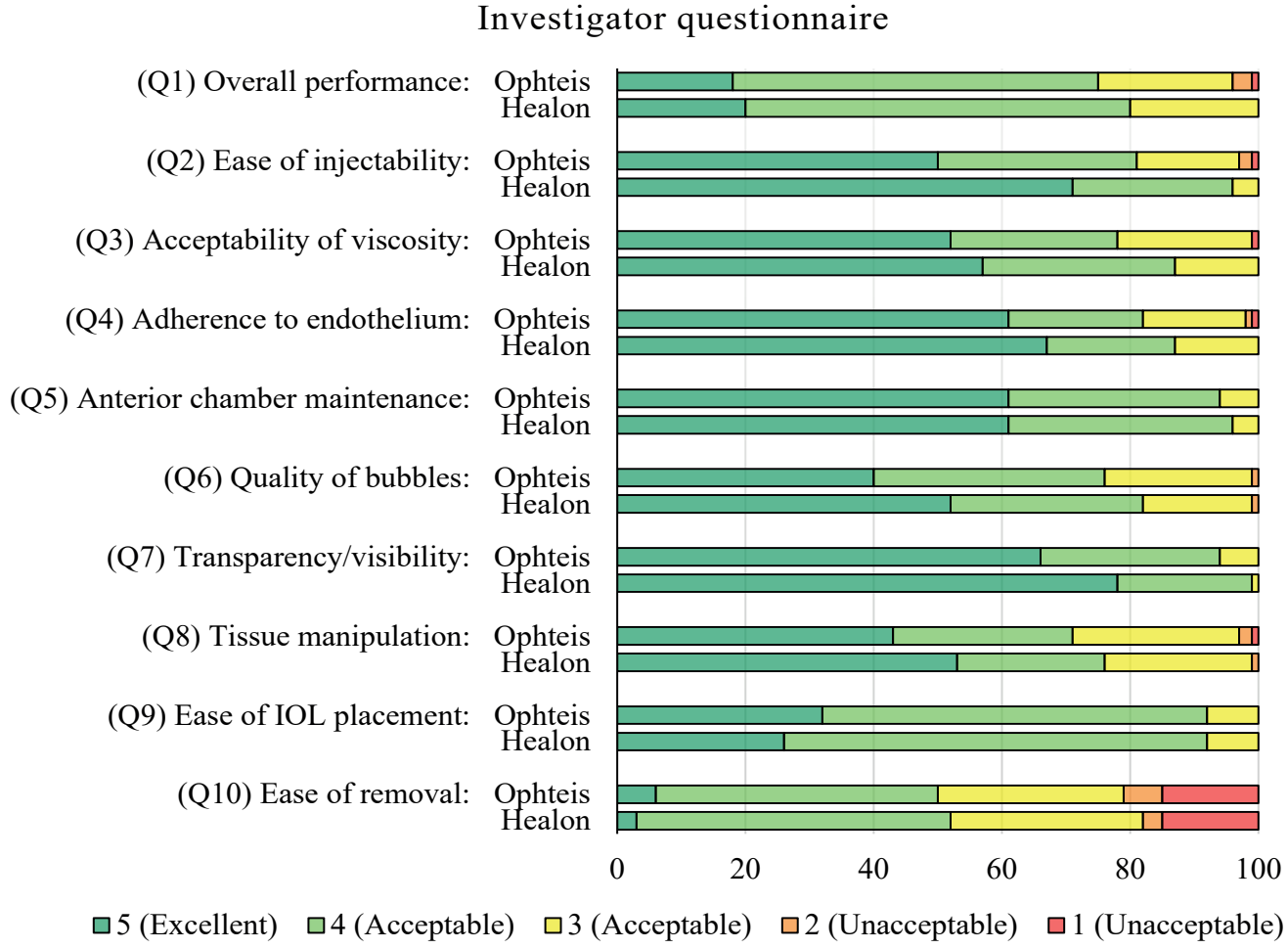

Graf 3. Investigator subjective questionnaire outcomes

Table 3. Surgery parameters

		n	mean	SD	median	min	max	*p*
OVD removal (min:sec)	**OphteisBio 3.0**	130	01:09	00:48	01:01	00:01	03:56	0.0338
	Healon	136	01:20	00:51	01:09	00:02	05:26	
Surgery total (min:sec)	**OphteisBio 3.0**	131	08:37	02:38	08:19	04:54	19:41	0.566
	Healon	136	08:45	02:32	08:12	05:03	20:14	

molecular weight ranging from 750–800 kg/mol produced using microbial biotechnology.

Despite slight difference in the hyaluronate manufacturing process and OVD viscosity, both studied devices were effective in protecting the corneal endothelium and did not induce IOP spikes after surgery. Since early postoperative IOP elevation is a frequent adverse event of cataract surgery and extremely high or prolonged ocular hypertension may result in corneal edema, pain or severe complications [26], extra care was taken at the end of the surgery to remove all the OVD residues which may mechanically obstruct the trabecular outflow pathway. Complete OVD removal together with proper ocular postoperative hydration resulted in the zero incidence of IOP spikes ≥ 30 mmHg in the Ophteis group. Two cases of IOP spikes in the Healon group measured within one hour after the surgery normalized within a week. No occurrence of IOP spike or IOP elevation at the 7-day visit with median of change -1.0 mmHg in both groups implies the successful removal of both OVDs and proves their safety in cataract surgery. The postoperative IOP decrease was repeatedly observed and is probably caused by improved aqueous flow in the anterior chamber [27–29], which explains the statistical differences pre- and postoperatively. Therefore, the postoperative IOP decrease in both groups is in a good agreement with previously published studies using OVDs in cataract surgery [8,12].

The OVD effectiveness to protect the corneal endothelial cells was evaluated by measuring the postoperative ECD reduction from baseline. The OVD injection into the anterior chamber prevented the corneal endothelial cell damage during phacoemulsification in most patients. In both groups the mean ECD loss from baseline was approximately 10%, and up to 75% of eyes exhibited ECD loss within 10% compared to preoperative measurement at the 7-day visit. In order to reflect the average cataract population this study did not exclude eyes with preoperative ECD below 1,500 cells/mm^2, hard cataract, pseudoexfoliation cases, shallow anterior chambers, poor dilation, Malyugin ring use, intraoperative floppy iris syndrome or zonulolysis with insertion of a capsular tension ring unlike previously published studies [8,10–12,30]. Despite this fact we were able to maintain the mean endothelial cell density loss at a relatively low level compared to previously reported ECD reductions, ranging between 4% and 18% using dispersive or cohesive OVDs alone or sequentially [1–9,11,12,31]. The more pronounced endothelial damage with ECD loss ≥ 30% was caused by the prolonged phacoemulsification time due to the presence of hard cataract and did not significantly differ between the groups. Nevertheless, the minimum ECD 7 days postoperatively did not drop below the critical endothelial cell density (400-500 cells/mm^2) required for maintaining the pump function of the corneal endothelium [32–34].

In addition to IOP elevation and ECD, corneal edema, flare and the presence of anterior chamber cells were assessed pre- and postoperatively to evaluate the OVD effectivity. One week postoperatively no corneal edema was observed in 85% and 90% of eyes in the Ophteis and Healon group, respectively. The slightly higher occurrence of corneal edema at the 7-day examination in the Ophteis group (15%) compared to the Healon group (10%) did not reach statistical significance and can be regarded as clinically irrelevant in our opinion. The corneal edema was of grade 1 in the majority of cases with only one eye with corneal edema of grade 3 in the Healon group. The incidence of corneal edema was expectable since the measurement was assessed only 7 days after surgery and no further intervention was necessary in any patient.

The subjective assessment of the OVDs showed that both OVDs were well accepted by surgeons. The analysis of separate parameters from the surgeon questionnaire revealed significant differences in two parameters, however the number of the ratings "unacceptable" was relatively low in both groups. We believe that the impact of these differences on the overall usability of the devices is clinically irrelevant.

The superior coating ability of dispersive OVDs enabling an effective endothelial cell protection comes with a price at the end of the surgery since their removal from the anterior chamber is not as simple compared to highly viscous cohesive OVDs [35]. The complete removal of dispersive OVDs may require a prolonged aspiration/irrigation process which can result into additional endothelial cell loss. Both studied OVDs were completely removed relatively quickly (approximately within 1 minute) compared to the mean total surgery time of almost 9 minutes. The Ophteis OVD was removed faster than the Healon OVD ($p = 0.0338$), however, it did not affect the total surgery time which was comparable in both groups ($p = 0.566$).

A limitation of this study is the relatively short 7-day follow-up period. While this interval is sufficient to evaluate the early safety and efficacy of the OVDs, it does not allow assessment of longer-term changes in corneal endothelial cell density or the persistence of potential differences between the study groups. This follow-up schedule reflects the routine clinical practice at our institution, where patients are subsequently followed by their referring ophthalmologists after the early postoperative period.

CONCLUSION

Our study included eyes with diverse ocular conditions who underwent phacoemulsification cataract surgery using OVDs. Due to large number of eyes, the study was limited only to one postoperative follow-up on day 7. No clinically relevant differences were found between the two OVDs regarding temporary IOP spikes, mean IOP, corneal endothelium trauma, or inflammation. Pronounced ECD losses occurred in individual cases associated with the existence of hard cataracts resulting in a prolonged exposure of phacoemulsification energy. In conclusion, OphteisBio 3.0 and Healon Endocoat, have a comparable protective effect on corneal endothelial cells and a similar effect on IOP elevation. Both OVDs were safe, highly effective and well-accepted by the surgeons.

SUPPLEMENTAL MATERIAL

Table A. Corneal edema grading

Grade	Corneal edema
0	Completely clear cornea
1	Focal exudation in stroma
2	Increase in stromal thickness
3	Severe increase in thickness and exudation

Table B. Anterior chamber cells and flare grading

Grade	Cells	Flare
0	< 1	None
0,5+	1–5	–
1+	6–15	Faint
2+	16–25	Moderate
3+	26–50	Marked
4+	> 50	Intense

Table C. Changes of intraocular pressure

IOP changes	Ophteis		Healon	
	Preop vs. Imm. Postop	Preop vs. 7D postoperatively	Preop vs. Imm. Postop	Preop vs. 7D postoperatively
Number	116	141	118	147
Mean	-2.9	-0.9	-1.2	-0.7
SD	4.6	2.8	5.4	2.6
Median	-2.5	-1.0	-2.0	-1.0
Minimum	-13.0	-10.0	-12.0	-5.5
Maximum	10.0	8.5	16.6	13.0
P value	**< 0.0001**	**< 0.0001**	**0.0032**	**0.0004**

IOP – intraocular pressure; SD – standard deviation; Preop – preoperatively; Imm. Postop – immediately postoperatively; 7D – 7 days

Table D. Endothelial cell density (ECD) changes between 7-day visit and baseline

ECD changes	Ophteis	Healon
Number	137	145
Mean	-228.7 (-9.8%)	-221.8 (-10.2%)
SD	403.1 (14.3%)	398.8 (15.7%)
Median	-88 (-4.4%)	-76 (-4.0%)
Minimum	-2636 (-82.1%)	-2023 (-74.0%)
Maximum	164 (0%)	341 (0%)
P value	**< 0.0001**	**< 0.0001**

ECD – endothelial cell density; SD – standard deviation

Table E. Slit lamp – Cornea status

Cornea status			
	Grade	Ophteis	Healon
Corneal edema	0	120 (85%)	133 (90%)
	1	20 (14%)	10 (7%)
	2	2 (1%)	3 (2%)
	3	0 (0%)	1 (1%)

Table F. Slit lamp – Signs of inflammation

Signs of inflammation			
	Grade	**Ophteis**	**Healon**
Anterior chamber cells	0	115 (82%)	120 (82%)
	0.5+	23 (16%)	19 (13%)
	1+ or more	3 (2%)	8 (5%)
Anterior chamber flare	0	138 (98%)	146 (99%)
		3 (2%)	1 (1%)

REFERENCES

1. Miyata K, Nagamoto T, Maruoka S, et al. Efficacy and safety of the soft-shell technique in cases with a hard lens nucleus. J Cataract Refract Surg. 2002;28:1546-1550. doi.org/10.1016/S0886-3350(02)01323-8
2. Vajpayee RB, Verma K, Sinha R, et al. Comparative evaluation of efficacy and safety of ophthalmic viscosurgical devices in phacoemulsification. BMC Ophthalmol. 2005;5:17. doi.org/10.1186/1471-2415-5-17
3. Storr-Paulsen A, Nørregaard JC, Farik G, et al. The influence of viscoelastic substances on the corneal endothelial cell population during cataract surgery: A prospective study of cohesive and dispersive viscoelastics. Acta Ophthalmol Scand 2007;85:183-187. doi.org/10.1111/j.1600-0420.2006.00784.x
4. Moschos mm, Chatziralli IP, Sergentanis TN. Viscoat versus Visthesia during phacoemulsification cataract surgery: corneal and foveal changes. BMC Ophthalmol. 2011;11:9. doi.org/10.1186/1471-2415-11-9
5. Van Den Bruel A, Gailly J, Devriese S, et al. The protective effect of ophthalmic viscoelastic devices on endothelial cell loss during cataract surgery: a meta-analysis using mixed treatment comparisons. Br J Ophthalmol. 2011;95:5-10. doi.org/10.1136/BJO.2009.158360
6. Holzer MP, Tetz MR, Auffarth GU, et al. Effect of Healon5 and 4 other viscoelastic substances on intraocular pressure and endothelium after cataract surgery. J Cataract Refract Surg. 2001;27:213-218. doi.org/10.1016/S0886-3350(00)00568-X
7. Maár N, Graebe A, Schild G, et al. Influence of viscoelastic substances used in cataract surgery on corneal metabolism and endothelial morphology: comparison of Healon and Viscoat. J Cataract Refract Surg. 2001;27:1756-1761. doi.org/10.1016/S0886-3350(01)00985-3
8. Auffarth GU, Auerbach FN, Rabsilber T, et al. Comparison of the performance and safety of 2 ophthalmic viscosurgical devices in cataract surgery. J Cataract Refract Surg. 2017;43:87-94. doi.org/10.1016/J.JCRS.2016.10.025
9. Papaconstantinou D, Karmiris T, Diagourtas A, et al. Clinical trial evaluating Viscoat and Visthesia ophthalmic viscosurgical devices in corneal endothelial loss after cataract extraction and intraocular lens implantation. Cutan Ocul Toxicol. 2014;33:173-180. doi.org/10.3109/15569527.2013.845835
10. Holzer MP, Tetz MR, Auffarth GU, et al. Effect of healon5 and 4 other viscoelastic substances on intraocular pressure and endothelium after cataract surgery. J Cataract Refract Surg. 2001;27:213-218. doi.org/10.1016/S0886-3350(00)00568-X
11. Praveen MR, Koul A, Vasavada AR, et al. DisCoVisc versus the soft-shell technique using Viscoat and Provisc in phacoemulsification: Randomized clinical trial. J Cataract Refract Surg 2008;34:1145-1151. doi.org/10.1016/J.JCRS.2008.03.019
12. Wood K, Pessach Y, Kovalyuk N, et al. Corneal endothelial cell loss and intraocular pressure following phacoemulsification using a new viscous-cohesive ophthalmic viscosurgical device. Int Ophthalmol. 2024;44:10. doi.org/10.1007/S10792-024-02997-Y
13. Arshinoff SA, Wong E. Understanding, retaining, and removing dispersive and pseudodispersive ophthalmic viscosurgical devices. J Cataract Refract Surg. 2003;29:2318-2323. doi.org/10.1016/j.jcrs.2003.09.045
14. Oshika T, Okamoto F, Kaji Y, et al. Retention and removal of a new viscous dispersive ophthalmic viscosurgical device during cataract surgery in animal eyes. Br J Ophthalmol 2006;90:485-487. doi.org/10.1136/BJO.2005.085969
15. Munk SJ, Heegaard S, Mosbech H, et al. Two episodes of anaphylaxis following exposure to hydroxypropyl methylcellulose during cataract surgery. J Cataract Refract Surg. 2013;39:948-951. doi.org/10.1016/J.JCRS.2013.02.034
16. Ucm R, Aem M, Lhb Z, et al. Comprehensive review on biotechnological production of hyaluronic acid: status, innovation, market and applications. Bioengineered. 2022;13(4):9645-9661. doi.org/10.1080/21655979.2022.2057760
17. Rayner. rayner.com/en/ovd/ophteisbio/ 2024.
18. Johnson & Johnson Vision. www.accessdata.fda.gov/cdrh_docs/pdf11/P110007c.pdf 2024
19. Yildirim TM, Auffarth GU, Son HS, et al. Dispersive viscosurgical devices demonstrate greater efficacy in protecting corneal endothelium in vitro. BMJ Open Ophthalmol. 2019;4:227. doi.org/10.1136/BMJOPHTH-2018-000227
20. Wüst M, Matten P, Nenning M, et al. Thickness of the Protective Layers of Different Ophthalmic Viscosurgical Devices During Lens Surgery in a Porcine Model. Transl Vis Sci Technol. 2022 Feb 1;11(2):28. doi.org/10.1167/tvst.11.2.28
21. Kretz FTA, Limberger IJ, Auffarth GU. Corneal endothelial cell coating during phacoemulsification using a new dispersive hyaluronic acid ophthalmic viscosurgical device. J Cataract Refract Surg. 2014;40:1879-1884. doi.org/10.1016/J.JCRS.2014.04.025
22. Karaca C, Ozkose M, Unlu M, et al. Comparison of corneal wetting properties of different dispersive ophthalmic viscosurgical devices. Retina. 2018;38:2137-2142. doi.org/10.1097/IAE.0000000000001854
23. Bourne WM. Biology of the corneal endothelium in health and disease. Eye (Lond). 2003;17:912-918. doi.org/10.1038/SJ.EYE.6700559
24. Malvankar-Mehta MS, Fu A, Subramanian Y, et al. Impact of Ophthalmic Viscosurgical Devices in Cataract Surgery. J Ophthalmol. 2020;2020:7801093. doi.org/10.1155/2020/7801093
25. Storr-Paulsen A, Nørregaard JC, Farik G, et al. The influence of viscoelastic substances on the corneal endothelial cell population during cataract surgery: A prospective study of cohesive and dispersive viscoelastics. Acta Ophthalmol Scand. 2007;85:183-187. doi.org/10.1111/J.1600-0420.2006.00784.X
26. Rhee DJ. Intraocular pressure trends aftersupranormal pressurization to aid closure of sutureless cataract wounds. J Cataract Refract Surg. 1999;25:546-549. doi.org/10.1016/S0886-3350(99)80053-4
27. Wang SY, Azad AD, Lin SC, et al. Intraocular Pressure Changes after Cataract Surgery in Patients with and without Glaucoma: An Informatics-Based Approach. Ophthalmol Glaucoma. 2020;3:343-349. doi.org/10.1016/J.OGLA.2020.06.002
28. Ling JD, Bell NP. Role of Cataract Surgery in the Management of Glaucoma. Int Ophthalmol Clin 2018;58:87. doi.org/10.1097/IIO.0000000000000234
29. Mansberger SL, Gordon MO, Jampel H, et al. Reduction in intraocular pressure after cataract extraction: the Ocular Hypertension Treatment Study. Ophthalmology. 2012;119:1826. doi.org/10.1016/J.OPHTHA.2012.02.050

30. Storr-Paulsen A, Nørregaard JC, Farik G, et al. The influence of viscoelastic substances on the corneal endothelial cell population during cataract surgery: A prospective study of cohesive and dispersive viscoelastics. Acta Ophthalmol Scand. 2007;85:183-187. doi.org/10.1111/j.1600-0420.2006.00784.x
31. Zetterström C, Laurell CG. Comparison of endothelial cell loss and phacoemulsification energy during endocapsular phacoemulsification surgery. J Cataract Refract Surg. 1995;21:55-58. doi.org/10.1016/S0886-3350(13)80480-4
32. Ventura S, Wälti R, Böhnke M. Corneal thickness and endothelial density before and after cataract surgery. Br J Ophthalmo.l 2001;85:18-20. doi: 10.1136/bjo.85.1.18
33. Duman R, Tok Çevik M, Görkem Çevik S, et al. Corneal endothelial cell density in healthy Caucasian population. Saudi J Ophthalmol. 2016;30:236. doi.org/10.1016/J.SJOPT.2016.10.003
34. Vaiciuliene R, Rylskyte N, Baguzyte G, et al. Risk factors for fluctuations in corneal endothelial cell density (Review). Exp Ther Med. 2022;23:129. doi.org/10.3892/ETM.2021.11052
35. Oshika T, Okamoto F, Kaji Y, et al. Retention and removal of a new viscous dispersive ophthalmic viscosurgical device during cataract surgery in animal eyes. Brit J Ophthalmol. 2006;90:485-487. doi.org/10.1136/BJO.2005.085969