Transfoveal Subthreshold Laser for the Treatment of Central Serous Chorioretinopathy: Efficacy and Safety According to Titrated-Fluence

Turizo-Mejía Sara[1,2], Restrepo-Velásquez Sarita[1,2], Quintero-Lizcano Karol[1,2], Pérez-Pérez Sara Margarita[1,2], Arango-Hurtado Mauricio[1,2]

[1]CES University, Medellín, Colombia
[2]Clínica Clofán, Medellín, Colombia



First author:
Sara Turizo-Mejía, MD

Submitted to the editorial board: June 16, 2026
Accepted for publication: July 30, 2026
Available on-line: November 11, 2026
https://doi.org/10.31348/2026/41

This manuscript has not been published previously and is not under consideration for publication elsewhere. The authors declare no conflicts of interest related with commercial influence.

Corresponding author:
Mauricio Arango-Hurtado
Clofán Clinic, Cra 48 #19A–40, Office 1715
Medellín, Postal Code: 050021
Colombia
E-mail: arangohurtado@gmail.com

SUMMARY

Aim: To evaluate the anatomical and functional outcomes of titrated-fluence-based, transfoveal subthreshold micropulse laser in patients with acute and chronic central serous chorioretinopathy (CSC).
Materials and Methods: Secondary data from patients with acute or chronic CSC treated between June 2021 and December 2024 were analyzed. All patients underwent transfoveal 577-nm subthreshold micropulse titrated-fluence-based laser. Optical coherence tomography (OCT) was performed at baseline, 4 weeks post-treatment, and at 6 months. The primary outcome was subretinal fluid (SRF) resolution after the first laser session. Secondary outcomes included best-corrected visual acuity (BCVA), final SRF resolution rate, recurrence, and treatment-related adverse effects.
Results: Twenty eyes of 18 patients were included. Median fluence ranged from 16.98–33.95 J/cm^2 (median 22.64 J/cm^2), with a median number of 343 spots (206–568 interquartile range). Complete SRF resolution after the first session occurred in 75% of eyes; final resorption was achieved in 80% with a statistically significant difference between the acute and chronic groups at 6 months ($p = 0.007$). Median BCVA improved from 0.3 logMAR at baseline to 0.2 logMAR at 4 weeks and remained stable at 0.2 logMAR at the final follow-up ($p = 0.027$). No adverse effects were observed.
Conclusion: Transfoveal subthreshold micropulse laser appears to be a safe and effective treatment modality for acute and chronic CSC. Fluence titration may contribute to improved clinical outcomes and may assist in optimizing treatment parameters.
Key words: central serous chorioretinopathy; subthreshold micropulse laser; fluence; optical coherence tomography

Čes. a slov. Oftal., 82, 2026, No. x, p.

INTRODUCTION

Central serous chorioretinopathy (CSC) is classified within the pachychoroid disease spectrum and is characterized by irregularities in the retinal pigment epithelium (RPE) and the accumulation of subretinal fluid (SRF) [1]. Although its pathogenesis is not yet fully defined, it is believed that choroidal alterations and vascular congestion play a fundamental role in its pathophysiology. The most common symptoms of CSC include blurred vision, metamorphopsia, micropsia, relative central scotoma, and dyschromatopsia. This condition is usually unilateral, primarily affects young and middle-aged adults (between 25 and 50 years old), and has a higher incidence in men [2]. In most cases, it has a favorable prognosis, with spontaneous resolution of SRF in 50 to 80% of patients within the first few months [3].

CSC has historically been classified as acute or chronic. However, there is no general consensus regarding the exact definitions. Acute CSC is characterized by spontaneous resolution of SRF within 3 to 6 months, with complete visual recovery in most patients [3]. Nevertheless, several studies have reported persistent deterioration of photoreceptor integrity and visual function (evidenced by reduced contrast sensitivity and microperimetry findings), even after SRF resolution over a relatively short period [3,4]. Recurrence rates can vary between 33% and 50%. In contrast, chronic CSC is defined by the persistence

of SRF for more than 6 months and is associated with progressive structural changes of the RPE and outer retina, potentially leading to irreversible visual dysfunction [1,5].

In order to achieve SRF resolution, various therapeutic strategies have been developed, including low-dose/medium-fluence photodynamic therapy (PDT), focal laser photocoagulation, oral treatment with mineralocorticoid receptor antagonists (spironolactone/eplerenone) and subthreshold micropulse laser (STML) [6–9]. Traditionally, a 4- to 6-month observation period has been recommended to allow for spontaneous resolution before initiating invasive treatment, given that CSC resolves spontaneously in a substantial proportion of patients [10]. The use of oral mineralocorticoid receptor inhibitors has not been shown to be superior to placebo, while focal laser photocoagulation (which always requires prior fluorescein angiography) should only be used in cases where the leakage point is away from the foveal center [10,11]. On the other hand, PDT can be applied even to the central macula and is considered as first-line therapy because of its superior rates of complete SRF resolution. Nevertheless, its availability remains limited worldwide [6]. In contrast, STML is widely available and cost-effective, but there is no clear consensus on the optimal fluence or the specific parameters for subfoveal application. When direct treatment on the fovea is necessary, careful control of laser power and precise delivery are essential to ensure safety, minimize the risk of retinal damage, and maximize both functional and anatomical outcomes. In addition, treatment response may vary according to whether the treatment targets acute or chronic forms [12].

As previously discussed, observation is generally preferred in patients with acute CSC, because of the self-limiting nature of this condition [10]. Nevertheless, some studies have suggested that treatment with STML may shorten the duration of acute CSC, potentially preventing progression to chronic disease while accelerating visual recovery and reducing the risk of recurrences and functional sequelae [4,5,13]. In contrast, in chronic CSC, anatomical improvement following STML may not translate into meaningful gains in visual acuity, as prolonged SRF duration can lead to irreversible photoreceptor damage and atrophy of the underlying RPE [6,10].

This study aims to evaluate the anatomical and functional outcomes of transfoveal STML treatment in patients with acute and chronic CSC. We analyzed how early intervention, combined with the use of standardized fluence parameters, impacts long-term outcomes.

MATERIAL AND METHODS

Study Design

A retrospective, observational cohort study from secondary sources was conducted from June 2021 to December 2024 at an Ophthalmology Clinic. The study was approved by the Ethics Committee of both the Clofan Clinic and the Institutional Review Board (IRB) of the CES University (Ref approved 2025). IRB reviewed the protocol and granted an exemption from formal protocol numbering, given the retrospective and anonymous nature of the data collection. The researchers adhered to the Declaration of Helsinki. All included patients provided signed informed consent to participate in the study.

Inclusion and Exclusion Criteria

Eligible patients had a diagnosis of acute or chronic CSC with subfoveal neurosensory retinal detachment, confirmed by optical coherence tomography (OCT). Acute CSC was defined as the presence of SRF for less than 3 months, whereas chronic CSC was defined as SRF persisting for more than 3 months. SRF duration was determined based on the onset of visual symptoms. All eyes underwent treatment with high-density subthreshold micropulse 577-nm laser, including transfoveal application and had a minimum follow-up of 6 months.

Exclusion criteria included patients with any documented pre-existing macular or retinal conditions, such as age-related macular degeneration, pachychoroidal neovascularization, polypoidal choroidal vasculopathy, intraocular tumors, posterior scleritis, optic disc pit maculopathy, or inflammatory processes such as Vogt–Koyanagi–Harada disease. When necessary, multimodal imaging, including fluorescein angiography (FA), ocular ultrasonography, and optical coherence tomography angiography (OCT-A), was performed to rule out coexisting retinal pathologies. In particular, when a neovascular complex was suspected at the initial visit, macular OCT-A (Optovue Solix; Optovue, Inc.) was performed. If a neovascular membrane was confirmed, the patient was excluded and treated accordingly.

Data Collection and Follow-up

Demographic information, including age, gender, laterality, refraction, time of symptom onset, best-corrected visual acuity (BCVA) at diagnosis, at 4 weeks post-treatment, and at the end of follow-up, was recorded. In addition, the parameters used for STML were documented (number of spots, size, power, duration, and fluence value per patient) (Table 1). All patients underwent a complete ophthalmological examination, and SD-OCT imaging (Optovue Solix - Optovue, Inc.; or Cirrus 5000 - Zeiss) at baseline, 4 weeks post-procedure, and at 6 months. In patients diagnosed with chronic CSC, ultra-widefield green autofluorescence imaging (California Optomap, Optos) was performed, to rule out RPE damage or outer retinal changes related to chronicity.

Procedure Description

Following the diagnosis of CSC, patients with symptoms persisting for more than 4 weeks underwent treatment with a 577-nm subthreshold micropulse laser (EasyRet, Quantel Medical) within one week. In patients with a symptom duration of less than 1 month, follow-up OCT was performed after 4 weeks; if persistent SRF was

Table 1. Laser treatment parameters in the overall cohort and according to acute or chronic central serous chorioretinopathy. Power, fluence, and number of spots are presented as median (interquartile range); the remaining parameters are presented as fixed treatment settings or number of eyes. The treatment area encompassed the entire region of subretinal fluid

Characteristics of parameters used			
	Overall	Acute	Chronic
Number of eyes (n)	20	7	13
Duty cycle (%)	5%	5%	5%
Spot size (µm)	160	160	160
Pulse duration (ms)	200	200	200
Area of treatment	Total area of subretinal fluid		
Power (mW) (IQR)	400 (350–438)	400 (400–500)	400 (350–425)
Fluence (J/cm^2) (IQR)	22.64 (19.81–24.76)	22.64 (22.64–28.29)	22.64 (19.81–24.05)
Number of spots (IQR)	343 (206–568)	359 (190–450)	328 (260–608)

CSC – central serous chorioretinopathy, IQR – interquartile range, n – number of eyes, µm – micrometers; ms – milliseconds, mW – milliwatts, J/cm^2 – joules per square centimeter

confirmed, STML treatment was subsequently initiated. All procedures were conducted using a Volk Area Centralis lens, which has a laser spot magnification factor of 0.94×, resulting in an effective retinal spot size of 160 µm for a 170-µm laser setting, and treatment parameters were individually tailored for each patient.

Titration power, defined as the minimum power required to elicit a barely visible retinal reaction in non-edematous tissue outside the macula, was first determined. This was achieved by initiating continuous-wave emission at 400 mW and increasing the power in 50-mW increments, relocating the aiming point each time, until a faint visible mark was observed. The laser was then switched to micropulse mode, and treatment was delivered at 50% of the titrated power. Importantly, the laser parameters: spot size (160 µm), duration (200 ms), and duty cycle (5%) remained constant for all patients and were never modified. Fluence (J/cm^2), defined as the energy delivered per unit area, is automatically calculated by the EasyRet and displayed at the bottom of the laser screen.

Laser application was guided by the OCT en face imaging, and direct clinical visualization of the area with SRF. These complementary strategies enabled precise delineation of the SRF area, ensuring that confluent, high-density micropulse spots were applied across the entire extent of the affected region. Eyes with persistent SRF at 4 to 6 weeks after the initial session underwent repeat micropulse laser treatment.

Statistical Analysis

A univariate analysis was performed for all demographic and clinical characteristics. Continuous data are reported as medians, while categorical variables are presented as frequencies and percentages. Changes in visual acuity were analyzed, using repeated-measures analysis of variance (ANOVA) with Bonferroni post-hoc correction. Subretinal fluid resolution was assessed, using the chi-square test. The database was constructed in Excel, and statistical analysis was conducted with SPSS software.

Purpose

The primary outcome of the study was the SRF resolution rate after the first laser session. Secondary outcomes included the change in BCVA after the first STML session and at final follow-up, the overall SRF resolution rate regardless of the number of sessions, and the occurrence of any procedure-related complications.

RESULTS

Baseline characteristics

Twenty eyes of 18 patients with acute or chronic CSC treated with transfoveal 577-nm subthreshold laser were included. Baseline demographic and clinical characteristics are summarized in Table 2. Most patients were male (83.3%, 15/18), with a median age of 42.5 years; 55% of treated eyes were left eyes (11/20), and 35% had acute CSC (7/20).

Table 2. Baseline characteristics of the complete cohort. Values are presented as median (range) or number/total number of available observations (%), unless otherwise indicated

Parameter	Value
Number of eyes	20
Median age in years (range)	42.5 (33–70)
Laterality	55% left (n = 11/20) 45% right (n = 9/20)
Mean follow-up in months (range)	6 (6–12)
Gender	83.3 % male (n = 15/18) 16.7% female (n = 3/18)
Acute CSC	35% (n = 7/20)
Chronic CSC	65% (n = 13/20)
Median total initial BCVA	0.3 LogMAR (0.2–0.6)
Median initial BCVA in acute CSC	0.3 LogMAR (0.1–0.4)
Median initial BCVA in chronic CSC	0.3 LogMAR (0.3–0.6)

CSC – central serous chorioretinopathy, BCVA – best-corrected visual acuity, logMAR – logarithm of the minimum angle of resolution

Laser parameters

During the procedure, power titration was performed in all patients, resulting in a fluence range of 16.98–33.95 J/cm^2 (median: 22.64 J/cm^2). The total number of spots varied according to the extent of SRF, overall with a median of 343 spots (206 - 568 IQR). The number of laser sessions varied according to disease duration. The average number of laser sessions was 1.1 in acute CSC and 1.5 in chronic CSC. Treatment parameters remained consistent across sessions, while the treatment area was adjusted, based on the location of the subretinal fluid.

Subretinal fluid resolution

The SRF resolution rate after the first laser session across both acute and chronic CSC was 75% (15/20). An additional 10% (2/20) showed partial improvement, and 15% (3/20) showed no improvement. The final SRF resolution rate, regardless of the number of sessions, was 80% (16/20). Three eyes (15%) demonstrated partial improvement, and one eye (5%) showed no SRF response. When stratified by presentation, eyes with acute CSC showed a more favorable response: 85% (6/7) achieved resolution after just one session (Figure 1**)**, while one eye underwent a second treatment due to persistent SRF at 4 weeks. The final resolution rate was 100% (7/7) at 6 months. In contrast, outcomes in chronic CSC (Figure 2) were more heterogeneous: 69.2% of eyes (9/13) improved after one session**,** 23% (3/13) required a second session (Figure 3), and 7.6% (1/13) ultimately received three sessions. Of the four eyes with persistent SRF at 6 months, three showed partial improvement, and one showed no SRF resolution with the third laser session – this patient rejected additional treatment. This pattern reflects the greater treatment burden typically observed in chronic cases**.** Statistical analysis demonstrated a significant difference in SRF resolution between the acute and chronic groups at 6 months (p=0.007).

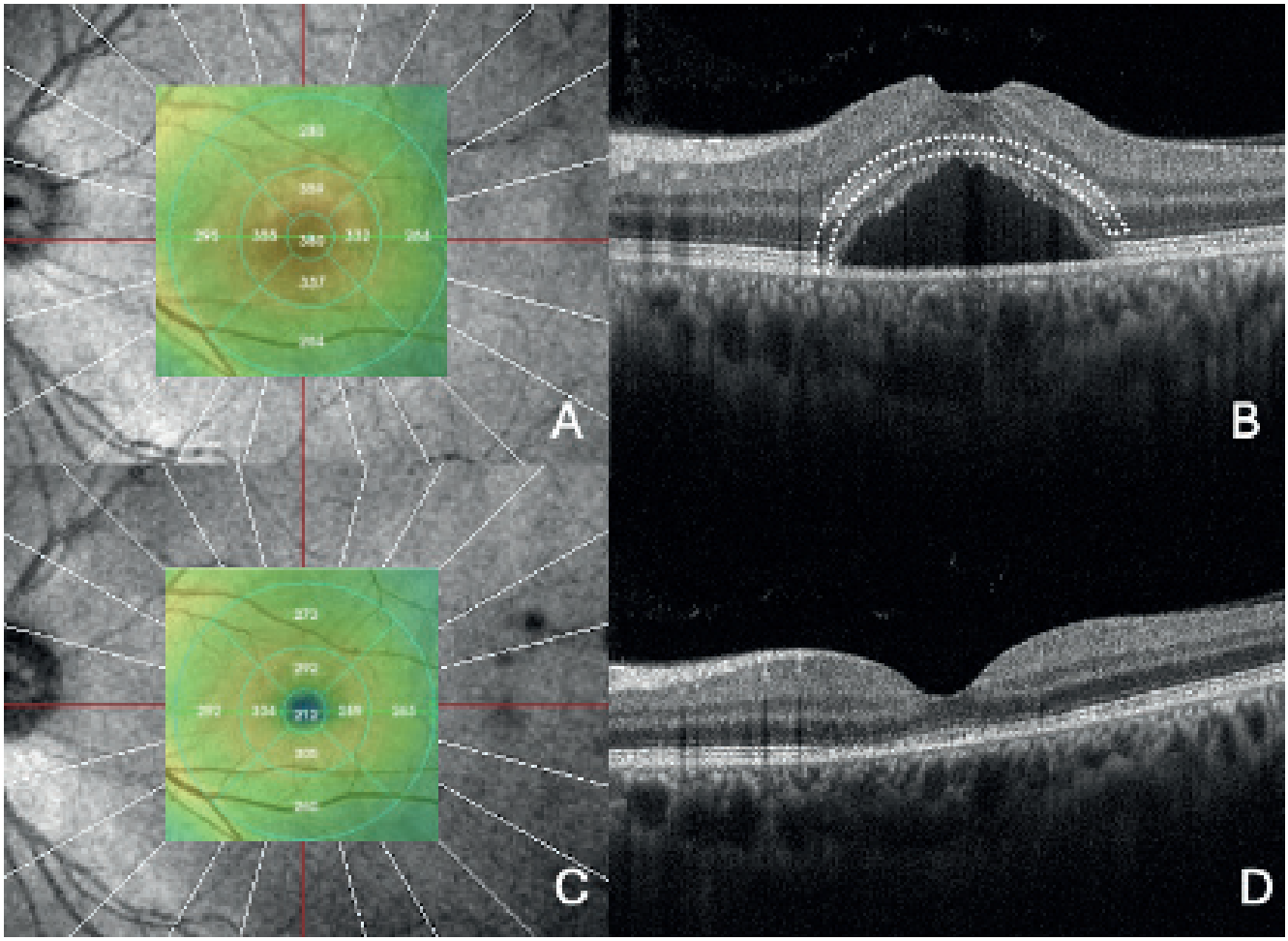

Figure 1. (**A, B**) Baseline imaging of a 38-year-old male with acute CSC. (**A**) The macular thickness map (ETDRS grid) overlaid on near-infrared reflectance imaging shows increased central macular thickness (380 µm) with diffuse parafoveal thickening. (**B**) Spectral-domain OCT demonstrates a subfoveal dome-shaped neurosensory retinal detachment delineated by white dotted lines. (**C, D**) Four-week follow-up after treatment. (**C**) A substantial reduction in central macular thickness to 212 µm is observed on the thickness map, corresponding to a 168 µm decrease from baseline. (**D**) The OCT B-scan shows complete resolution of subretinal fluid, with residual irregular and intermittent ellipsoid zone disruption

CSC – central serous chorioretinopathy

Visual Outcomes

The median baseline BCVA for the entire cohort was 0.3 logMAR. Eyes with acute CSC had a median baseline BCVA of 0.2 logMAR, whereas those with chronic CSC had a median baseline BCVA of 0.4 logMAR. Overall, median BCVA improved from 0.3 logMAR at baseline to 0.2 logMAR at 4 weeks and remained stable, reaching 0.2 logMAR at the final follow-up.

When analyzed by subgroups, the acute CSC group demonstrated improvement in median BCVA to 0.0 logMAR at 4 weeks, which was maintained at 6 months. In contrast, the chronic CSC group achieved a median BCVA of 0.3 logMAR at both 4 weeks and 6 months. Statistical analysis confirmed a significant difference between baseline and 6 months BCVA ($p = 0.027$).

Safety Outcomes

In this study, no adverse effects attributable to treatment were detected in any case, based on OCT and/or autofluorescence evaluation at the end of follow-up, including in patients who underwent multiple treatment sessions. No recurrences were reported during follow-up. However, this finding may reflect the relatively short duration of follow-up, rather than a true absence of recurrence. Longer-term monitoring is needed to accurately assess the risk of recurrent subretinal fluid in both acute and chronic CSC, as recurrences may develop beyond the timeframe of the current observation period.

DISCUSSION

Subthreshold micropulse laser has emerged as an effective, safe, and repeatable treatment option for CSC, targeting the RPE while avoiding thermal retinal damage. Its therapeutic effect relies on selective stimulation of the RPE by inducing the expression of heat shock proteins with anti-inflammatory and antiangiogenic properties. This response is achieved through the delivery of ultrashort, low-power laser pulses, alternated with cooling intervals that prevent heat accumulation, thereby minimizing the risk of retinal and RPE damage [1,14]. As a result, micropulse laser can be safely performed transfoveally without causing foveal injury [13]. These biological and safety characteristics translate into significant clinical advantages, as STML enhances RPE-mediated SRF reabsorption and allows safe subfoveal treatment. This is particularly important, given its detrimental impact on visual function.

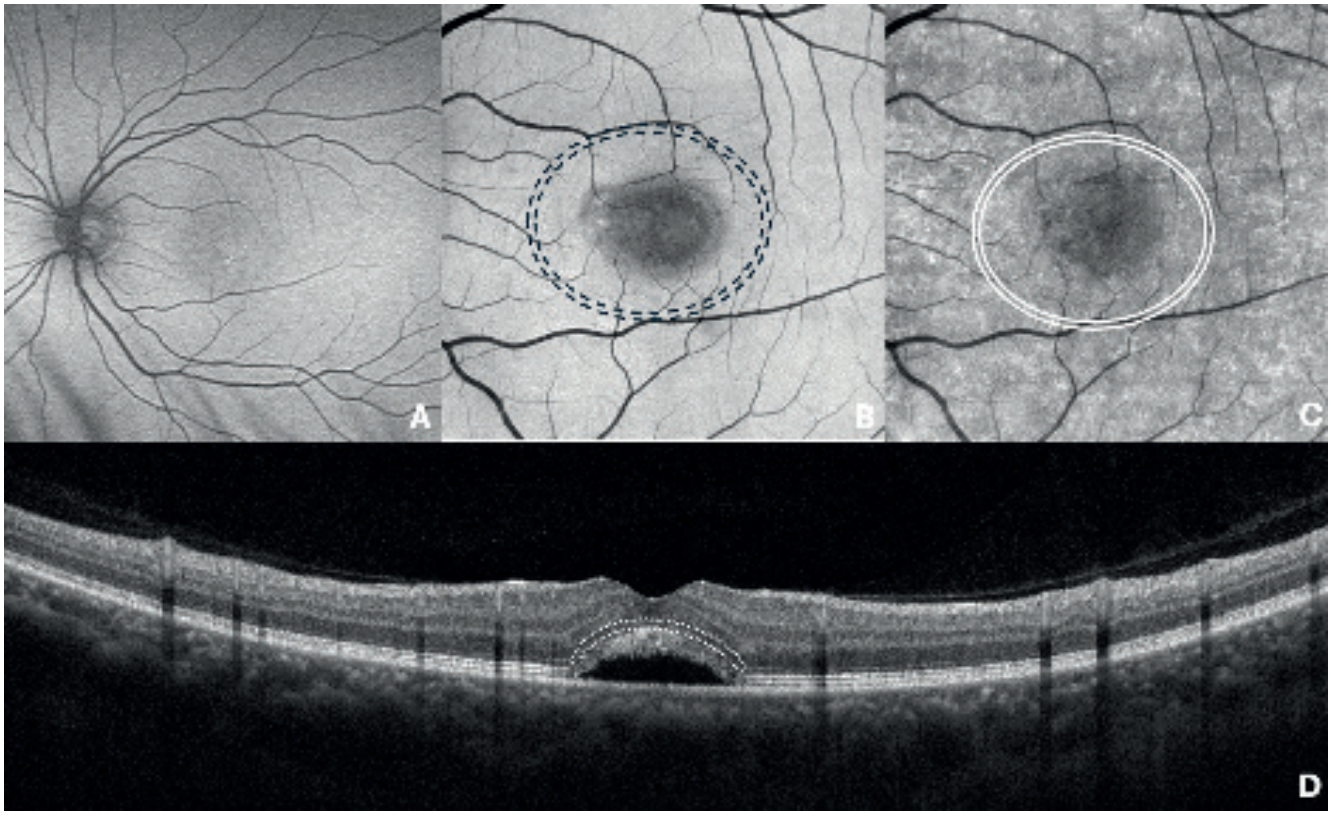

Figure 2. Baseline imaging of a 36-years old male patient who presented with a chronic CSC. (**A**) Fundus autofluorescence demonstrated subtle perifoveal hyperautofluorescent mottling. (**B**) Outer retinal en face SD-OCT projection showed a round area of hyporeflectivity corresponding to subretinal fluid (dotted lines). (**C**) Choriocapillaris en face OCT with a hyporeflective area (outlined by continuous white lines) corresponding to the distribution of SRF, surrounded by an otherwise unremarkable choriocapillaris. (**D**) OCT B-scan with evidence of a subfoveal neurosensory retinal detachment (white dots) and elongation of photoreceptors. Adequate segmentation was confirmed

CSC – central serous chorioretinopathy

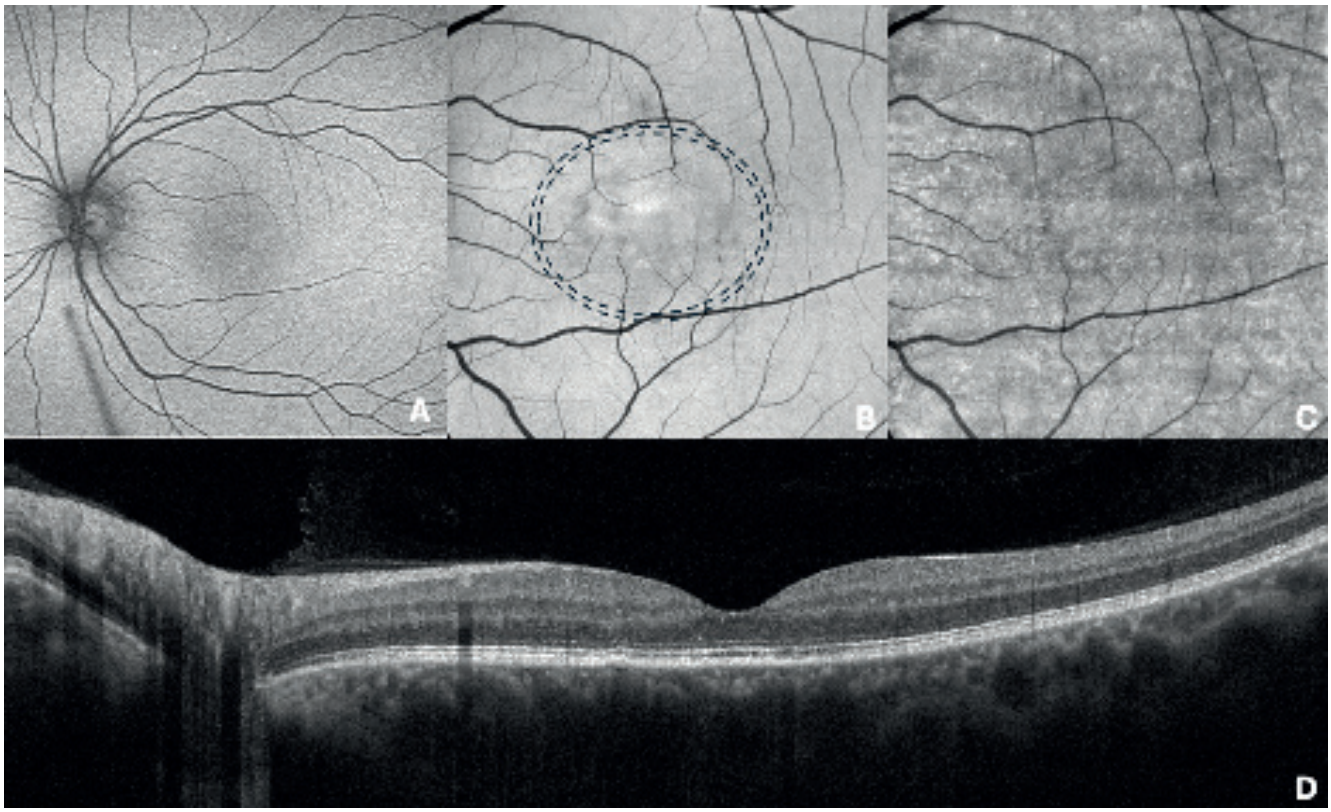

Figure 3. Post-treatment multimodal imaging of the same patient with chronic CSC following two sessions of subthreshold micropulse laser therapy. (**A**) Fundus autofluorescence revealed complete resolution of the hyperautofluorescent mottling previously described, without evidence of RPE damage after laser procedures. (**B**) Outer retinal en face OCT projection demonstrated a subtle area of central diffuse patchy hyperreflectivity surrounded by an irregular hyporeflective halo. (**C**) Choriocapillaris end face OCT showed mild parafoveal hyporeflectivity, with the remaining area exhibiting an irregular, granular hyperreflective pattern consistent with preserved choriocapillaris architecture with no bright lesions as indicative of hypertransmission defects. (**D**) Structural OCT B-scan confirmed complete resolution of the neurosensory retinal detachment. No evidence of RPE damage was observed, as indicated by the absence of hypertransmission. Adequate segmentation was confirmed

CSC – central serous chorioretinopathy, RPE – retinal pigment epithelium

Despite these advantages, the clinical efficacy and safety of STML are highly dependent on precise fluence control, which is essential to achieve an adequate biological response while avoiding overtreatment. In this context, our study adds to the growing body of evidence supporting STML as a valuable therapeutic modality for CSC and highlights fluence titration and transfoveal treatment as critical determinants of success [1]. Setting the correct laser power is a key aspect of STML therapy. Two main strategies have been described: individualized titration and fixed low-power settings [13]. Individualized parameter selection has been suggested, given variations in RPE pigmentation, optical media clarity and device-specific characteristics. Additionally, inadequate fluence or an insufficient number of laser spots may lead to undertreatment, which remains a recognized limitation of micropulse therapy. Consequently, meticulous fluence titration, combined with careful OCT-guided treatment planning, are essential to achieve optimal anatomical and functional outcomes [15,16].

To evaluate the effectiveness of our titrated-fluence protocol, we analyzed outcomes in a cohort of 20 eyes treated with transfoveal STML. Complete SRF resolution was achieved in 15 eyes (75%), partial improvement in 4 eyes (20%) and one eye (5%) showed no SRF response at 4 weeks. At final follow-up, complete SRF resolution was observed in 16 eyes (80%), regardless of the number of treatment sessions, highlighting the clinical efficacy of individualized fluence titration. In cases of persistent SRF, treatment was repeated, using the same initial parameters without increasing the risk of adverse events. Overall, these results are consistent with previous reports by Abd Elhamid et al. and Lanzetta et al., who reported SRF resolution rates of 67–75% at 1 month and 75–85% at 6 months [17,18]. Notably, all patients in our study demonstrated some degree of visual improvement, even in the presence of persistent SRF.

In our study, fluence values ranged from 16.98 to 33.95 J/cm^2, with no evidence of retinal injury on OCT cross-sectional imaging, en face OCT, or fundus autofluorescence. This was even when slightly exceeding the safety range recommended by A. Filloy at EURETINA 2025 (12–20 J/cm^2), highlighting the importance of individualized fluence titration [15]. Although there is no consensus

on the optimal degree of power reduction after titration, most authors recommend a 50% reduction, which reduces the risk of overtreatment while avoiding undertreatment commonly associated with fixed settings [15,16]. Photodynamic therapy remains the most consistently effective treatment. However, its limited availability reinforces the role of STML as a highly effective alternative.

Accurate delivery of STML and monitoring of treatment response depend heavily on advanced imaging modalities. OCT-guided treatment, particularly using en face OCT, enhances laser precision, optimizes efficacy, and allows continuous, noninvasive assessment of therapeutic outcomes [1,10,19]. En face OCT provides direct visualization of SRF, which typically appears as a circular hyporeflective area, enabling accurate delineation of fluid distribution and more precise guidance of STML therapy.

During follow-up, OCT cross-sectional and en face imaging proved valuable for detecting potential secondary structural alterations [3,12]. Although fundus autofluorescence (FAF) has traditionally been used to assess SRF accumulation and RPE damage, hyperautofluorescent signals from SRF can interfere with accurate evaluation of underlying RPE changes. In contrast, en face OCT provides a reliable method for visualizing and quantifying both SRF and RPE alterations. On en face OCT imaging, SRF appears as circular or disc-shaped hyporeflective lesions, whereas RPE changes present as punctiform hyperreflective signals, facilitating differentiation between fluid accumulation and true RPE damage [20]. Accordingly, the first follow-up visit was scheduled 4 – 6 weeks after STML treatment and included OCT imaging with en face acquisition to confirm SRF resolution and identify RPE alterations. Consistent with Chhablani et al., we observed no structural damage on OCT B-scan, en face OCT, or FAF, supporting the safety of transfoveal STML when strict individualized titration and controlled parameters are applied [12].

Although the optimal timing for CSC treatment remains debatable, emerging evidence suggests that traditional conservative approaches may require reconsideration. Acute CSC has been shown to cause lasting structural and functional retinal changes, challenging its previously assumed benign and self-limiting nature [4,13]. Funatsu et al. demonstrated that even brief persistence of subretinal fluid (1–2 months) can induce measurable thinning of the outer nuclear layer, with time to treatment identified as the primary contributing factor [21]. While this thinning did not adversely affect post-treatment outcomes, it underscores that retinal alterations may occur earlier than traditionally recognized.

Clinical outcomes in CSC strongly correlate with disease duration. Earlier intervention has been associated with higher SRF resolution rates, greater visual improvement, lower recurrence, better visual function and fewer outer retinal and RPE alterations, as reported by Kiraly et al. and Arora et al. [3,4]. Although STML can restore retinal architecture in many cases, functional recovery is often limited in chronic disease, further emphasizing the importance of timely treatment [13,14]. Therefore, even considering the possibility of spontaneous resolution, initiating therapy after 4 weeks of persistent SRF may improve long-term anatomical and functional outcomes and reduce the risk of progression to chronic CSC and irreversible visual impairment. This approach aligns with Subthreshold Laser Ophthalmic Society (SOLS) guidelines, which recommend treatment for acute CSC when SRF persists beyond 4 weeks [3,4,14]. Consistent with these observations, our cohort demonstrated a statistically significant difference ($p = 0.007$) for SRF resolution rates at 6 months in the acute CSC group, compared with chronic cases; this difference supports the concept that earlier intervention may enhance anatomical outcomes and reinforces the clinical relevance of timely STML application.

Regarding complications, in our study, no adverse effects attributable to STML were observed in any patient, including those who underwent multiple treatment sessions, as confirmed by OCT and fundus autofluorescence evaluation at the end of follow-up. Moreover, no recurrences of SRF were detected during the study period. However, these findings may reflect the relatively short duration of follow-up, rather than a true absence of recurrence, as SRF can reappear beyond the timeframe of observation. Longer-term monitoring is therefore warranted to fully assess the risk of recurrence and to confirm the sustained safety of STML in both acute and chronic CSC.

In summary, our findings provide real-world evidence that careful fluence titration, guided by OCT and advanced imaging modalities such as en face OCT, allows precise and safe delivery of transfoveal STML, achieving high rates of anatomical success without inducing retinal damage. This supports the role of STML as a minimally invasive, retina-sparing therapeutic option for CSC, with the potential to improve visual outcomes while minimizing treatment-related risks. Collectively, these results reinforce the clinical relevance of individualized, imaging-guided STML protocols and underscore their value as an effective alternative to more invasive therapies, particularly in cases involving subfoveal fluid.

This study has several limitations that should be considered when interpreting the results. The relatively small sample size of 20 eyes of 18 patients limits statistical power and external validity. The retrospective and observational design may introduce selection and reporting biases, as treatment decisions were not randomized and follow-up intervals varied slightly among patients. In addition, no formal inferential statistical analyses were performed to compare outcomes between acute and chronic CSC, limiting definitive conclusions regarding subgroup differences. Finally, the 6-month follow-up period may not capture long-term recurrences or delayed adverse effects, highlighting the need for larger, prospective studies with extended follow-up.

CONCLUSION

Transfoveal subthreshold micropulse laser may represent an effective and safe treatment for CSC. Its efficacy relies on precise fluence titration and accurate macular OCT guidance to ensure complete and confluent coverage of the affected area, optimizing SRF resolution. Based on our findings and the absence of significant adverse effects, STML could represent an extremely suitable therapeutic option for patients with CSC and may be considered even in the early stages of the disease to potentially improve long-term anatomical and functional outcomes.

Statement of Ethics

Authorization and signed informed consent were obtained from the patients and the Institution's Ethics Committee. The research adhered to the principles of the Declaration of Helsinki. This is an observational study.

REFERENCES

1. Van Dijk E, Boon C. Serous business: delineating the broad spectrum of diseases with subretinal fluid in the macula. Prog Retin Eye Res. 2021;84:100955. https://doi.org/10.1016/j.preteyeres.2021.100955
2. Li X, Long H, Hu Q. Efficacy of subthreshold micropulse laser for chronic central serous chorioretinopathy: a meta-analysis. Photodiagnosis Photodyn Ther. 2022;39:102931. https://doi.org/10.1016/j.pdpdt.2022.102931
3. Kiraly P, Habjan M, Smrekar J, Mekjavić P. Functional outcomes and safety profile of transfoveal subthreshold micropulse laser in persistent central serous chorioretinopathy. Life (Basel). 2023;13(5):1194. https://doi.org/10.3390/life13051194
4. Arora S, Sridharan P, Arora T, Chhabra M, Ghosh B. Subthreshold diode micropulse laser versus observation in acute central serous chorioretinopathy. Clin Exp Optom. 2019;102(1):79-85. https://doi.org/10.1111/cxo.12818
5. Long H, Liu M, Hu Q, Li X. 577-nm subthreshold micropulse laser treatment for acute central serous chorioretinopathy: a comparative study. BMC Ophthalmol. 2022;22(1):105. https://doi.org/10.1186/s12886-022-02330-0
6. Van Dijk E, Fauser S, Breukink M, et al. Half-dose photodynamic therapy versus high-density subthreshold micropulse laser treatment in chronic central serous chorioretinopathy: the PLACE trial. Ophthalmology. 2018;125(10):1547-1555. https://doi.org/10.1016/j.ophtha.2018.04.021
7. Robertson D, Ilstrup D. Direct, indirect, and sham laser photocoagulation in the management of central serous chorioretinopathy. Am J Ophthalmol. 1983;95(4):457-466. https://doi.org/10.1016/0002-9394(83)90265-9
8. Bousquet E, Zhao M, Daruich A, Behar-Cohen F. Mineralocorticoid antagonists in the treatment of central serous chorioretinopathy. Exp Eye Res. 2019;187:107754. https://doi.org/10.1016/j.exer.2019.107754
9. Scholz P, Altay L, Fauser S. A review of subthreshold micropulse laser for treatment of macular disorders. Adv Ther. 2017;34(7):1528-1555. https://doi.org/10.1007/s12325-017-0559-y
10. Van Rijssen T, van Dijk E, Yzer S, et al. Central serous chorioretinopathy: towards an evidence-based treatment guideline. Prog Retin Eye Res. 2019;73:100770. https://doi.org/10.1016/j.preteyeres.2019.07.003
11. Lotery A, Sivaprasad S, O'Connell A, et al. Eplerenone for chronic central serous chorioretinopathy (VICI): a randomized controlled trial. Lancet. 2020;395(10220):294-303. https://doi.org/10.1016/S0140-6736(19)32981-2
12. Chhablani J, Kalra G, Alkwatli L, et al. Safety of various parameter sets with navigated microsecond pulsing laser in central serous chorioretinopathy. Int J Retina Vitreous. 2021;7(1):62. https://doi.org/10.1186/s40942-021-00335-3
13. Gawęcki M, Jaszczuk-Maciejewska A, Jurska-Jaśko A, Kneba M, Grzybowski A. Transfoveal micropulse laser treatment of central serous chorioretinopathy within six months of disease onset. J Clin Med. 2019;8(9):1398. https://doi.org/10.3390/jcm8091398
14. Gawęcki M. Micropulse laser treatment of retinal diseases. J Clin Med. 2019;8(2):242. https://doi.org/10.3390/jcm8020242
15. Keunen J, Battaglia-Parodi M, Vujosevic S, Luttrull J. International Retinal Laser Society guidelines for subthreshold laser treatment. Transl Vis Sci Technol. 2020;9(9):15. https://doi.org/10.1167/tvst.9.9.15
16. Abd Elhamid A. Subthreshold micropulse yellow laser treatment for nonresolving central serous chorioretinopathy. Clin Ophthalmol. 2015;9:2277-2283. https://doi.org/10.2147/OPTH.S87499
17. Zhang Z, Deng C, Duan J, et al. The role of en face imaging of retinal pigment epithelium alterations in rapid classification of central serous chorioretinopathy using widefield swept-source optical coherence tomography. Retina. 2026;46(2):373-382. https://doi.org/10.1097/IAE.0000000000004693
18. Maltsev D, Kulikov A, Burnasheva M, Chhablani J. En face OCT transillumination for evaluation of retinal pigment epithelium alteration in central serous chorioretinopathy. Graefes Arch Clin Exp Ophthalmol. 2022;260(7):2231-2237. https://doi.org/10.1007/s00417-021-05537-x
19. Funatsu R, Mihara N, Miyake S, et al. Subretinal fluid duration and clinical outcomes in central serous chorioretinopathy: an analysis of time-to-photodynamic therapy. Am J Ophthalmol. 2026;283:7-13. https://doi.org/10.1016/j.ajo.2025.11.039
20. Lanzetta P, Furlan F, Morgante L, Veritti D, Bandello F. Nonvisible subthreshold micropulse diode laser treatment of central serous chorioretinopathy. Eur J Ophthalmol. 2008;18(6):934-940. https://doi.org/10.1177/112067210801800613
21. Chhablani J, SOLS Writing Committee. Subthreshold laser therapy guidelines for retinal diseases. Eye (Lond). 2022;36(12):2234-2235. https://doi.org/10.1038/s41433-022-02136-w