

# Clinical Results Following the Implantation of a New Toric Intraocular Lens with Extended Depth of Focus

Jančárová Simona<sup>1</sup>, Němcová Marie<sup>1</sup>, Rozsival Pavel<sup>1,2</sup>,  
Nováček Ladislav Viktor<sup>1</sup>

<sup>1</sup>Department of Ophthalmology, Institute of Aviation Medicine, Prague, Czech Republic

<sup>2</sup>Charles University, Faculty of Medicine in Hradec Králové, Department of Ophthalmology, University Hospital Hradec Králové, Czech Republic



MUDr. Simona Jančárová

Submitted to the editorial board: February 11, 2025

Accepted for publication: March 17, 2025

Available on-line: June 6, 2025

*The authors of the study declare that no conflict of interests exists in the compilation, theme and subsequent publication of this professional communication, and that it is not supported by any pharmaceuticals company. The study has not been submitted to any other journal or printed elsewhere.*

Correspondence address:

Ústav leteckého zdravotnictví Praha  
Generála Píky 1  
160 00 Praha  
Česká republika  
E-mail: js.simona@gmail.com

## SUMMARY

**Purpose:** To evaluate the clinical outcomes following the implantation of a new toric intraocular lens (TIOL) with extended depth of focus (EDOF) Bi-Flex ELON Toric POB-MA 877PETY (Elon<sup>®</sup>, MediconTur Medical Engineering Ltd., Zsámbék, Hungary), including analysis of lens rotational stability and assessment of patient satisfaction.

**Material and methods:** In a retrospective, monocentric clinical study, 29 eyes of 18 patients (11 men and 7 women) with presbyopia, cataracts, and corneal astigmatism were evaluated. These patients underwent uncomplicated cataract surgery with Bi-Flex ELON Toric TIOL implantation. Postoperative assessments included measurements of monocular uncorrected and corrected distance visual acuity (UDVA, CDVA) and near visual acuity (UNVA, CNVA), rotational stability of the TIOL, and subjective evaluation of visual quality using a questionnaire. Follow-up examinations were conducted 6 months postoperatively (ranging from 3 to 9 months).

**Results:** The mean postoperative monocular UDVA improved from  $0.4 \pm 0.2$  to  $0.90 \pm 0.1$  ( $p < 0.0001$ ). Average CDVA was  $1.0 \pm 0.2$ . All patients achieved monocular UDVA  $\geq 0.6$  and CDVA  $\geq 0.8$ . The average postoperative monocular UNVA was at Jaeger chart level 4, and CNVA reached Jaeger level 1 in all patients. The mean residual astigmatic refraction was  $-0.6 \pm 0.4$  Dcyl ( $p = 0.0003$ ), and the mean absolute rotational deviation was  $1.9 \pm 2.65^\circ$ . Patient satisfaction was assessed on a scale of 1 to 5, with an average score of 1.4. Targeted questioning revealed that halo-type dysphotopsia was reported in 52 % of eyes, glare-type in 17%, and no dysphotopsia in 31%.

**Conclusion:** Implantation of a Bi-Flex ELON Toric TIOL for correcting astigmatism and presbyopia significantly improved both distance and near visual acuity. The rotational stability of the lens was high, and the majority of patients achieved independence from wearing spectacles.

**Key words:** toric intraocular lens, extended depth of focus, IOL rotation, cataract

*Čes. a slov. Oftal., 82, 2026, No. 1, p. 35–40*

## INTRODUCTION

Implantation of an artificial intraocular lens (IOL) in patients with cataracts has become a standard treatment. Modern IOLs not only treat cataracts but also correct refractive errors [1]. Advances in optical biometry have enabled precise predictions of IOL power to correct both myopia and hyperopia. Corneal astigmatism, present in approximately 87% of cataract patients [2], can be corrected with the implantation of a toric IOL (TIOL) [3]. For presbyopic patients seeking independence from wearing spectacles, refractive lens exchange is now an option, using IOLs specifically designed to correct presbyopia.

IOLs are available in various optic designs. Monofocal IOLs are designed to provide optimal uncorrected visual acuity at a fixed distance, but require spectacles to achieve

sharp vision at other distances [4]. Implantation of a multifocal IOL ensures sharp vision at all distances [5], which increases independence from wearing spectacles [6,7]. However, these advantages come with certain compromises [8], including problems with neuroadaptation [9], dysphotopsias, and reduced contrast sensitivity [7–9].

The latest innovation in IOL technology is the extended depth of focus (EDOF) IOL [10], which operates on the principle of creating a single, continuous, elongated focal point [6,11], thereby enhancing the depth of focus of the lens. The primary goal of EDOF lenses is to strike a balanced compromise between monofocal and multifocal IOLs, providing better visual acuity at intermediate distances compared to monofocal IOLs, while simultaneously reducing the incidence and intensity of secondary optical phenomena and minimizing the impact on contrast sensitivity compared to multifocal IOLs [10].

According to the most recent data, EDOF IOLs are categorized into five types based on their optical design: Type 1 utilizes spherical aberrations to extend the depth of focus (DOF); Type 2 uses the pinhole effect; Type 3 is a multifocal IOL with a low addition for near vision; Type 4 is a hybrid IOL that combines spherical aberrations with a low addition for near vision; and Type 5 uses special geometry in the central optic region [11].

The IOL Bi-Flex ELON POB-MA 877PEY (Elon®, Medicon-tur Medical Engineering Ltd., Zsámbék, Hungary) uses patented wavefront linking technology and is classified as Type 5. With the correction of astigmatism, the recently introduced toric variant, Bi-Flex ELON Toric POB-MA 877PETY, achieves optimal visual results, fully leveraging the advantages of EDOF technology.

To the best of our knowledge, no reviewed study has been published to date that focuses on evaluating the clinical outcomes of the toric variant of the above IOL. In light of this, we decided to conduct a pilot retrospective study to assess the clinical results, including an analysis of rotational stability and subjective patient satisfaction.

## MATERIAL AND METHOD

A retrospective clinical trial evaluated preoperative and postoperative outcomes of patients with presbyopia and cataracts. All patients had preoperative corneal astigmatism of  $\geq 0.75$  D (keratometry value from TRK-2P, Topcon Corporation, Tokyo, Japan) and requested partial independence from wearing spectacles. The total cohort consisted of 18 patients, 11 of whom received a toric EDOF IOL in both eyes, while 7 patients had a toric EDOF IOL implanted in one eye and a non-toric EDOF IOL in the contralateral eye. All surgeries were performed by a single experienced surgeon (NLV) between January and September 2024. The patients were carefully selected based on predefined criteria. Exclusion criteria included irregular astigmatism, corneal pathology, congenital ocular defects, amblyopia, uveitis, glaucoma, ocular trauma, previous laser refractive surgery, and any other ocular conditions that could affect the surgical outcome. Only adult patients aged 18 years or older were included in the analysis. All participants were fully informed about the surgical procedure and the implanted TIOL, and each provided written informed consent in accordance with the Declaration of Helsinki.

### Preoperative and postoperative results

Before surgery, a comprehensive ocular examination was conducted. This included refractometry, keratometry, non-contact tonometry (TRK-2P, Topcon Corporation, Tokyo, Japan), and optical biometry to measure axial length (AXL), anterior chamber depth (ACD), and keratometry values (K1, K2) using the IOL Master 700 (Carl Zeiss Meditec AG, Jena, Germany). Corneal topography was assessed with the Oculus

Pentacam 70700 (OCULUS Optikgeräte GmbH, Wetzlar, Germany). The anterior and posterior segments of the eye were examined under pharmacologically induced mydriasis using a slit lamp (SL-D4, Topcon, Topcon Corporation, Tokyo, Japan). Additionally, spectral-domain OCT imaging (Spectralis OCT, Heidelberg Engineering, Heidelberg, Germany) was performed to exclude retinal pathology. Monocular uncorrected and corrected visual acuities (distance UDVA, CDVA, at 4m; near UNVA, CNVA at 40 cm) were measured using the SC-1600 Snellen Chart (Nidek Co., Ltd., Tokyo, Japan) and Jaeger Charts. (The results are presented in decimal values of Snellen Charts.) The diagnosis of cataract was determined based on an examination by slit lamp and subjective deterioration of the patients' visual acuity. A follow-up measurement was conducted at an interval of 3 to 9 months after surgery.

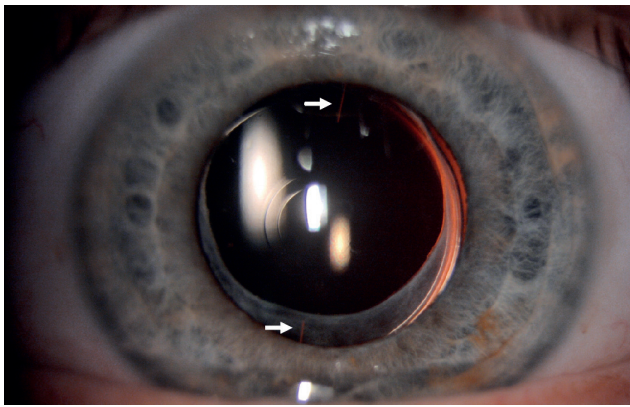
Rotational stability of the TIOL was evaluated by comparing its position at the postoperative follow-up examination with the originally planned surgical position. The angle of rotation was measured using beam inclination on the slit lamp after artificial mydriasis had been induced (Figure 1 and 2). The resulting value of rotation (in degrees) was expressed both as an absolute value and in relation to direction, with clockwise rotation considered negative and counterclockwise positive.

Visual function, quality of vision, and patient satisfaction following TIOL implantation were assessed using a questionnaire consisting of five questions. The questionnaire methodology was based on an evaluation published by Pašková et al. [12]. The questions were focused on the presence of photic phenomena and satisfaction with vision at various distances without correction. The responses were recorded on a scale of 1 to 5, with each score representing the following:

- 1 – satisfied, I have no complaints;
- 2 – satisfied, I have minor complaints that do not inconvenience me;
- 3 – not satisfied, I have complaints that inconvenience me;
- 4 – not satisfied, I have complaints that are unacceptable to me;
- 5 – explantation performed due to patient dissatisfaction.

### Intraocular lens

The Bi-Flex ELON Toric POB-MA is a single-piece aspherical TIOL produced from hydrophobic acrylate. It has a total diameter of 13 mm, with the optical part measuring 6 mm in diameter. In the center of the optical part is a refractive zone, ranging from 1.6 to 2.0 mm in diameter, featuring a special geometric layout. This zone contains a series of concentric refractive zones, varying in curvature, linked by specially designed linking zones. Wavefront linking distributes light energy continuously along the optical axis. The focal points are connected, creating a singular, elongated focus that is effective across the entire range of vision.




**Figure 1.** Postoperative image of an EDOF IOL with toricity markers indicated by arrows. A 2 mm wide refractive zone is observed in the central region of the intraocular lens  
*EDOF IOL – extended depth of focus intraocular lens*

Two toric markers are located on the optical part, indicating the axis of the TIOL. The lens haptics have zero angulation (0°). The patented 360° square-edge technology prevents the occurrence of posterior capsular opacification (PCO). The lens material has a refractive index of 1.47 and an Abbe number of 58. The lens is equipped with a UV blocker and blue light filter and is supplied as part of a preloaded injector system.

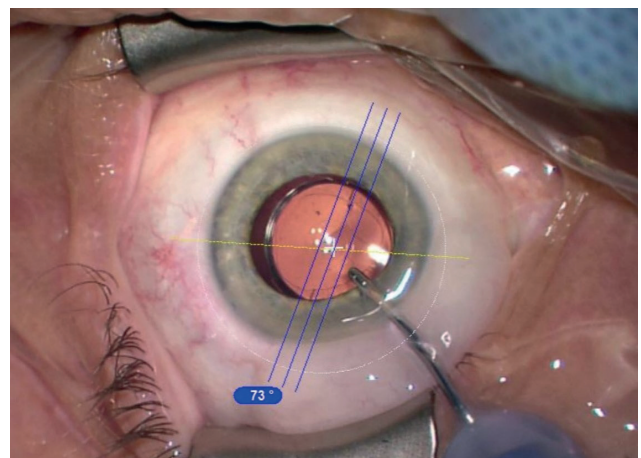
The manufacturer's online calculator was used to calculate a suitable TIOL (available at [www.toriccalculator.net](http://www.toriccalculator.net)). Target refraction was set to emmetropia, taking into account the surgically induced corneal astigmatism (0.25 D) and the location of the surgical incision. The optimal spherical equivalent (SE) and cylindrical power (CYL) of the TIOL were calculated using the Haigis formula. Astigmatism of the posterior surface of the cornea was also considered during optical biometry performed using the IOL Master 700.

### Surgical technique

After the application of local anesthesia and pupil dilation, a 2.2 mm corneal incision was made along an axis of 135°. The anterior chamber was filled with viscoelastic material, followed by continuous circular capsulorhexis. The opacified lens was then removed by phacoemulsification. Following irrigation and aspiration, the TIOLs were implanted within the capsular bag using the preloaded injector system POB-MA (Medicontur Ltd.). After the removal of the ophthalmic viscosurgical device (OVD) the TIOL was rotated to its final position and the toric reference marker was aligned using the navigation system Callisto Eye (Carl Zeiss Meditec AG, Jena, Germany) (Figure 3). In all cases the surgical incision was closed by hydration of the corneal stroma without the use of a suture. At the end of the procedure, antibiotics (Aprokam, Thea Laboratories) were applied into the anterior chamber. Following the operation, antibiotic (Maxitrol, Novartis Pharmaceuticals) and anti-inflammatory drops (Indocolllyre, Bausch + Lomb) were administered.



**Figure 2.** Assessment of the final axis alignment following TIOL implantation using a slit lamp  
*TIOL – toric intraocular lens*



**Figure 3.** Rotation of TIOL to the final position using the Callisto Eye Navigation System  
*TIOL – toric intraocular lens*

### Statistical analysis

The statistical analyses were performed using the online statistical calculator StatisticsKingdom ([www.statskingdom.com/correlation-calculator.html](http://www.statskingdom.com/correlation-calculator.html)). First, a normality test was conducted using the Shapiro-Wilk test. In all cases, the data were evaluated as nonparametric, and consequently, nonparametric tests were used for comparison. A Mann-Whitney test was used to compare the two independent groups. Correlation analysis was performed using the Pearson correlation coefficient. The data are presented as the mean  $\pm$  standard deviation (unless stated otherwise), with a P value  $< 0.05$  considered statistically significant.

### RESULTS

The preoperative and demographic data of the patients are summarized in Table 1. Preoperative monocular UDVA improved from a mean of  $0.4 \pm 0.2$  (expressed in decimal values) to  $0.90 \pm 0.1$  postoperatively. This improvement in UDVA was statistically significant

( $p < 0.0001$ ). The mean postoperative monocular CDVA was  $1.0 \pm 0.2$ . As shown in the cumulative histogram (Graph 1), 100% of eyes achieved a postoperative monocular UDVA of  $\geq 0.6$  and a CDVA of  $\geq 0.8$ . The mean SE of postoperative subjective refraction was  $-0.4 \pm 0.4$  D. The mean postoperative monocular UNVA measured at 40 cm using Jaeger charts corresponded to Jaeger no. 4. All patients were able to read Jaeger no. 1 postoperatively with spectacle correction. The mean value of the best near-vision spectacle correction was  $+1.3 \pm 0.4$  D sf.

A significant reduction in astigmatism was observed when comparing the mean preoperative corneal astigmatism ( $-1.03 \pm 0.3$  Dcyl) with the postoperative residual refractive astigmatism ( $-0.6 \pm 0.4$  Dcyl), both measured using the same instrument (TRK-2P) ( $p = 0.0003$ ). No significant difference ( $p = 0.894$ ) was found between the mean preoperative corneal astigmatism measured by the autorefractometer TRK-2P ( $-1.03 \pm 0.3$  Dcyl) and that measured by the optical biometer IOL Master 700 ( $-1.0 \pm 0.2$  Dcyl) ( $p = 0.894$ ). A moderate correlation was demonstrated between the two sets of values, as indicated by Spearman's rank correlation coefficient ( $r = 0.426$ ,  $p = 0.021$ ) (Graph 2).

The mean absolute value of rotational deviation from the intended axis of implantation in our cohort was  $1.93 \pm 2.65^\circ$  (range:  $0^\circ$  to  $11^\circ$ ). The TIOL rotated clockwise in 10 cases (mean deviation:  $4.4 \pm 3^\circ$ ), counterclockwise in 5 cases (mean deviation:  $2.4 \pm 1^\circ$ ), and remained precisely aligned with the planned axis in 14 cases. The Spearman's rank correlation coefficient for the correlation between the planned axis and the final postoperative

**Table 1.** Demographic and preoperative characteristics of the study population

Demographic	Mean $\pm$ SD	Min	Max
Number of eyes (patients)	29 (18)		
Male/Female (n)	11/7		
Age (years)	$62 \pm 8$	50	77
UDVA (decim.)	$0.4 \pm 0.2$	0.1	0.8
SPH (D)	$+1.4 \pm 1.4$	-1.75	3.5
CYL (D)	$-1.03 \pm 0.3$	-0.75	-1.75
SEQ (D)	$+1.2 \pm 1.6$	-2.25	3.25
AXL (mm)	$23.7 \pm 0.8$	21.7	24.8
K1 (mm)	$42.2 \pm 1.2$	39.7	44.1
K2 (mm)	$43.2 \pm 1.4$	40.7	46
IOL power (D)	$22 \pm 2$	19	27.5
IOL cylinder (D)	$1.1 \pm 0.2$	1	1.5

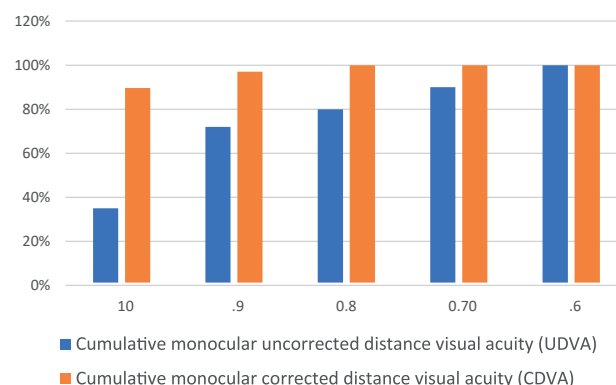
UDVA – Uncorrected Distance Visual Acuity (decimal value), SPH – Preoperative spherical refraction, CYL – Preoperative cylindrical refraction, SEQ – Spherical equivalent refraction, AXL – Axial length, K1 – Flattest meridian of keratometry, K2 – Steepest meridian of keratometry, IOL power – Spherical power of intraocular lens, IOL cylinder – Cylindrical power of intraocular lens, SD – Standard deviation, Min – Minimum value, Max – Maximum value

axis was  $r = 0.992$ , indicating a high degree of predictability in lens positioning (Graph 3).

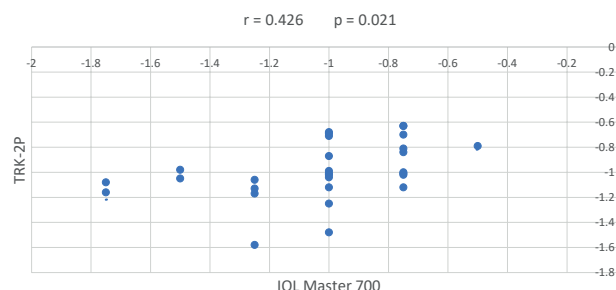
Subjective satisfaction was assessed on a scale from 1 to 5, where lower scores indicated greater satisfaction. The average score was 1.4. A score of 1 was reported for 18 eyes (62%) and a score of 2 for 11 eyes (38%). In response to a targeted question on pseudophakic dysphotopsia, a halo effect was reported in 15 cases (52%), glare in 5 cases (17%), and no dysphotopsias were recorded in 9 eyes (31%). None of the patients reported dysphotopsia as interfering with their daily activities or causing significant discomfort. Near-vision correction with spectacles was used in 7 cases (24%), distance-vision correction with spectacles in 1 case (3%), and complete independence from wearing spectacles was achieved in 22 cases (76%) in our cohort.

## DISCUSSION

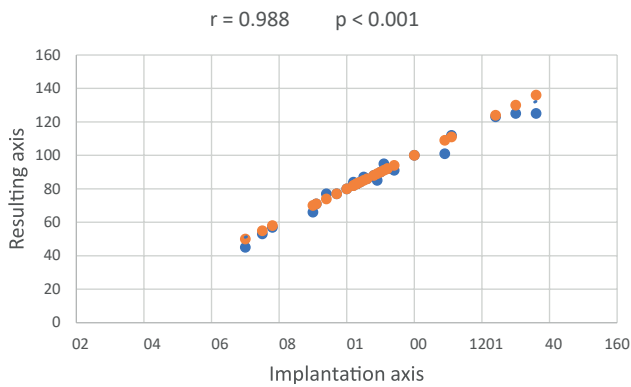
Implantation of toric EDOF IOLs represents a significant advancement in the surgical treatment of cataracts and presbyopia, particularly for patients with corneal astigmatism. Our study demonstrated that the use of the Bi-Flex ELON Toric POB-MA model led to a reduction of



**Graph 1.** Cumulative percentage of eyes with different degrees of uncorrected and corrected distance visual acuity (UDVA, CDVA)



**Graph 2.** Correlation between keratometry measurements on the TRK-2P (Topcon) and IOL Master (Zeiss) ( $r$  – Spearman's Correlation Coefficient,  $p$  – Probability Value)



**Graph 3.** Comparison of EDOF TIOL implantation and resulting axis ( $r$  – Spearman's Correlation Coefficient,  $p$  – Probability Value)

*EDOF TIOL – toric intraocular lens with extended depth of focus*

residual astigmatism and a significant improvement of visual functions, including UDVA, CDVA, and UNVA.

One of the key parameters in calculating the appropriate IOL is the preoperative value of corneal astigmatism. According to literature recommendations, astigmatism correction is typically indicated for values of  $\geq 1$  Dcyl [13,14]. To maximize patient independence from spectacles postoperatively, our center focuses on correcting astigmatism at values as low as  $\geq 0.75$  Dcyl. For accurate postoperative outcomes, it is recommended to measure keratometry using two different instruments. In our study, we used an automatic keratometer, TRK-2P, and an optical biometer, IOL Master 700, for measurement. No significant difference was observed between the measured values, in which the value of Spearman's rank correlation coefficient ( $r = 0.426$ ) confirmed a correlation between the measurements. In our cohort of patients, we corrected predominantly low values of astigmatism (average preoperative corneal astigmatism was  $-1.03 \pm 0.3$  Dcyl, and in all cases, the cylindrical powers of the implanted TIOLs were 1.0 or 1.5 Dcyl). Upon correction of higher values of astigmatism, the correlation between the measurements on the two instruments is higher. This finding is in accordance with the results of the study conducted by Pašková et al. (2024), which demonstrated a higher correlation ( $r = 0.873$ ) between the values of keratometry obtained by the two instruments (Nidek ARK-1a and IOL Master) on a similar sample of patients (with a higher mean value of preoperative corneal astigmatism of  $-2.4 \pm 0.7$  Dcyl).

As with other TIOLs, lens rotation was also observed in our cohort of patients with a toric EDOF IOL. Incorrect axial positioning of a TIOL may result from imprecise axial implantation during surgery or undesirable lens rotation in the postoperative period [15,16], both of which may negatively impact visual quality. A rotation of a TIOL by  $1^\circ$  off-axis results in a reduction of astigmatism correction by approximately 3.3% of its power. Studies have shown

that a rotation of more than  $10^\circ$  leads to a one-third reduction in astigmatism correction, and after a  $30^\circ$  rotation, the corrective effect of the TIOL is nullified [17]. Deviation of more than  $30^\circ$  can result in the inversion of the angle without diminishing the original astigmatic correction [17,18]. While rotation of a TIOL is a common phenomenon, it is typically not clinically significant unless the rotation exceeds  $5^\circ$  [15]. In our study, the mean absolute value of rotational deviation was  $1.93 \pm 2.65^\circ$ . Only 2 eyes (7%) manifested rotation exceeding  $5^\circ$ , which confirms the high predictability of the resulting axis. These results align with our recent studies following the implantation of TIOLs with the same design (Bi-Flex, double-loop haptics). In one study, the mean absolute value of rotational deviation 1 year post-implantation was  $2.96 \pm 2.42^\circ$  [19], while in another study, the mean was  $1.42 \pm 1.89^\circ$ , with no rotations greater than  $5^\circ$  recorded in any case [20]. The stability of the Bi-Flex IOL is ensured by the unique shape of its haptic system (double loop), which has a large contact angle ( $2 \times 88.8^\circ$ ) with the internal wall of the capsular bag. This design ensures better fixation of the lens within the capsule, minimizing the risk of rotation or displacement after implantation. In 10 cases, the rotation of the TIOL occurred in a clockwise direction (ranging from  $-1^\circ$  to  $-11^\circ$ ), in 5 cases counterclockwise (ranging from  $1^\circ$  to  $4^\circ$ ), and in 14 cases the lens was positioned precisely in the planned axis. In our opinion, the more frequent clockwise rotation may be due to the shape of the lens' haptic part, although this phenomenon has not been unequivocally demonstrated in any study to date [21]. The limit for indicating surgical revision is set at a deviation of  $\geq 10^\circ$  [16]. In our study, rotation of  $11^\circ$  in a clockwise direction was recorded in one eye. Due to excellent monocular UDVA of 1.0 and subjective patient satisfaction, no surgical rotation of the lens was performed in this case. We assume that the increased tolerance of rotational instability of the TIOL in patients with lower values of astigmatism may represent one of the possible explanations for this observed phenomenon. The cylindrical power of the implanted TIOL in this case was 1.0 Dcyl, which represents a relatively low value of astigmatism.

A subjective evaluation of patient satisfaction revealed a high level of satisfaction with the surgical results, with 76% of patients achieving complete independence from wearing spectacles. In the case of dysphotopsias, especially halo effect and glare, the symptoms were mostly mild and were not reported as bothersome by patients, which is in accordance with the expectation for EDOF IOLs. The results of our study confirm that toric EDOF IOLs offer an excellent balance between visual acuity at all distances and minimizing undesirable optical phenomena. Although dysphotopsias were recorded in some cases, their intensity was low, and most patients found them to be acceptable.

One of the main benefits of this technology is its ability to combine the advantages of monofocal and

multifocal IOLs. The results of our study indicate that a toric EDOF IOL is a safe and effective option for patients with presbyopia and corneal astigmatism who desire independence from wearing spectacles for regular distances.

The limitation of our study consists of its retrospective design and the small sample size. Further studies with a larger patient cohort and extended follow-up could provide more insight into the long-term stability of results and the incidence of potential complications. Additionally, while our findings indicate a positive trend, the long-term development of dysphotopsias and patient

satisfaction may be dependent upon individual factors such as the speed of adaptation to new vision, the patient's lifestyle, psychological factors, quality of the cornea, and the presence of other ocular pathologies.

## CONCLUSION

In conclusion, implantation of a toric EDOF IOL appears to be a safe and effective method for correcting presbyopia and astigmatism in patients with cataracts, providing good visual outcomes, high patient satisfaction, and a low risk of complications.

## REFERENCES

1. Georgiev S, Palkovits S, Hirschall N, Döller B, Draschl P, Findl O. Visual performance after bilateral toric extended depth-of-focus IOL exchange targeted for micromonovision. *J Cataract Refract Surg.* 2020 Oct;46(10):1346-1352. doi: 10.1097/j.jcrs.0000000000000290
2. Ferrer-Blasco T, Montés-Micó R, Peixoto-De-Matos SC, González-Méijome JM, Cerviño A. Prevalence of corneal astigmatism before cataract surgery. *J Cataract Refract Surg.* 2009;35(1):70-75.
3. Goggin M. Toric intraocular lenses: evidence-based use. *Clin Exp Ophthalmol.* 2022 Jul;50(5):481-489.
4. Kohnen T. Current and future nomenclature and categorization of intraocular lenses. *J Cataract Refract Surg.* 2024 Aug;50(8):787-788. doi: 10.1097/j.jcrs.0000000000001510
5. Rosen E, Alió JL, Dick HB, Dell S, Slade S. Efficacy and safety of multifocal intraocular lenses following cataract and refractive lens exchange: Meta-analysis of peer-reviewed publications. *J Cataract Refract Surg.* 2016 Feb;42(2):310-328. doi: 10.1016/j.jcrs.2016.01.014. PMID: 27026457
6. Zhong Y, Yu X, Wang Z, et al. Comparison of trifocal or hybrid multifocal-extended depth of focus intraocular lenses: a systematic review and meta-analysis. *Sci Rep.* 2021;11(1):6699.
7. Kohnen T, Suryakumar R. Extended depth-of-focus technology in intraocular lenses. *J Cataract Refract Surg.* 2020;46(2):298-304.
8. Cao K, Friedman DS, Jin S, et al. Multifocal versus monofocal intraocular lenses for age-related cataract patients: a systematic review and meta-analysis based on randomized controlled trials. *Surv Ophthalmol.* 2019;64(5):647-658.
9. Alió JL, Plaza-Puche AB, Fernández-Buenaga R, Pikkel J, Maldonado M. Multifocal intraocular lenses: An overview. *Surv Ophthalmol.* 2017;62(5):611-634.
10. Ferrando Gil J, Churrua Irazola A, Reparaz I, Lauzirika G, Martínez-Soroa I, Mendicutie J. Visual, refractive, functional, and patient satisfaction outcomes after implantation of a new extended depth-of-focus intraocular lens. *Clin Ophthalmol.* 2024 Dec 17;18:3801-13. doi: 10.2147/OPHTH.S499911
11. Megiddo-Barnir E, Alió JL. Latest development in extended depth-of-focus intraocular lenses: an update. *Asia Pac J Ophthalmol.* 2023;12(1):58-79.
12. Pašková B, Marešová K, Schreiberová Z, Malušková M, Karhanová M. Evaluation of Clinical Results of Implantation of Toric Intraocular Lenses Including their Rotational Stability. *Cesk Slov Oftalmol.* 2024;80(3):146-153.
13. Mendicutie J, Irigoyen C, Aramberri J, Ondarra A, Montés-Micó R. Foldable toric intraocular lens for astigmatism correction in cataract patients. *J Cataract Refract Surg.* 2008;34(4):601-607.
14. Statham M, Apel A, Stephensen D. Comparison of the AcrySof SA60 spherical intraocular lens and the AcrySof Toric SN60T3 intraocular lens outcomes in patients with low amounts of corneal astigmatism. *Clin Exp Ophthalmol.* 2009;37(8):775-779.
15. Holland E, Lane S, Horn JD, Ernest P, Arleo R, Miller KM. The AcrySof Toric intraocular lens in subjects with cataracts and corneal astigmatism: a randomized, subject-masked, parallel-group, 1-year study. *Ophthalmology.* 2010;117(11):2104-2111.
16. Jin H, Limberger IJ, Ehmer A, et al. Impact of axis misalignment of toric intraocular lenses on refractive outcomes after cataract surgery. *J Cataract Refract Surg.* 2010; 36: 2061-2072.
17. Novis C. Astigmatism and toric intraocular lenses. *Curr Opin Ophthalmol.* 2000 Feb;11(1):47-50. doi: 10.1097/00055735-200002000-00007
18. Vlčková E, Došková H, Vícha I. První zkušenosti s torickými IOL [Initial experience with toric intraocular lenses]. *Cesk Slov Oftalmol.* 2001 May;57(3): 161-164. Czech.
19. Nováček LV, Němcová M, Sičová K, et al. Simultaneous presbyopia and astigmatism correction with a novel trifocal toric intraocular lens—a one-year follow-up. *J Clin Med.* 2022 Jul 19;11(14):4194. doi: 10.3390/jcm11144194. PMID: 35887960; PMCID: PMC9322991.
20. Nováček LV, Němcová M, Tyx K, et al. Evaluation of astigmatism-correcting efficiency and rotational stability after cataract surgery with a double-loop haptic toric intraocular lens: A 1-year follow-up. *Biomed Hub.* 2021 Feb 17;6(1):30-41. doi: 10.1159/000513894
21. Singh A, Kapoor G, Baranwal VK, Kalra N. Rotational stability of Toric intraocular lenses. *Med J Armed Forces India.* 2022 Jan;78(1):68-73. Epub 2020 Jul 9. doi: 10.1016/j.mjafi.2020.03.014