

# Punctate Inner Pachychoroidopathy Associated with Choroidal Neovascularization. A Case Report

Orrego-Vélez Maria Antonia<sup>1</sup>, Quintero-Lizcano Karol<sup>1,2</sup>,  
Turizo Sara<sup>1,2</sup>, Arango Mauricio<sup>1,2</sup>

<sup>1</sup>Faculty of Medicine, Department of Ophthalmology, CES University,  
Medellín, Colombia

<sup>2</sup>Retina and Vitreous department, Clófán Clinic, Medellín, Colombia



Maria Antonia Orrego-Vélez, MD.

Submitted to the editorial board: April 17, 2025

Accepted for publication: May 19, 2025

Available on-line: July 7, 2025

*The authors of the study declare that no conflict of interest exists in the compilation, theme and subsequent publication of this professional communication, and that it is not supported by any pharmaceutical company.*

Correspondence address:

Clínica CES, Calle 58 N° 50C-2 Prado Centro  
Medellín, Antioquia, Medellín  
050012 Colombia

E-mail: mariaantoniaorrego222@gmail.com

## SUMMARY

**Aims:** To report a case of punctate inner choroidopathy (PIC) with pachychoroid disease features and active choroidal neovascular membrane.

**Materials and methods:** Case report

**Results:** A 33-year-old female patient with a history of myopic neovascular membrane in the right eye (OD), who had received multiple doses of intravitreal Aflibercept, consulted our retina service. Best-corrected visual acuity was 20/40 in OD. Fundus examination revealed small, well-defined, yellow-gray spots with subretinal fluid limited to the posterior pole. Optical coherence tomography scans from the OD showed subretinal fluid and a hyperreflective material between the epithelium/Bruch membrane (RPE/ BrM) complex, associated with loss of normal choroidal architecture and focal conformational choroidal excavation. There was also diffuse choroidal thickening in the macula, with pachyvessels compressing the inner choroid. Fundus autofluorescence showed active PIC lesions. With these findings, the diagnosis of punctate inner pachychoroidopathy associated with active choroidal neovascular membrane was made and Aflibercept therapy was restarted.

**Conclusions:** A subset of patients with PIC exhibits features associated with pachychoroid disease. This subtype of PIC is determined by unique demographics, multimodal image findings, and complications that differ from classic PIC, due to the potential influence of choroidal venous insufficiency on PIC manifestations and secondary complications.

**Key words:** antiangiogenic therapy (anti-VEGF), choroidal neovascularization, punctate inner choroidopathy, pachychoroid, choroidal venous congestion, optical coherence tomography (OCT)

*Čes. a slov. Oftal., 82, 2026, No. 1, p. 51–54*

## INTRODUCTION

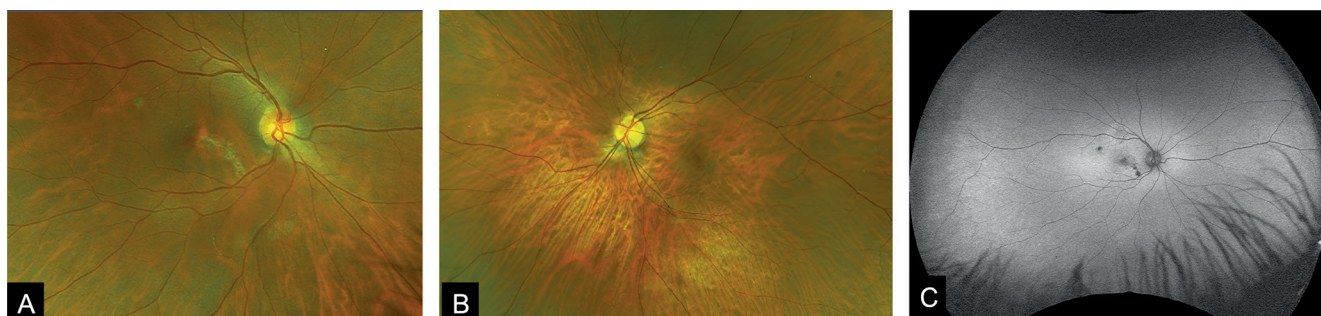
Different pathologies can compromise choroidal structure and function, so it is essential to distinguish these disorders thorough imaging and diagnostic evaluations. Punctate inner choroiditis/idiopathic multifocal choroiditis (PIC/MFC) is an inflammatory disease of the choroid, outer retina and retinal pigment epithelium (RPE) that usually affects young women with myopia and thin choroids [1]. It is characterized by the presence of bilateral yellow-white round or oval lesions in the inner choroid and/or RPE [2]. On fundus autofluorescence, acute lesions appear as hypoautofluorescent spots with a hyperautofluorescent margin if there is disease activity [3]. Optical coherence tomography (OCT) shows choroidal hyperreflectivity, sub-RPE hyperreflective deposits probably composed of B-cell infiltrates and transient reversible photoreceptor alterations [1,4]. Although it

can be a self-limited condition, active PIC has the potential to cause permanent visual loss if associated with neovascularization or inflammation. On the other hand, pachychoroid disease encompasses a group of conditions characterized by attenuation of the choriocapillaris with overlying dilated choroidal veins. Diverse entities have been described within this spectrum, including focal choroidal excavation (FCE), which is often associated with other diseases; previous studies have described FCE in 6% of eyes with polypoidal choroidal vasculopathy [7]. A novel entity in patients with emmetropia or low myopia, thick choroids, choroidal vascular hyperpermeability and a high prevalence of FCE with an inflammatory component has been recently described, as punctate inner pachychoroidopathy [8]. Here, we report the case of a 33-year-old woman with this newly defined condition and its association with choroidal neovascularization (CNV).

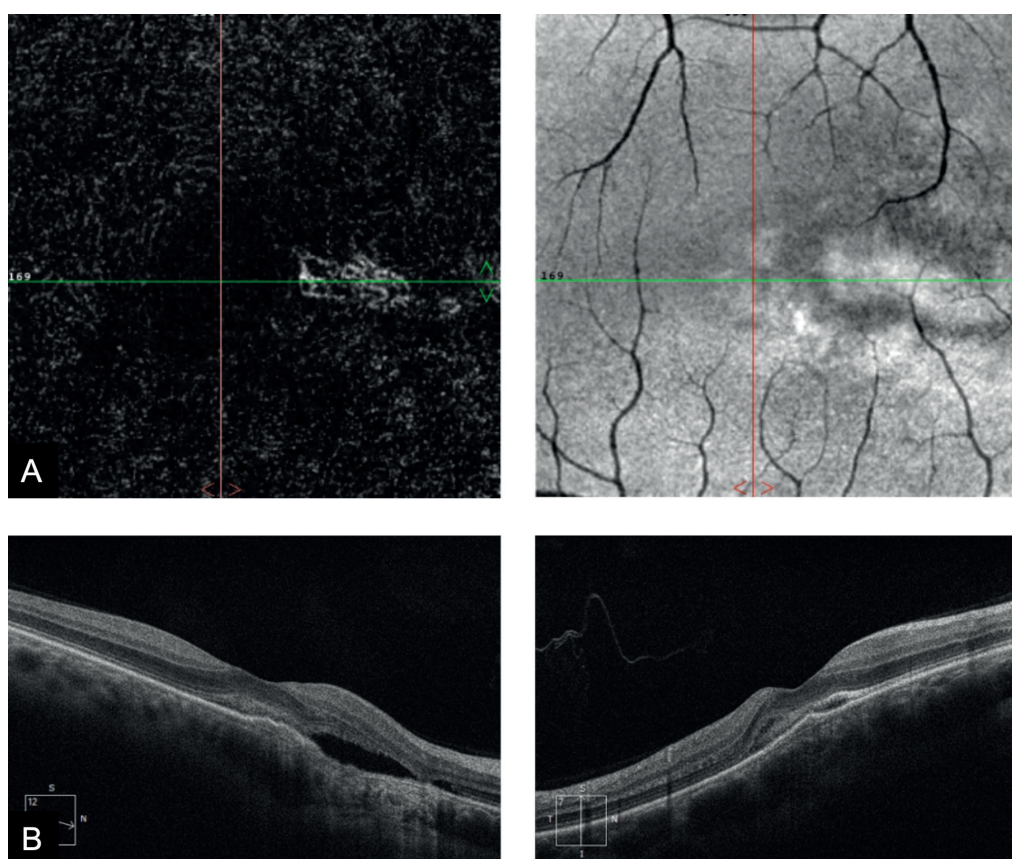
## CASE REPORT

A 33-year-old woman with a history of myopia in both eyes (-1.50 -1.25 x 50° in the right eye and -7.50 -0.25 x 100° in the left eye (OS)) and a previous diagnosis of myopic macular neovascularization in her OD, treated with intravitreal anti-vascular endothelial growth factor (anti-VEGF) injections (12 doses of Ranibizumab) by another specialist, presented to our retina service with

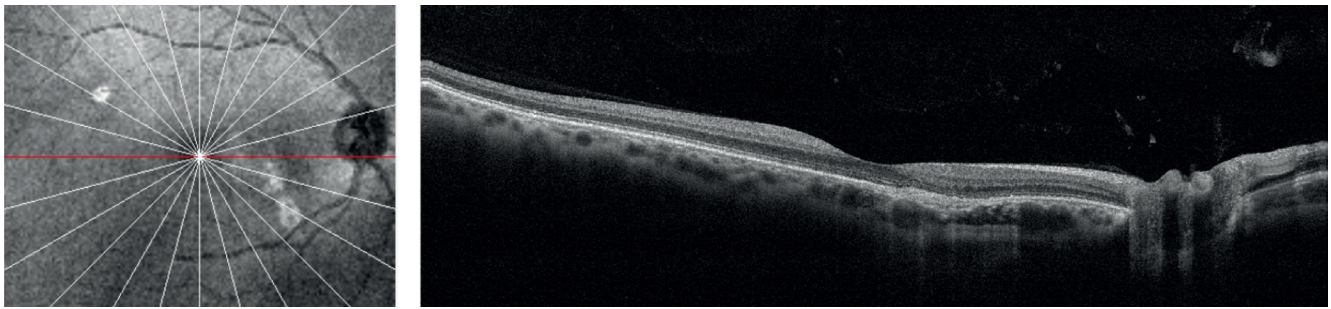
metamorphopsia in said eye. Best-corrected visual acuity at presentation was 20/40 in her OD and 20/30 in her OS. Anterior segment examination was unremarkable and the fundoscopic exam of the OD revealed macular chorioretinal scarring, subretinal fluid, areas of fibrosis and multiple round hyperpigmented lesions with hypopigmented borders in the macula. (Figure 1A). Fundus examination of the OS only exhibited augmented tessellation (visibility of large choroidal vessels at the posterior fun-



**Figure 1.** Color fundus photography of the right eye (A) revealed small, well-defined, yellow-gray spots limited to the posterior pole and distributed in a linear pattern with subretinal fluid. And left eye (B), only exhibited augmented tessellation. Fundus autofluorescence from the right eye (C) showed multiple hypoautofluorescent spots with a hyperautofluorescent margin showing active PIC lesions  
*PIC – punctate inner choroidopathy*



**Figure 2.** (A) En face OCT-A of the right confirmed that the right eye had a CNV with subfoveal involvement. (B) B scans showed subretinal fluid in the context of a subretinal hyperreflective material splitting the retinal pigment epithelium/Bruch membrane (RPE/BrM) complex associated with loss of the normal choroidal architecture and a focal conformational choroidal excavation, there is also a diffuse increased choroidal thickness in the macula with pachyvessels compressing the inner choroid. The ellipsoid zone and interdigitation zone in the vicinity of the lesion were disrupted



**Figure 3.** OCT of the right eye after three-monthly doses of aflibercept

dus pole outside of the peripapillary region) (Figure 1B). Autofluorescence imaging of the OD showed that these lesions were hypoautofluorescent and some of them presented hyperautofluorescent borders (Figure 1C). Optical coherence tomography angiography (OCTA) confirmed that the OD had a CNV with subfoveal involvement and signs of activity associated with conforming focal choroidal excavation and pachyvessels (Figure 2A, B). Given the presence of active neovascularization, it was decided to administer a new set of three-monthly doses of Aflibercept, with an adequate clinical (BCVA of 20/25 in her OD) and tomographic response (Figure 3).

## DISCUSSION

PIC is an idiopathic inflammatory multifocal chorioretinopathy with a wide range of clinical phenotypes. However, these lesions have never been explicitly described in eyes with pachychoroid disease [1]. Ramtohl et al. in their study identified two distinct clusters of patients with different characteristics: the first group included older patients with high myopia, signs of myopic maculopathy, thin choroids and a higher tendency to develop patchy chorioretinal atrophy; the other group consisted of younger emmetropic or low myope patients with signs of pachychoroid disease and a higher frequency of FCE and subretinal fibrosis, similar to the patient described in our report. Based on the observations in the second cluster, the authors introduced the term “punctate inner pachychoroidopathy” for the first time. These eyes present changes in the permeability of choroidal blood vessels, which lead to increased choroidal thickness, a fundamental characteristic in the pachychoroid spectrum. FCE is also an entity that occurs in patients with pachychoroid disease, and it is believed to derive from Bruch’s membrane defects, choroidal scarring, atrophy, and contraction at the site of a previous inflammatory or

degenerative process. The coexistence of FCE and other diseases associated with pachyvessels has been previously described. Ramtohl et al. described FCE in 100% of patients with punctate inner pachychoroidopathy. They suggest that pachychoroid disease spectrum features are a prerequisite for FCE formation [1].

Moreover, different authors have described FCE in eyes with CNV, establishing a potential association [7]. This coexistence might arise due to several proposed theories, including: RPE thinning leading to ischemic changes, deterioration of Bruch’s membrane and aberrant choroidal vasculature [10]. An inflammatory component has also been proposed in some cases of CNV associated with idiopathic FCE and it might develop at the site of previous punctate inner choroidopathy lesions. However, this case would be the first one to describe this association in punctate inner pachychoroidopathy [8]. Evaluating CNV association in these patients requires advanced imaging techniques, such as OCTA and, in cases with confirmed neovascularization, anti-VEGF therapy should be considered [10]. Nevertheless, responses to such treatment remain unpredictable and may vary amongst individuals. Fortunately, in our case, three doses of anti-VEGF therapy induced anatomical and visual improvement.

## CONCLUSION

The patient presented herein exhibits findings characteristic of a condition in which pachychoroid, RPE lesions and FCE coexist. These overlapping features have been recently described as punctate inner pachychoroidopathy. However, to our knowledge, our case is the first report in the literature of CNV related to this novel entity. Our patient also displayed a very good response to intravitreal antiangiogenic therapy. Nonetheless, more studies or case series are required to define its role in this newly defined pathology.

## REFERENCES

1. Ahnood D, Madhusudhan S, Tsaloumas MD, Waheed NK, Keane PA, Denniston AK. Punctate inner choroidopathy: A review. *Surv Ophthalmol.* 2017 Mar-Apr;62(2):113-126. Epub 2016 Oct 15. doi: 10.1016/j.survophthal.2016.10.003
2. Standardization of Uveitis Nomenclature (SUN) Working Group. Classification Criteria for Punctate Inner Choroiditis. *Am J Ophthalmol.* 2021 Aug;228:275-280. Epub 2021 Apr 15. doi: 10.1016/j.ajo.2021.03.046

3. Li M, Zhang X, Wen F. The Fundus Autofluorescence Spectrum of Punctate Inner Choroidopathy. *J Ophthalmol*. 2015;2015:202097. Epub 2015 Jul 22. doi: 10.1155/2015/202097
4. Vance SK, Khan S, Klancnik JM, Freund KB. Characteristic spectral-domain optical coherence tomography findings of multifocal choroiditis. *Retina*. 2011 Apr;31(4):717-723. Epub 2015 Jul 22. doi: 10.1097/IAE.0b013e318203c1ef
5. Ruiz-Medrano J, Montero JA, Flores-Moreno I, Arias L, García-Layana A, Ruiz-Moreno JM. Myopic maculopathy: Current status and proposal for a new classification and grading system (ATN). *Prog Retin Eye Res*. 2019 Mar;69:80-115. Epub 2018 Nov 1. doi: 10.1016/j.preteyeres
6. Hady SK, Xie S, Freund KB, et al. Prevalence and characteristics of multifocal choroiditis/punctate inner choroidopathy in pathologic myopia eyes with patchy atrophy. *Retina*. 2022 Apr 1;42(4):669-678. doi: 10.1097/IAE.0000000000003383
7. Cheung CMG, Lee WK, Koizumi H, Dansingani K, Lai TYY, Freund KB. Pachychoroid disease. *Eye (Lond)*. 2019 Jan;33(1):14-33. Epub 2018 Jul 11. doi: 10.1038/s41433-018-0158-4
8. Ramtohul P, Freund KB, Parodi MB, et al. Punctate inner pachychoroidopathy: Demographic and Clinical Features of Inner Choroidal Inflammation in Eyes with Pachychoroid Disease. *Retina*. 2023 Nov 1;43(11):1960-1970. doi: 10.1097/IAE.0000000000003926
9. Kim H, Woo SJ, Kim YK, et al. Focal choroidal excavation in multifocal choroiditis and punctate inner choroidopathy. *Ophthalmology*. 2015;122:1534-1535.
10. Ghadiali Q, Dansingani KK, Freund KB. focal choroidal excavation and choroidal neovascularization with associated pachychoroid. *Retin Cases Brief Rep*. 2016 Autumn;10(4):293-296.