

Screening ROP in the University Hospital Ostrava

REPORT

Timkovič J.¹, Němčanský J.¹,
Cholevík D.¹, Kolarčíková V.¹,
Mašek P.¹, Pokrývková M.²,
Poláčková R.²

¹Eye Clinic, Univerzity Hospital Ostrava,

Head: MUDr. Petr Mašek, CSc.

²Department of Neonatology, Univerzity Hospital Ostrava

Head: MUDr. Renáta Poláčková

SUMMARY

Objective: to analyze the group of premature infants who were examined by an ophthalmologist in screening for ROP (retinopathy of prematurity) at the University Hospital in Ostrava.

Methods: A retrospective observational case series. We reviewed and analyzed clinical records of all the premature infants born before the 32nd gestational week examined by ophthalmologist in ROP screening at the University Hospital in Ostrava in the period from 1. 9. 2011 to 31. 8. 2012. Children's gestational age at birth, birth weight, postconceptional age (PCA) of the child at the time of the first ocular inspection, at the time of diagnosis ROP and at the time of any intervention, possible risk factors of ROP (Apgar score in the 1st minute, duration of oxygen therapy, FiO₂ (%) (percentage fraction of oxygen in the inspired gas mixture), duration of mechanical ventilation, transfusion of erythrocytes (resuspended leukodepleted), presence of sepsis / infection in the perinatal period and duration of phototherapy) were evaluated. Eye examination was performed in local anesthesia with the use of an eyelid retractor, in artificial mydriasis, using an indirect ophthalmoscope and digital imaging system RetCam 3.

Results: 138 premature infants with an average gestational age at birth of 29.8 weeks, average birth weight 1385 g, were included in this study. Thirty-four children (24.6 %) were diagnosed with ROP, in all cases 1st stage at the time of diagnosis. An ophthalmologist indicated and subsequently implemented intervention (cryotherapy / laser treatment) in the case of five children (14.7 %) with ROP under general anesthesia. Average duration of oxygen therapy at infants with ROP was 371 hours, in the group without ROP 84 hours. The difference between the average values was statistically significant [t (37) = -3.69, P <= 0.0007]. Average time of mechanical ventilation in the case of children with ROP were 229 hours, in the group without ROP 41 hours [t (35) = -2.99, P <0.005]. In the case of children with ROP, we noticed on average 3 transfusions of erythrocytes, in the group without ROP 1 transfusion [t (40) = -3.94, P <= 0.0003]. The average value of the Apgar score in the 1st minute of children with ROP group was 6.3 and children without ROP 7.8. The difference between the average values of Apgar score in the 1st minute was between both groups statistically significant [t (136) = 4.06, P <= 0.00008]. Sepsis / infection in the perinatal period occurred in 30 (88.2 %) children with ROP, in comparison with 46 (44.2 %) children with sepsis / infection without ROP. Average duration of phototherapy in infants with ROP was 42.4 hours, in the group without ROP 53.6 hours [t(136) = 1,21, P<= 0,2]. Conclusion: This study demonstrated statistically significant correlation of Apgar score in the 1st minute, duration of oxygen therapy, duration of mechanical ventilation, transfusion of erythrocytes and presence of sepsis / infection on the onset and progression of ROP at premature infants in our group. No effect of FiO₂ (%) and duration of phototherapy on the onset and progression of ROP was demonstrated.

Key words: ROP, retinopathy of prematurity, ROP screening, RetCam 3, risk factors of ROP

First author:

MUDr. Juraj Timkovič

Eye Clinic, Univerzity Hospital Ostrava,

17. listopadu 1790

708 52 Ostrava - Poruba,

email: timkovic.j@bluepoint.sk

Čes. a slov. Oftal., 69, 2013, No. 2, p. 51–57

INTRODUCTION

Retinopathy of prematurity (ROP) was first described in 1942 by Terry as greyish white non-translucent retrolental membranes (retrolental fibroplasias). He assumed that the cause was proliferation of the embryonic hyaloid system [17]. The term retinopathy of prematurity was first used in 1953 by Heath,

who described three histopathological stages of this disorder in his work – primary disease of the retina, secondary affliction of the retina caused by changes in the vitreous body and atrophy of the eye as a consequence of reparation processes [6].

According to the current view, retinopathy of prematurity is a vasoproliferative disorder afflicting especially prematurely born infants with low birth

weight. The etiology of ROP is complex and multi-factorial. The main risk factors are the degree of prematurity and low birth weight, which predict the incidence, course and prognosis of ROP [12]. However, a range of other factors may also participate in the incidence of ROP, and their significance is supported by several studies [9, 11, 14, 15].

RetCam 3 is a digital imaging system enabling a modern alternative to scree-

ning of afflicted retinas in infants. The main advantage of this system is the possibility of a 130-degree view of the retina in comparison with the 30-degree view which can be attained by the classic method of indirect ophthalmoscopy. Studies have demonstrated the higher sensitivity of this method of examination in comparison with the sensitivity of conventional indirect ophthalmoscopy [19].

The aim of our work was to identify possible risk factors of ROP in prematurely born infants in the Moravian-Silesian region.

METHOD

We conducted a retrospective analysis of medical documentation in all infants born before the 32nd week of gestation, examined by an ophthalmologist within the framework of ROP screening in the University Hospital Ostrava within the period from 1 September 2011 to 31 August 2012. The population did not include infants with/without ROP who had not reached the 40th week of post-conception age (PCA) within the monitoring period. The observed parameters covered the gestation age of infants at the time of birth, post-con-

ception age of the infant at the time of the first eye examination, at the time of determining of the ROP diagnosis and at the time of any applicable intervention, also birth weight, possible risk factors of ROP (Apgar score in 1st minute, duration of oxygen therapy, FiO_2 (%) (percentage fraction of oxygen in inhaled gas mixture), time of APV (artificial pulmonary ventilation), transfusion of ERL (erythrocytes resuspended leukodepleted), presence of sepsis / infection in the perinatal period, length of phototherapy). An eye examination was conducted on all the infants under local instillation anaesthesia (oxybuprocaine hydrochloride 0.4% gtt.) using an eyelid speculum (Katena K1-5401 / K1-5677) in artificial mydriasis (phenylephrine hydrochloride 2.5% gtt. + tropicamidum 0.5% gtt.) The fundus was examined by an indirect ophthalmoscope using a 28D lens and digital imaging system RetCam 3 [fig. 1a – 1e]. A Student t-test was used for determination of the statistical significance of the compared results between the groups of infants with / without ROP (statistical program of Microsoft Office Professional Edition, 2003). The indicator of statistical significance was the value $P < 0.05$.

RESULTS

The population was composed of 138 infants (77 boys, 61 girls), with an average gestation age at the time of birth of 29.8 weeks (median 30 weeks, $SD \pm 2.16$, interval 24-32 weeks, with an average birth weight of 1385 g (median 1400 g, $SD \pm 404.78$, interval 460-2200 g). The average age of the infants at the time of the first eye examination was 33 PCA (median 33 PCA, $SD \pm 0.96$, interval 29th-35th PCA). In 34 infants (24.6%) ROP was diagnosed by an ophthalmologist, in all cases the 1st stage at the time of designation of the diagnosis. The average age of these infants at the time of designation of the diagnosis was the 37th PCA (median 36th PCA, $SD \pm 3.86$, interval 32nd-47th PCA), average birth weight 1040 g (median 990 g, $SD \pm 250.86$, interval 460-1490 g). The individual stages of ROP in the prematurely born infants in the population during the observation period are shown in summary by the photographic documentation obtained in the University Hospital Ostrava by the digital imaging system RetCam 3 [fig. 2a – 2f]. In 5 infants (14.7%) with ROP the ophthalmologist indicated and

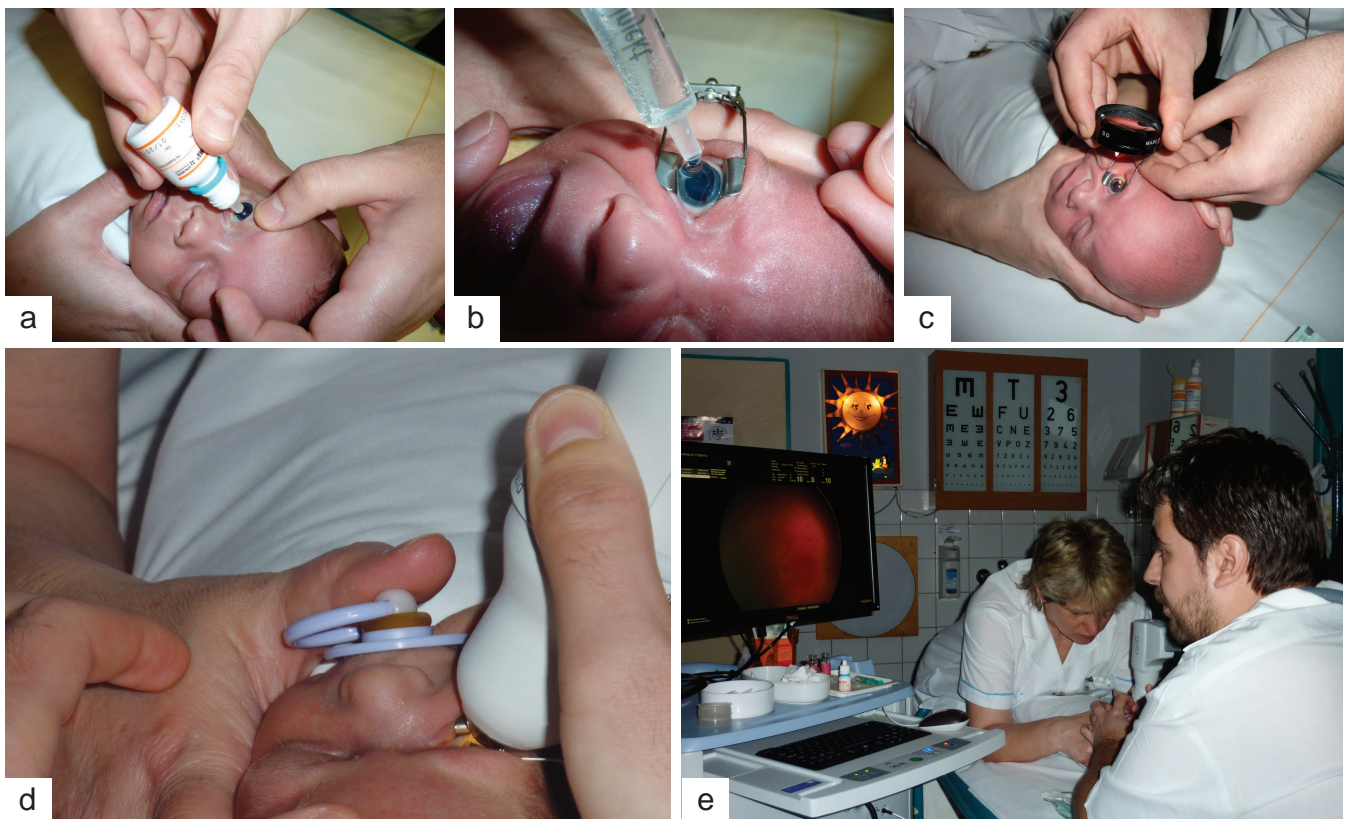


Fig. 1 Eye examination was conducted on all infants under local anaesthesia (fig. 1a), using an eyelid speculum (fig. 1b), in artificial mydriasis. Examination of fundus by indirect ophthalmoscope with use of a 28D lens and digital imaging system RetCam 3 (fig. 1c, d, e,)

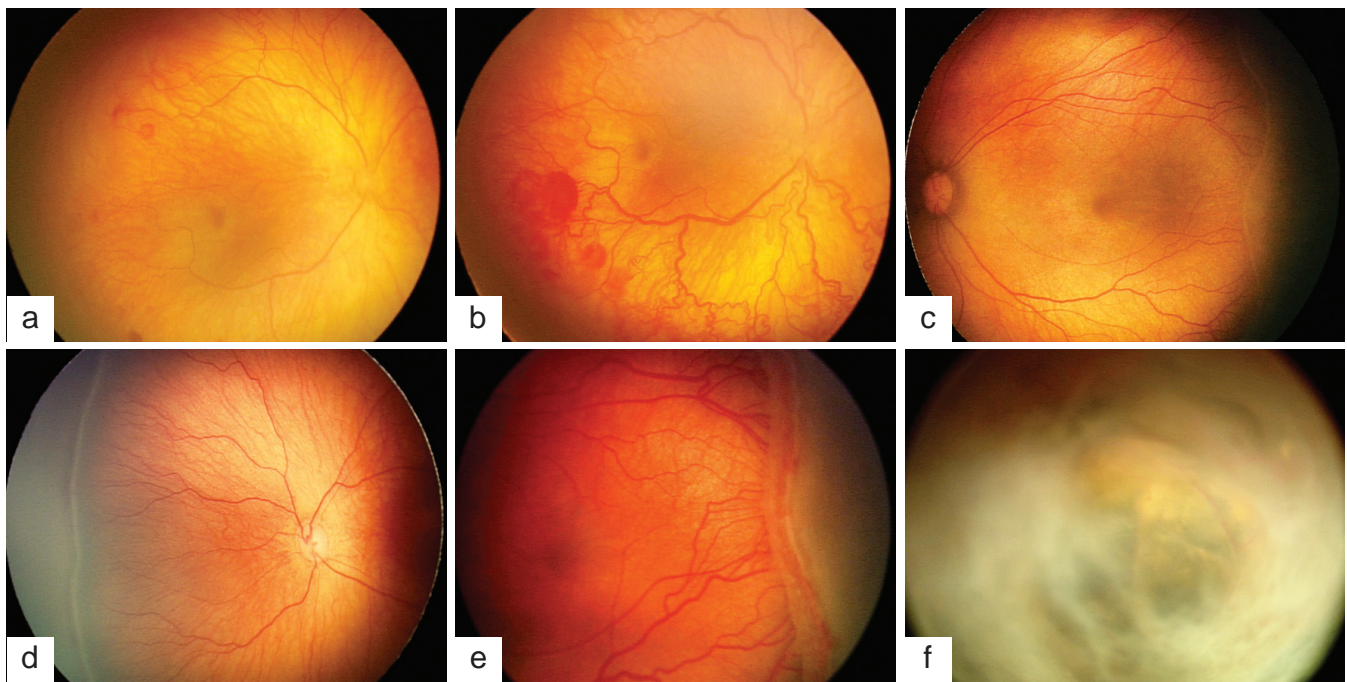


Fig. 2 Progression stages of ROP (retinopathy of prematurity) – photo documentation obtained in the University Hospital Ostrava by digital imaging system RetCam 3. Image of immature vascularisation of retina – progressive constriction of retinal capillaries in the direction towards the periphery (fig. 2a), “plus disease” form of ROP – dilated and coiled capillaries (fig. 2b), ROP stage 1 – a demarcation line separating vascularised and avascular part of retina (fig. 2c), ROP stage 2 – elevation of a demarcation line and formation of the so-called wall (fig. 2d), ROP stage 3 – a ridge-like demarcation line with neovascularisations and incipient extraretinal fibroproliferation (fig. 2e), ROP stage 4 – partial retinal detachment, ROP stage 5 – terminal stage – total retinal detachment (fig. 2f).

subsequently performed intervention (cryotherapy/laser treatment of the retina) under general anaesthesia. The average age of the infants at the time of the intervention was 36th PCA (median 36th PCA, SD \pm 2.28, interval 34th-40th PCA), birth weight 946 g (median 960 g, SD \pm 205.26, interval 690-1250 g). The intervention was conducted under direct monitoring by RetCam 3. The course of cryotherapy and laser photocoagulation of the avascular part of the retina by transscleral diode laser under monitoring by RetCam is displayed in summary in the images [fig. 3a – 3f]. The average time of oxygen therapy in infants with ROP was 371 hours (median 156 hours, SD \pm 441.3, interval 0-1560 hours), in the group without ROP 84 hours (median 5 hours, SD \pm 185, interval 0-1000 hours). The difference between the average values was statistically significant [t(37) = -3.69, P < 0.0007] [graph 1]. The average value of FiO₂ (%) was 42.5% in infants with ROP (median 37.5%, SD \pm 20.8, interval 0-100%) compared to 34.9 % in infants without ROP (median 29 %, SD \pm 22.2, interval 0-100 %). The difference between both groups was statistically insignificant [t(136) = -1.78, P < 0.08] [graph 2]. The average time of APV in infants with ROP was 229 hours (median 44 hours, SD \pm 360.3, interval 0 –

1530 hours), in the group without ROP 41 hours (median 0, SD \pm 102, interval 0 – 700 hours) [t(35) = -2.99, P < 0.005] [graph 3]. In the infants with ROP we recorded an average of 3 ERL transfusions (median 3 transfusions, SD \pm 2.8, interval 0-10), in the group without ROP 1 transfusion (median 1, SD \pm 1.5, interval 0-9) [t(40) = -3.94, P < 0.0003] [graph 4]. The average value of the Apgar score in the 1st minute in infants in the group with ROP was 6.3 (median 6, SD \pm 2.3, interval 2-10), in infants without ROP 7.8 (median 8.5, SD \pm 1.8, interval 1-10). The difference between the average values of the Apgar score in the 1st minute was statistically significant between the two groups [t(136) = 4.06, P < 0.00008] [graph 5]. 30 infants (88.2%) with ROP suffered sepsis / infection in the perinatal period, compared with 46 infants (44.2%) suffering sepsis / infection without ROP [graph 6]. The last observed possible risk factor of ROP in prematurely born infants in the population was the average duration of phototherapy. In infants with ROP this was 42.4 hours (median 44.5 hours, SD \pm 38.9, interval 0-148), in infants without ROP 53.6 hours (median 49 hours, SD \pm 49.6, interval 0-210). The difference between both groups was statistically insignificant in the case of this factor [t(136) = 1.21, P < 0.2] [graph 7].

DISCUSSION

In comparison with foreign studies [13, 18], which state a 68% incidence of ROP in infants with birth weight below 1250 g, the incidence of retinopathy of prematurity in our perinatal centre, nominally in the Moravian-Silesian region, was considerably lower (24.6%, birth weight of infants under 1490 g). The comparison is not completely precise due to the difference in the use of input criteria of the particular studies, but it is sufficient for orientation. We expect that the lower incidence is linked to the marked improvement in ophthalmological-neonatal care of prematurely born infants which has indisputably occurred in the last decade, not only in Europe but worldwide. This is also confirmed by studies from South America (Brazil), in which the incidence of ROP is described in retrospective and prospective studies in 20-23 % infants with low birth weight [8, 16]. Compared to the work of colleagues from Plzeň [9], who observed the above risk factors over a period of 12 years, the incidence of ROP in infants with a birth weight below 1490 g in our workplace is higher (24.6% in comparison with 9%). The significant difference in the incidence of both perinatal centres is most

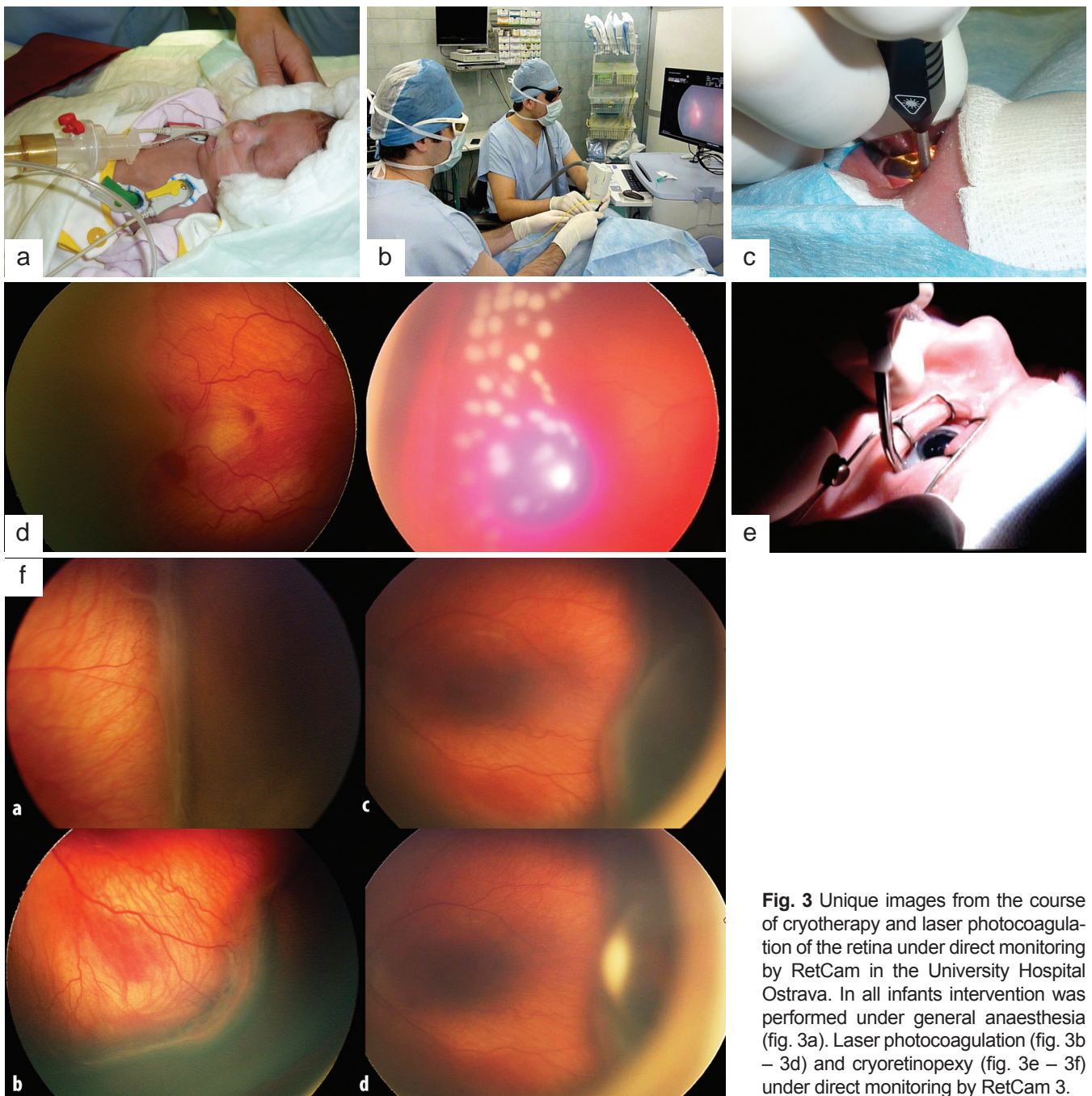
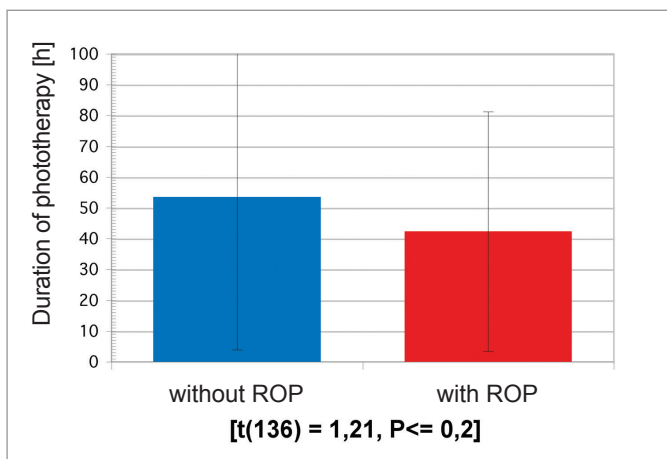
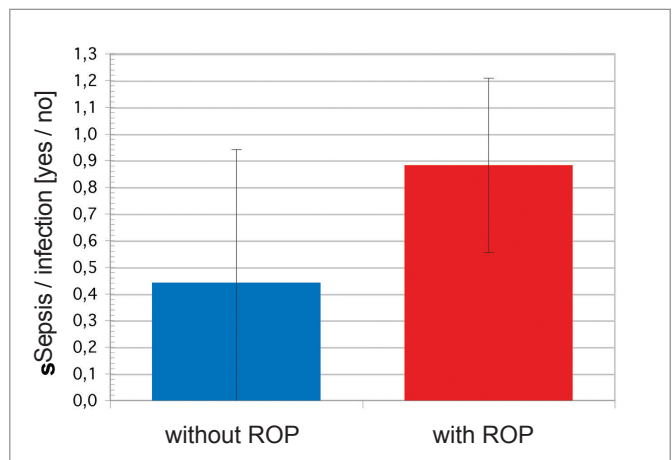
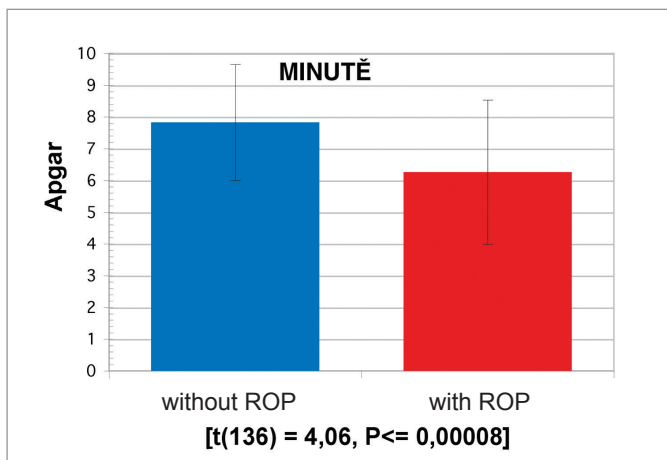
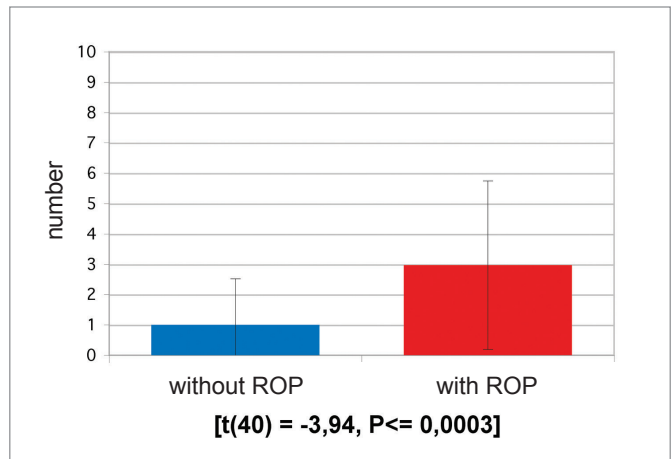
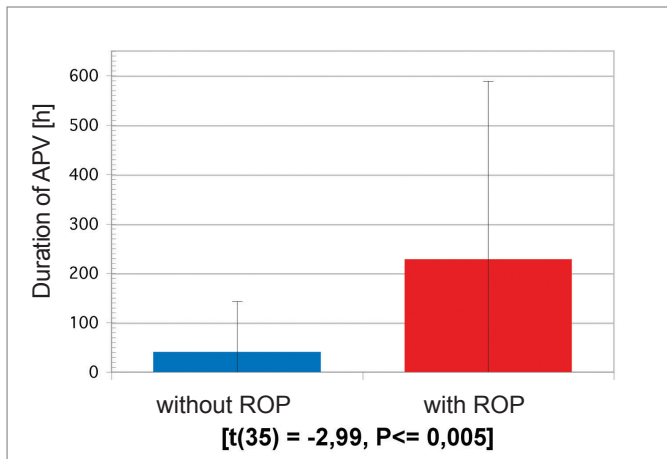
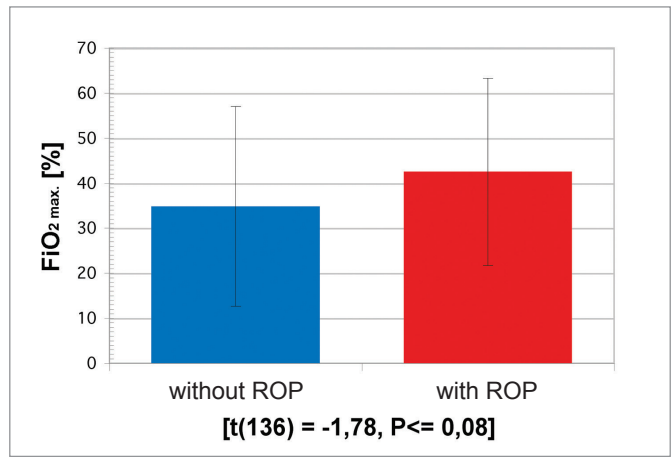
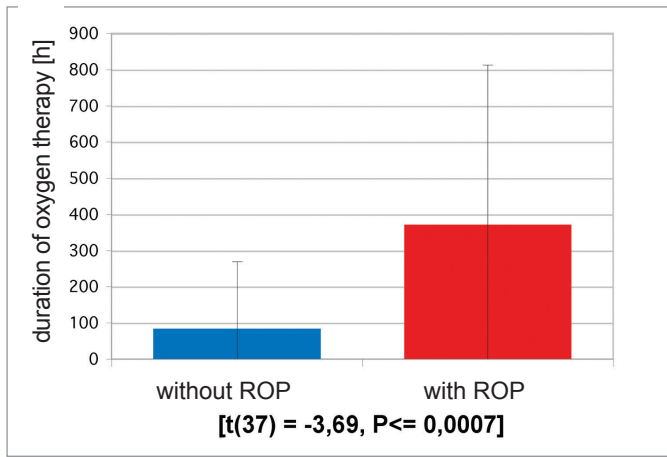


Fig. 3 Unique images from the course of cryotherapy and laser photocoagulation of the retina under direct monitoring by RetCam in the University Hospital Ostrava. In all infants intervention was performed under general anaesthesia (fig. 3a). Laser photocoagulation (fig. 3b – 3d) and cryoretinopexy (fig. 3e – 3f) under direct monitoring by RetCam 3.

probably due to the length and scope of the study and the number of the observed infants. The higher identification of ROP in the Moravian-Silesian region is probably caused by the higher identification of lower degrees of ROP, which may be contributed to by the introduction of routine examination of prematurely born infants by the digital imaging system RetCam 3, which has become an integral component of the screening process at our workplace. Duration of oxygen therapy and artificial pulmonary ventilation also has an influence on the progression of ROP in prematurely born infants and infants with low birth weight. Mehmet et al. in

their study described a significant difference in the length of oxygen therapy in infants with ROP in comparison with infants without affliction of the retina (average 7 ± 13.6 days [10]). Our retrospective trial in the perinatal centre at the University Hospital Ostrava confirms a significant difference in the need for oxygen therapy and duration of artificial pulmonary ventilation of infants with ROP (average 6.5 ± 18.4 days). This fact is confirmed also by other studies [5, 7]. Administration of transfusion is a further risk factor in the incidence of ROP in prematurely born infants. Authors of studies from Italy and Bangladesh have

also reached a similar conclusion [1, 3]. On the other hand, a prospective study from the USA conducted in 1999 did not demonstrate a significant influence of transfusion on the incidence of ROP [2]. In our study we recorded a statistically significant difference in the number of administered transfusions in infants with ROP (in infants with ROP the number of administered transfusions was 3, in comparison with 1 transfusion on a child without affliction of the retina). For an unequivocal conclusion as to whether or not the influence of transfusion is a risk factor for the incidence and progression of ROP it would be necessary to conduct a more extensive study with



Graphs 1-7 Comparison of average length of oxygen therapy, maximum percentage fraction of oxygen in inhaled gas mixture FiO₂ max (%), average length of APV, number of ERL transfusions, Apgar score in 1st minute, presence of sepsis/infection in perinatal period and average length of phototherapy in prematurely born infants examined by ophthalmologists within the framework of ROP screening at the University Hospital Ostrava in the period from 1 September 2011 to 31 August 2012.

precisely defined and comparable criteria and larger populations of patients. Some foreign studies [4] demonstrate an influence of phototherapy on the progression of ROP. In our study no influence of phototherapy on the progression of ROP was demonstrated, the difference between the length of phototherapy in infants with ROP and infants without affliction of the retina was not significant in our population. The result is most probably linked to the measures which we adhere to during phototherapy of newborns. This primarily concerns thorough covering of the eyes with canvas patches as prevention against damage to the retina by blue light. The lack of demonstration of an influence of phototherapy on the progression of ROP is positive feedback for us, indicating that the above-indicated measures are justified.

From the development and improvement of intensive care of premature newborns it ensues that there is a need for increased ophthalmoneonatalogical care and constant improvement thereof according to current trends, which inclu-

de the digital imaging system RetCam 3. The system enables us to obtain photo documentation or a video recording from the examination, comparison of images in time and observation of the dynamics of progression of the disorder or effect of applicable treatment, the possibility of connection to the computer network, sharing and consultation of the obtained photo documentation with another workplace, in particular for borderline cases, and last but not least provides credible, defensible medical-legal documentation. Since December 2011 we have been using this equipment also for therapeutic interventions (laser photocoagulation/cryotherapy of the retina), and so far we have not encountered similar utilisation of this system in the literature. The obtained data shall be the subject of further analysis.

CONCLUSION

In our retrospective trial, in addition to the low birth weight and short gestation period of prematurely born infants, we identified also the length of oxygen therapy and the duration of artificial pul-

monary ventilation as the main risk factors. Further risks are administration of transfusion, postnatal adaptation in the 1st minute of the child after birth and the presence of sepsis/infection in the perinatal period. No influence of phototherapy or the percentage fraction of oxygen in the inhaled mixture of gas on the progression of ROP was demonstrated. Our results do not differ significantly from the previously conducted studies from other regions of the Czech Republic and worldwide, but it would undoubtedly be of benefit to conduct at least a multicenter study. A more profound analysis of the individual risk factors could then improve the precision of the prognostic parameters of the incidence and progression of ROP.

This represents an area of care which has been developing very dynamically, with the typical example being the routine use of the RetCam 3 system, in particular in the precision of diagnostics and data processing. In addition, this system opens up new possibilities also in the therapeutic area – in the sense of performance of intervention under direct monitoring by RetCam.

LITERATURE

- Akter, S., Hossain, M. M., Shirin, M. et al.: Blood Transfusion: A Risk Factor in Retinopathy of Prematurity. *Bangladesh J Child Hlth*, 2012; 34, 2.
- Brooks, S.E., Marcus, D.M., Gillis, D., et al.: The Effect of Blood Transfusion Protocol on Retinopathy of Prematurity: A Prospective, Randomized Study. *Pediatrics*, 1999; 104: 3, 514–518.
- Dani, C., Reali, M.F., Bertini, G., et al.: The role of blood transfusions and iron intake on retinopathy of prematurity. *Early Human Development*. 2001; 62, 1: 57–63.
- Ebrahim, M., Ahmad, R., S., Mohammad, M.: Incidence and Risk Factors of Retinopathy of Prematurity in Babol, North of Iran. *Ophthalmic Epidemiology*. 2010; 17, 3: 166–170.
- Hakeem, A. H. A. A., Othman, M. F., Gamal, B. M.: Retinopathy of prematurity: A study of prevalence and risk factors. *Middle East African Journal of Ophthalmology*. 2012; 19, 3: 289.
- Health, P.: Pathology of retinopathy of prematurity, RLF. *Am J Ophthalmol*, 1953; 34: 1249–1259.
- Hungi, B., Vinekar, A., Datti, N., et al.: Retinopathy of Prematurity in a Rural Neonatal Intensive Care Unit in South India – A Prospective Study. *The Indian Journal of Pediatrics*, 2012; 79, 7: 911–915.
- Lorena, S. H. T., Brito, J. M. S.: Retrospective study of preterm newborn infants at the ambulatory of specialities Jardim Peri-Peri. *Arquivos Brasileiros de Oftalmologia*. 2009, roã. 72, ř. 3, s. 360–364. ISSN 0004-2749.
- Marková, A., Jurčuková, M., Dort, J. a kol.: Hodnocení rizikových faktorů vzniku ROP, oční vady a psychomotorický vývoj nedonošených dětí v západočeském regionu, dvanáctileté sledování. *Čes a Slov Oftalmol*, 2009; 65, 1: 24–28.
- Mehmet, S., Fusun, A., Sebnem, C., et al.: One-year experience in the retinopathy of prematurity: frequency and risk factors, short-term results and follow-up. *Int J Ophthalmol*, 2011; 4(6): 634–640.
- Mutlu, F., M., Altinsoy, H. I., Mumcuoglu, T., et al.: Screening for Retinopathy of Prematurity in a Tertiary Care Newborn Unit in Turkey: Frequency, Outcomes, and Risk Factor Analysis. *J Pediatric Ophthalmol*; 2008; 45, 5, 291–298.
- Odehnal, M., Malec, J., ťůpánková, J., Dotfielová, D.: Souãasnĕ pohled na retinopatii nedonošenãch. řes a Slov Oftalmol, 2011; 67, 2: 35–41.
- Palmer, E.A., Flynn, I.T., Hardy, R. J., et al.: for the Cryotherapy for Retinopathy of prematurity Cooperative Group. Incidence and early course of retinopathy of prematurity. *Ophthalmology*, 1991; 98: 1628–1640.
- Reynolds, J. D., Hardy, R. J., Kennedy, K. A., et al.: Lack of Efficacy of Light Reduction in Preventing Retinopathy of Prematurity. *New England J Med*, 1998; 338, 22: 1572–1576.
- Saugstad, O.D.: Oxygen and retinopathy of prematurity. *J Perinatol*. 2006; 26 (suppl 1): 546–550.
- Schumann, R. de F., Barbosa, A. D. M., Valet, C. O.: Incidence and severity of retinopathy of prematurity and its association with morbidity and treatments instituted at Hospital Antonio Pedro from Universidade Federal Fluminense, between 2003 and 2005. *Arquivos Brasileiros de Oftalmologia*. 2010; 73, 1: 47–51.
- Terry, T. L.: Extreme Prematurity and Fibroblastic Overgrowth of Persistent Vascular Sheath Behind Each Crystalline lens. I. Preliminary report. *Am J Ophthalmol*, 1942; 25: 203–204.
- The Incidence and Course of Retinopathy of Prematurity: Findings from the Early Treatment for Retinopathy of Prematurity Study. *PEDIATRICS*. 2005; 116, 1: 15–23.
- The photographic screening FOR retinopathy of prematurity study (PHOTOROP). *Retina*. 2008; 28: Suppl, S47–S54.