

# HDR 192Ir Brachytherapy in Treatment of Basal Cell Carcinoma of the Lower Eyelid and Inner Angle – Our Experience

Furdová A.<sup>1</sup>, Lukačko P.<sup>2</sup>, Lederleitner D.<sup>3</sup>

<sup>1</sup>Eye Clinic, Komenský University Hospital, Ružinov Hospital, Bratislava, Head: doc. MUDr. Vladimír Krásnik, PhD.

<sup>2</sup>Clinic of Radiation Oncology, Clinic of Oncology St. Elizabeth, Department of brachytherapy, Bratislava, Head: MUDr. Elena Boljevíkova, CSc.

<sup>3</sup>Department of Radiation Oncology, Department of Radiophysics, National Institute of Oncology, Bratislava,

## First author:

doc. MUDr. Alena Furdová, PhD., MPH  
Eye Clinic, Komenský University Hospital, Ružinov Hospital, Bratislava  
Ružinovská 6  
826 06 Bratislava  
e-mail: afrf@mail.t-com.sk,  
alifurdova@gmail.com  
tel: pracovisko 421 2 48234 kl.583

## SUMMARY

**Purpose:** First experience and evaluation of relapses in group of patients after surgery with applied adjuvant HDR brachytherapy for recurrent tumor after incomplete excision of basal cell carcinoma of the lower eyelid and inner angle.

**Methods:** Patients with recurrent basal cell carcinoma of the lower eyelid in year 2010. In 3 male patients with recurrent finding of basal cell after surgery we applied adjuvant HDR 192Ir brachytherapy. The isodose curve chosen to prescribe the dose was 5 mm away from the skin surface.

**Results:** In the year 2010 we applied adjuvant HDR 192Ir brachytherapy in 3 male patients with recurrent basal cell carcinoma. The average age was 58 years (52 to 75 years). From group of 41 patients with non melanotic malignant tumors of the eyelids in 3 patients (7.3 %) with relapse after incomplete excision of the basal cell carcinoma of the lower eyelid we applied after removal of stitches after surgery adjuvant HDR 192Ir brachytherapy. For each patient was made individual orbit mask that bore plastic applicators. Tungsten eye shield applicator was applied to protect the eye globe. Treatment of 10 fractions of 4.5 Gy single dose (5 times weekly) were scheduled within 2 weeks. Patients received outpatient treatment.

**Conclusion:** Acute toxicity postradiation erythema of eyelid and skin around relieved by standard symptomatic treatment within a few days after completion of radiation therapy. In 2 year interval after HDR 192Ir brachytherapy we did not record the occurrence of late complications such as corneal ulcers. Our preliminary experience shows excellent early skin tolerance. After 2 years of follow-up at 6 month interval we did not recognize relapse in our group of patients. The proposed technique of HDR 192Ir brachytherapy after surgery should be considered a new clinical treatment in patients with recurrent non melanotic eyelid cancer. Its main advantage lies in the usefulness in all types of basal cell and squamous cell carcinoma and sebaceous carcinoma of the eyelids, without restriction by site, dimension, clinical or histological type, or the patient's general status.

**Key words:** HDR 192Ir brachytherapy, basal cell carcinoma, eyelid carcinoma treatment

Čes. a slov. Oftal., 69, 2013, No. 2, p. 75–79

## INTRODUCTION

The incidence of tumours in the area of the eyelids (dg. C44.1) has increased in recent years, and with it there has also been an increase in the incidence of malignant skin tumours in other localisations, in which we are recording the highest occurrence of these diseases in the group of patients aged from 70 to 74 years (15). The most frequently occurring nonmelanocytic tumours of the eyelids are basocellular carcinoma (basal cell carcinoma), spinocellular carcinoma, mucoepidermoid carcinoma, sebaceous carcinoma and Merkel cell carcinoma. Tumours which simultaneously afflict the

conjunctiva and the eyelids are squamous cell carcinoma, lymphomas and leukemic infiltrates (1, 13).

Basal cell carcinoma is the most frequent malignant tumour of the eyelids, blameful for 90% of malignant tumours in this area. Its incidence has also been increasing in recent decades. It originates from the basal cells of the epidermis and hair follicles. Histopathologically we can find several forms of basal cell carcinoma: multicentric, sclerodermiform, fibroepithelial, keratinising, metatypical and intraepidermal. We classify them in histopathological stages from G1 – G4. In clinical practice, basal cell carcinoma is most often identified in

stage T1 or T2 (5, 6, 7).

It is a tumour resembling the basal layers of the squamous epithelium. Macroscopically it is very diverse, beginning from minor resistance of the eyelid or medial angle, later exulcerates and infiltrates into the surrounding area. It is distinguished by invasive growth, low mortality and a low tendency towards formation of metastases. Basal cell carcinoma is the main representative of the category of dg. No. C44 MKCH-10 (other malignant skin tumours), the incidence of which was 69/100 000 persons in Slovakia last years (13). It is possible to stipulate a definitive diagnosis of basal cell carcinoma only on the basis

of a histological examination. Upon differential diagnostics it is possible to confuse basal cell carcinoma with adnexal epitheliomas, the presence of melanin must not lead to such confusion. The most important etiological factors in the occurrence of basal cell carcinoma are actinic radiation, genetic influences, carcinogens, scars and chronic damage to skin (1, 4, 8).

Primary therapy of basal cell carcinoma in the area of the lower eyelid and the medial angle is in principle surgical. Broad excision of the deposit with loose resection edges (at least 2-3 mm) is a highly effective solution, with a 5 year rate of local recurrence of less than 10% (16). With regard to the size of the defect after primary excision, it is necessary to continue with a reconstructive surgery for 80% of patients. Some advanced lesions require extensive surgical interventions and it is necessary to embark upon mutilating procedures – orbital exenteration (10). In the case of positive resection edges following insufficient primary excision (e.g. by inexperienced surgeon), the indication of re-excision is considered. In the case of pronounced locally advanced basal cell carcinomas in this area with a high risk of local recurrence after excision or an unacceptable expected cosmetic effect, in patients of advanced age or with repeatedly recurring lesions, the definitive radiotherapy is an appropriate solution. In certain exceptional cases, where a surgical procedure is impossible, isolated radiotherapy may also be a definitive alternative (12).

In the past, especially in the 1970s, external radiotherapy in monotherapy (mostly  $^{60}\text{Co}$ ) was used as a standard in the treatment of basal cell carcinomas in the area of the lower eyelid and medial angle. This procedure has now been surpassed with regard to the post-radiation scar changes in the surrounding area, whilst in certain other localisations this treatment is considered highly effective to this day (5, 8, 14).

After incomplete excision, in the case of recurring malignant tumours of the lower eyelids or in the case of impossibility of a surgical solution, high dose rate (HDR) brachytherapy is currently coming to the forefront (2). The advantage of brachytherapy is the possibility of concentrating the dose of radiation into a small volume and the sharp gradient of the dose into the surrounding area with potential sparing the surrounding tissues. Brachytherapy has a theoretical advantage in comparison with sur-

gery in the fact that it enables coverage of a larger area of the skin with a high dose (macroscopic disease, microscopic disease, safety margin), without the necessity of irreversible damage to the surrounding tissues. Brachytherapy in the treatment of skin tumours may be implemented via the interstitial pathway (surgical introduction of brachytherapeutic applicators directly into the tumour tissue by puncture), or superficially. Superficial brachytherapy is implemented by using standard applicators (e.g. Leipzig Applicator, Brock Applicator, Nucletron BV, Holland), or moulages made to measure. Standard applicators are distinguished by their simplicity of use, good reproducibility of treatment, but they do not enable use for irregular deposits or in a “crooked” irregular terrain such as the periocular area (9, 11).

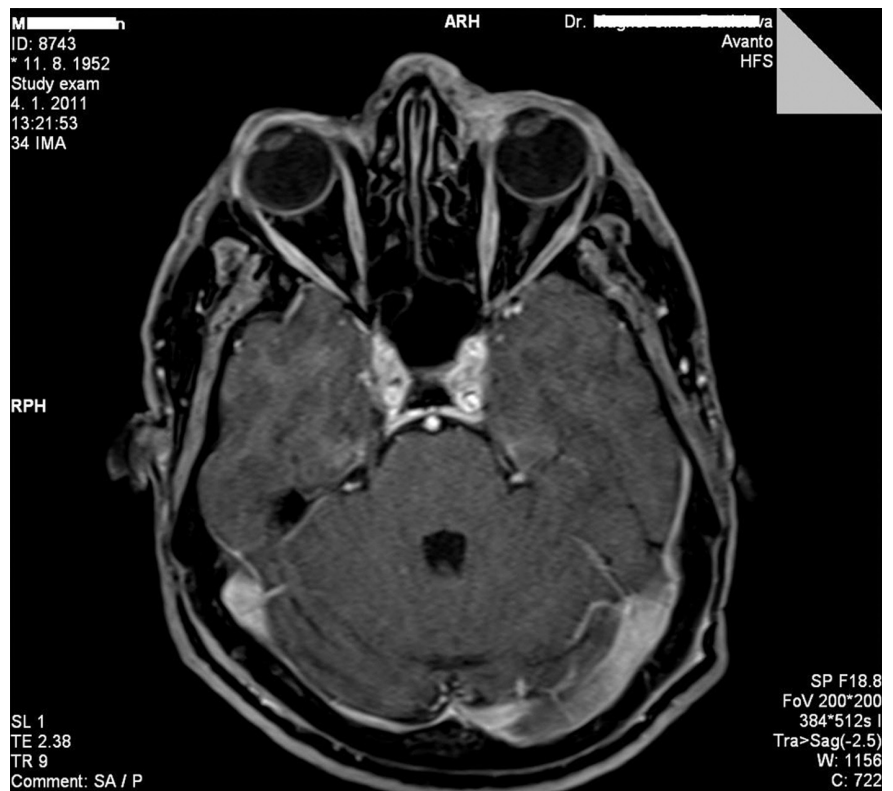
Individually made surface moulages enable us to overcome the above-mentioned circumstances, but require longer preparation. The principle of moulage lies in preparation of a vessel of the appropriate depth, which sufficiently copies the surface of the respective area and bears the plastic applicators for brachytherapy. The vessel can be made of various materials, e.g. dental or thermoplastic materials. Plastic applicators respecting the shape and depth of the target volume are subsequently fixed

to the vessel at a distance of 5-10 mm. Planning systems which reconstruct the spatial distribution of the individual applicators and create an isodose plan at the selected levels are used for calculation of the dose distribution. The resulting dose distribution is specified by a summary of doses in the single path positions of  $^{192}\text{Ir}$  radiation. Subsequent use of an individually made applicator is simple, easily reproducible, comfortable for the patient, and the entire treatment may be conducted in an outpatient form.

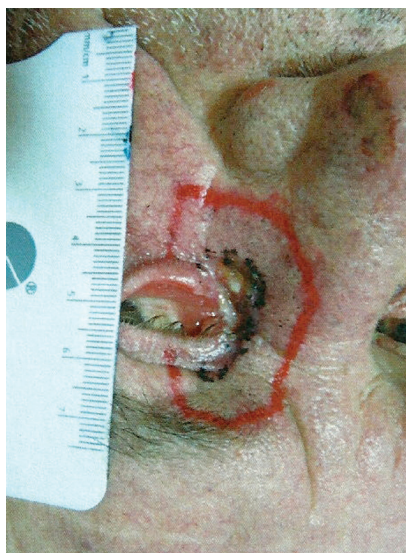## MATERIAL AND METHODOLOGY

In 3 patients (7.3%) with recurring basal cell carcinoma of the medial angle and lower eyelid, after incomplete excision of the lower eyelid and after confirming recurrence by histological examination, we indicated the outpatient adjuvant HDR  $^{192}\text{Ir}$  brachytherapy.

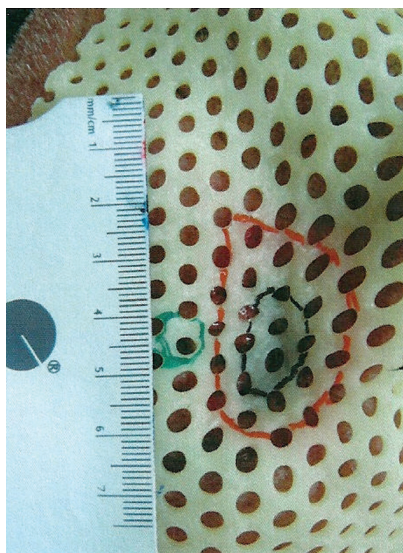
We indicated radiation therapy after removing stitches in the form of surface individually made moulage on the area of the scar and recurrence with a margin of 5-10 mm. An individual thermoplastic mask (Orfit industries, Belgium) was made as a vessel for each patient, onto which plastic applicators for brachytherapy were fixed (Flexible implant tube 6F, Nucletron, Holland). There followed 2D orthogonal reconstruction and calculation of the dose



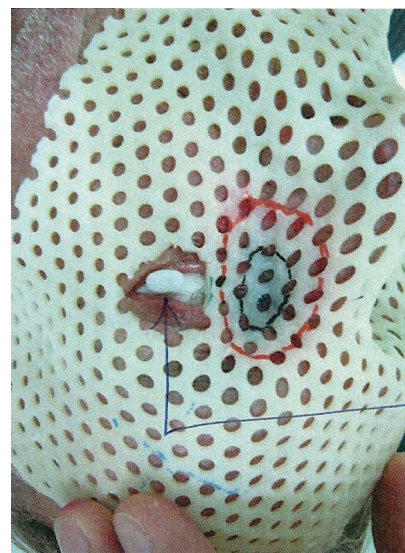
**Fig. 1.** MRI examination of orbit in patient with infiltration of medial angle of left eye before HDR brachytherapy



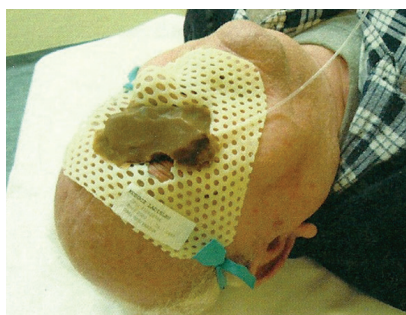
**Fig. 2** Plotting of recurring deposit (black colour) with margin 5-10 mm (red colour) before creation of Orfit mask



**Fig. 4.** Placement of protection on surface of eyeball (Tungsten eye shield)



**Fig. 5.** Treatment position of patient with applied individually made surface moulage



**Fig. 3.** Indication of target volume (red colour) and lens (green colour) on Orfit mask

with subsequent geometric optimisation. In all 3 patients we applied an individual dose of 4.5 Gy in 10 fractions (1 fraction per day, 5 fractions per week), which biologically represented a dose per tumour of 54.4Gy EQD2 ( $\alpha/\beta = 10$ , LQ model). During treatment the eyeball was covered as standard by a Tungsten eye shield applicator (Civco, USA). All patients underwent

treatment as outpatients. Subsequent checks after the completion of brachytherapy were conducted due to expected acute toxicity at 2-week intervals, later at 3-month intervals or after 1 year at 6-month intervals.

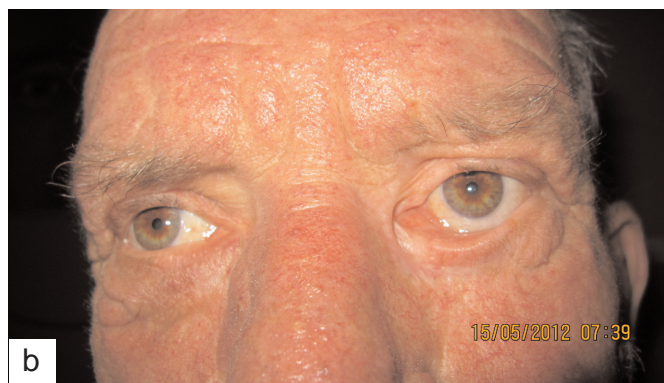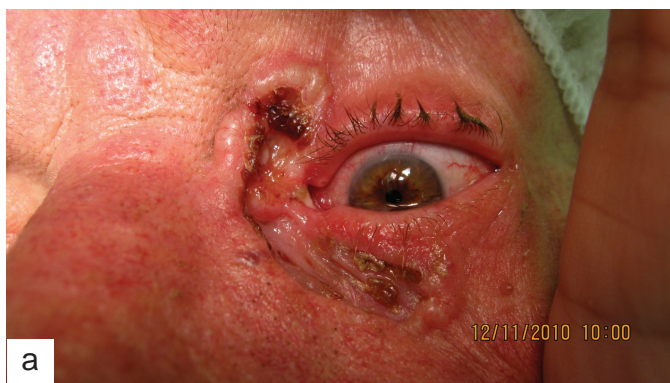## RESULTS

After 2 years of observation at 6-month intervals we did not record recurrence in any of the patients. The results are satisfactory after treatment by HDR 192Ir brachytherapy, we did not record the occurrence of later complications such as corneal ulcer. Acute post-radiation toxicity – erythema of the skin of the eyelids and in the surrounding area subsided after standard symptomatic treatment within a few days of the end of radiation treatment.

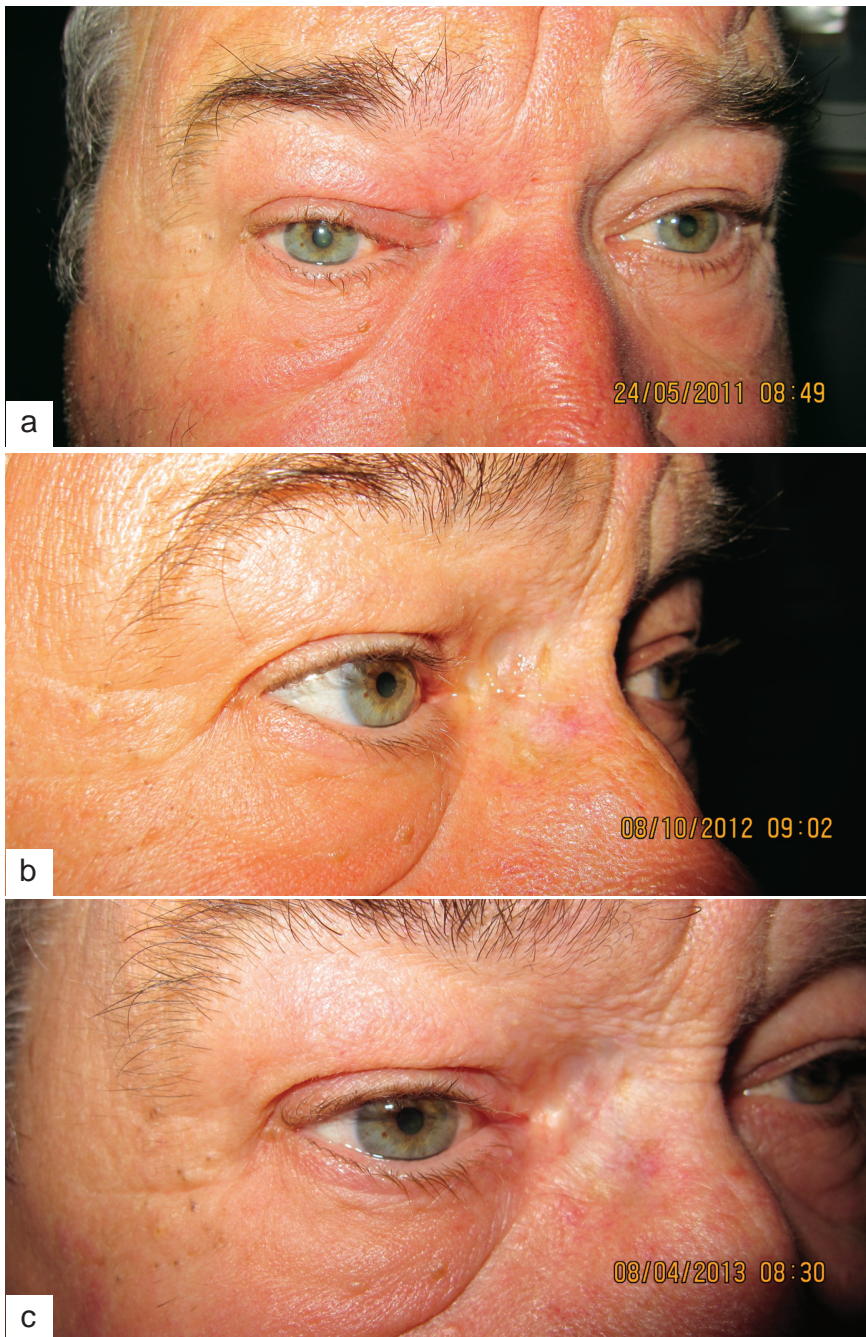
## DISCUSSION

Data on recurrences after surgical tre-

atment of basal cell carcinoma differs, depending on the use of the operating technique. In the studies known to us, published over the course of the last 10 years, the incidence of recurrences in patients treated without the use of Mohs micrographic surgery or “en-face” frozen incisions preoperatively was within the range of 1.8% to 39%, in the case of longer monitoring of patients the rate of recurrences increased. In epidemiological and clinical studies we find a slight predominance of incidence in men. Within the framework of the possible causes we may consider the smaller amount of attention devoted by this part of the Slovak population to the occurrence of “cosmetic” lesions on the face from the perspective of the layman. The most frequent incidence of recurrences is on the lower eyelid. Local treatment (Imiquimod – Aldara) in localisation close to the margin of the eyelid or the lateral or medial angle is not yet widely used (3, 16, 17).



**Fig. 6.** Patient with recurring basal cell carcinoma of medial angle of left eye before treatment – November 2010 after treatment without recurrence, persisting ectropion – May 2012



**Fig. 7.** Patient with microscopically positive resection edge after excision of basal cell carcinoma of the medial angle of the right eye  
 a) 6 months after brachytherapy erythema of skin persists in the radiation-treated area  
 b) 22 months after completion of brachytherapy  
 c) 29 months after completion of brachytherapy

Reconstructive surgeries and plastic surgeries of eyelids following removal of tumour are currently elaborated to the level of a displacement of the chondromucosal septal flap from the upper eyelid. Despite this the orbital exenteration remains one of the alternatives of resolving of an advanced stage of the process (10).

HDR  $^{192}\text{Ir}$  brachytherapy was developed in the treatment of basal cell and squamous cell carcinoma of the

eyelids in the 1990s. Newer methods of brachytherapy are applied in the treatment of nonmelanotic lesions on the face using the method of HDR electronic brachytherapy (electronic BT). However, the first reports of HDR brachytherapy in the treatment of basal cell carcinomas of the eyelids did not appear until 2007 (11).

Guix (9) referred to 136 patients with basal cell carcinoma or spinocellular carcinoma in the facial area. Nineteen

patients were treated using standard Brock applicators and 117 patients were treated using individually made polymethylmethacrylate applicators obtained by making a casting of the patient's face. For lesions with a size of up to 4 cm the minimum dose was 60 to 65 Gy in a dose to a fraction of 1.8 Gy (EQD2 58.4-63.7 Gy), which is a slightly higher dose than we used on our patients. Lesions larger than 4 cm were irradiated up to a total dose of 75-80 Gy (EQD2 72 – 78 Gy). In the entire group they recorded 3 recurrences, only one patient suffered recurrence upon treatment of the primary tumour, in two patients this concerned relapse in the case of recurrent tumours. At a time interval of 5 years 98% of patients were without recurrence, for patients with primary tumours the 5-year local check-up showed 99% without recurrence, for patients with recurrent tumours 87%. Tolerance of the treatment was excellent in all cases, no serious, early or later complications were detected. The radiobiologically converted total dose in the treatment scheme we used in the treatment plan (10 fractions of 4.5 Gy) was lower in comparison with the above-presented work (EQD2 54.4 v.s. EQD2 58.4 Gy) and also brought a complete remission of the disorder. However, the short monitoring period (2 years) and the small number of our patients unfortunately does not enable us to evaluate this therapeutic regime reliably with regard to effectiveness.

## CONCLUSION

Within the framework of ophthalmology, increased attention is being devoted to the problem of malignant nonmelanocytic tumours of the eyelids, because in the case of growth into the orbit, an untreated tumour may cause loss of the eye or even orbital exenteration. Primary surgical treatment and subsequent reconstructive surgery of advanced stages represents a repeatedly serious aesthetic intervention.

Radiotherapy represents a highly effective modality in the treatment of skin carcinomas in the facial area. Adjuvant brachytherapy is the method of choice in the case of incomplete excisions or of recurring nonmelanocytic malignant tumours of the eyelids. Our first experience demonstrates that no recurrence of basal cell carcinoma occurred within the monitored interval of 2 years after treatment.

## LITERATURE

1. Allali J, D'Hermes F, Renard G: Basal Cell Carcinoma of the Eyelids. *Ophthalmologica*, 219; 2005: 57–71.
2. Bhatnagar A.: Nonmelanoma skin cancer treated with electronic brachytherapy: Results at 1 year. *Brachytherapy*, 9.január 2013, in press, dostupné na internete <http://www.sciencedirect.com/science/article/pii/S153847211200236X>.
3. Carter KD, Nerad JA, Whitaker DC: Clinical factors influencing periocular surgical defects after Mohs micrographic surgery. *Ophthalm Plast Reconstr Surg* 15; 1999: 83–91.
4. Ducasse A, Pluot M, Gotzamanis A, Brugnart C, Leccia L, Rossi P: Factors of recurrence of basal cell carcinomas of the eyelid. *J Fr Ophthalmol* 25(5); 2002: 512–516.
5. Furdová A.: Bazocelulárny karcinóm mihalnic [elektronický dokument]. i-med.sk, 2012, dostupné na internete: ISSN 1338–4392.
6. Furdová, A., Oláh, Z.: *Nádory oka a okolitých štruktúr*, CERM, Brno, 2010, 151 s.
7. Furdová, A., Strmeň, P., Oláh, Z.: Použitie TNM-klasifikácie v oftalmológii. *Choroby hlavy a krku, Head and Neck Diseases*, 2 (9); 2000: 17–25.
8. Furdová, A., Svetlošáková, Z.: Bazaliómy v oblasti oka a mihalnic. *Dermatológia pre prax*, 3, 2009, 115–117.
9. Guix B, Finestres F., Tello JI, Palma C, Martínez A., Guix JR, Guix R.: Treatment of skin carcinomas of the face by high-dose-rate brachytherapy and custom-made surface molds. *International Journal of Radiation Oncology\*Biophysics*, 47 (1); 2000: 95–102.
10. Chynoranský, M., Furdová, A., Oláh, Z.: Exenterácie očnice. *Čes a Slov Oftalmol*, 50 (2); 1994: 92–97.
11. Monge RM, Gómez-Iturriaga A: High-dose-rate brachytherapy in lower eyelid cancer. *Brachytherapy*, 6 (3); 2007: 227–229.
12. Nemet AY, Deckel Y, Martin PA, Kourt G, Chilov M, Sharma V, Benger R: Management of periocular basal and squamous cell carcinoma: a series of 485 cases. *Am J Ophthalmol*, 142; 2006: 293–297.
13. Ondrušová M, Pleško I, Safaei-Diba Ch, Obšitníková A, Štefaňáková D, Ondruš D: Komplexná analýza výskytu a úmrtnosti na zhubné nádory v Slovenskej republike [online]. *Národný onkologický register SR, NCZI, 2007* [cit. 27.2.2009]. <http://www.nor-sk.org/>.
14. Paavilainen V, Tuominen J, Aho VV, Saari KM: Long-term results after treatment of basal cell carcinoma of the eyelid in South-Western Finland. *Eur J Ophthalmol*: 17(4); 2007: 494–500.
15. Paavilainen V, Tuominen J, Pukkala E, Saari KM: Basal cell carcinoma of the eyelid in Finland during 1953–97. *Acta Ophthalmol Scand* 83(2); 2005: 215–220.
16. Sigurdsson H, Agnarsson BA: Basal cell carcinoma of the eyelid. Risk of recurrence according to adequacy of surgical margins. *Acta Ophthalmol Scand* 76(4); 1998: 477–480.
17. Wong VA, Marshall JA, Whitehead KJ, Williamson RM, Sullivan TJ: Management of periocular basal cell carcinoma with modified en face frozen section controlled excision. *Ophthalm Plast Reconstr Surg* 18(6); 2002: 430–435.