

# COMPARISON OF THERAPEUTIC RESULTS OF MONOCANALICULAR AND BICANICULAR INTUBATION FOR CONGENITAL NASOLACRIMAL DUCT OBSTRUCTION

Červenka S.<sup>1,2,3</sup>, Matoušek P.<sup>2,3</sup>,  
Komínek P.<sup>2,3</sup>

<sup>1</sup>Lacrima Eye Centre Ltd. Otrokovice

<sup>2</sup>Department of Otorhinolaryngology and Head and Neck Surgery, University Hospital Ostrava

Head physician: prof. MUDr. P. Komínek, Ph.D., MBA

<sup>3</sup>Faculty of Medicine, Department of Craniofacial Surgery, University of Ostrava  
Head: prof. MUDr. P. Komínek, Ph.D., MBA

*The authors of the study declare that no conflict of interest exists in the compilation, theme and subsequent publication of this professional communication, and that it is not supported by any pharmaceuticals company.*

MUDr. Stanislav Červenka, Ph.D.  
Lacrima oční centrum, s.r.o.  
tř. Osvobození 1388  
765 02 Otrokovice  
e-mail: cervenka.s@volny.cz

## SUMMARY

**Purpose:** To compare the success rate of monocanalicular (MI) and bicanalicular intubation (BI) in congenital nasolacrimal duct obstruction (CNLDO).

**Methods:** MI through the inferior canaliculus and BI were performed under general anaesthesia in children from 7 to 24 months old with CNLDO. Only children after unsuccessful conservative therapy and two and more probings were included in the study. The tubes were removed 3 months after intubation and the therapeutic success was evaluated 6 months after intubation.

**Results:** There were performed 139 MI in 114 children and 119 BI in 88 children. The success rate 6 months after intubation is 135/139 (97.1%) in MI, 114/119 (95.8%) in BI and the difference in therapeutic results between MI and BI is not significant ( $p = 0.737$ ).

**Conclusion:** Silicone intubation is an effective procedure for treating CNLDO without difference in therapeutic success between MI and BI.

**Key words:** congenital nasolacrimal duct obstruction (CNLDO), monocanalicular intubation (MI), bicanalicular intubation (BI)

Čes. a slov. Oftal., 72, 2016, No. 5, p. 178–181

## INTRODUCTION

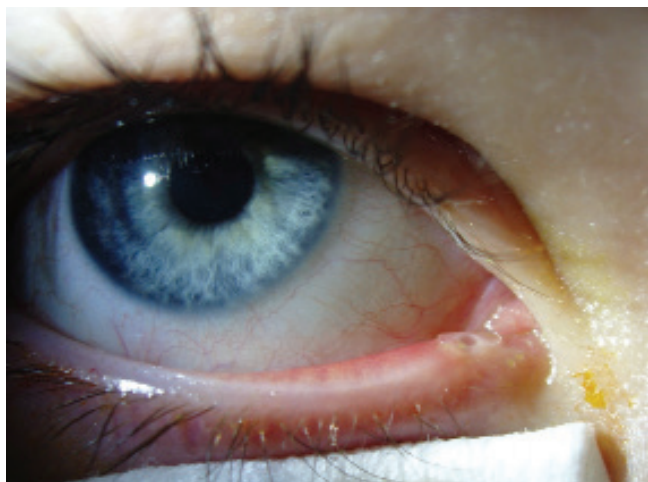
Intubation of the nasolacrimal duct with a silicone cannula in the case of CNLDO is a procedure indicated as a rule following unsuccessful conservative therapy and repeated probings. The principle of the operation consists in breaching the obstruction in the nasolacrimal duct and temporary introduction of a silicone cannula into the lacrimal pathways. The cannula acts here as a stent, i.e. it maintains their lumen, but does not secure drainage itself. The silicone cannula may be introduced via both lacrimal canaliculus, referred to as bicanicular intubation (BI), which was first performed in the 1970s [22]. The cannula may also be introduced only through one canaliculus, the superior or the inferior, which is referred to as monocanalicular intubation (MI), and this was first presented in the 1990s [7]. Today both MI and BI are used in the treatment of CNLDO [3, 5, 6, 7, 8, 13, 14]. As a result the aim of our study is to compare the therapeutic results of both of these surgical techniques.

## METHODOLOGY

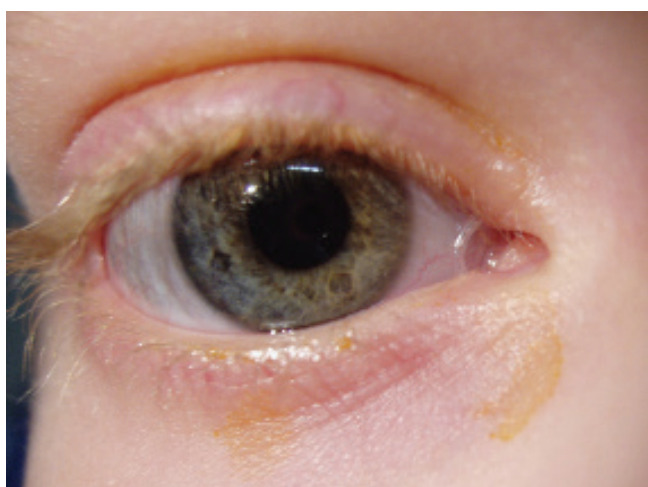In the period from 2006 – 2009, 139 MI procedures were performed via the inferior canaliculus (fig. 1) on 114 children, and 119 BI procedures (fig. 2) were performed on 88 children at the Department of Otorhinolaryngology and Head and Neck Surgery at the University Hospital in Ostrava. The indication for surgery was congenital nasolacrimal duct obstruction following unsuccessful conservative therapy and after 2 or more unsuccessful probings. The study

included children aged 7 – 24 months at the time of surgery, and cases with previously performed intubation, balloon dilation of the nasolacrimal duct or dacryocystorhinostomy were excluded. Conditions with defects of the position and function of the eyelids, with pathologies of the lacrimal puncta and canaliculi, craniofacial anomalies, amniocoele, acute dacryocystitis and children with Down's syndrome were also not assessed. All operations were performed under general anaesthesia in co-operation with an ophthalmologist and otorhinolaryngologist, using rigid nasal endoscopes, and in all cases monocanalicular and bicanicular intubation sets from the firm ELLA-CS s.r.o. Hradec Králové were used. The children were examined in outpatient care 1, 3 and 6 months after intubation. At all follow-up examinations the condition of lacrimation and secretion of the ocular aperture was determined, and drainage of the lacrimal pathways was always examined using a fluorescein dye disappearance test (FDT). Lacrimation and secretion of the ocular aperture were evaluated subjectively by the parents and objectively by the doctor (lacrimation – present, absent, secretion – present, absent), and FDT was evaluated according to Meyer et al. [16] as negative (FDT 0) – full drainage, slightly positive (FDT 1) – partial drainage, and highly positive (FDT 2) – without drainage. The cannulas were removed always under local anaesthesia 3 months after the operation, and the therapeutic effect of intubation was defined as a condition without subjective or objective manifestations of lacrimation and secretion of the ocular aperture simultaneously with full drainage of the lacrimal pathways (FDT 0).

In the statistical evaluation, a non-parametric Wilcoxon



**Fig. 1** Monocanalicular intubation of right eye, silicone cannula in the lower lacrimal point.



**Fig. 2** Bicanalicular Intubation of right eye, silicone cannula between the lacrimal points.

test was used for comparison of the average age in MI and BI. Evaluation of the therapeutic effect of MI and BI 6 months after intubation was performed using a Pearson's chi-squared test for two selections, and if the condition for its use was not met the results were processed using a Fisher's exact test. The statistical tests were evaluated on a level of significance of 5 %.

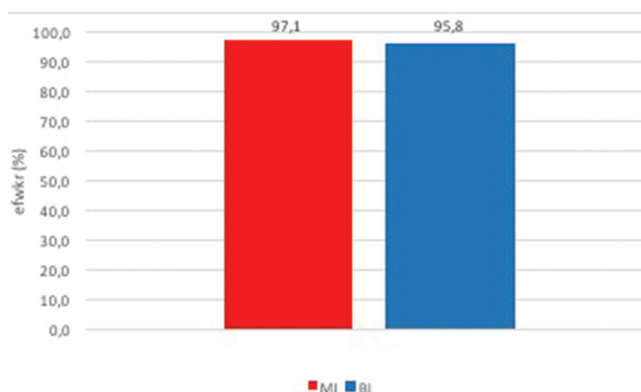
## RESULTS

258 silicone intubations of the nasolacrimal duct were evaluated, of which MI of the inferior canaliculus 139/258 (54%) and BI 119/258 (46%). The youngest patient at the time of surgery was aged 7 months, the oldest 24 months, and no statistically significant difference was determined between the mean age of the children undergoing MI (11.4 months) and BI (11.2 months) ( $p=0.191$ ). At a follow-up examination 6 months after intubation, the therapeutic effect in the case of MI via the inferior canaliculus is 135/139 (97.1%), for BI 114/119 (95.8%) (fig. 3), and there is no sta-

tistically significant difference between the two types of intubation ( $p=0.737$ ).

## DISCUSSION

Silicone intubation of the nasolacrimal duct was first described by Quickert and Dryden in 1970, and became the standard procedure in the treatment of congenital nasolacrimal duct obstruction [1 – 10, 13, 14, 17, 22]. As a rule conditions following unsuccessful conservative therapy and one or more probings are indicated for intubation, and these are also the indication criteria used in our evaluated cohort [1, 4, 9, 14, 25]. However, sometimes intubation may be performed as the first intervention procedure without prior probings [5, 6]. The operation is performed under general anaesthesia with the possible use of an endoscopic technique [3, 12, 13, 17, 20, 23]. Use of endoscopes enables the performance of a large part of the operation under visual control, thereby improving its quality and reducing the time of the procedure. All our intubations were performed in this manner, in standard co-operation of an ophthalmologist and otorhinolaryngologist. MI may be introduced via both the upper [6, 8, 10], and inferior lacrimal canaliculus [13, 14]. At our centre we chose the inferior canaliculus for MI, because we primarily use this in diagnosis and surgery of the lacrimal pathways.



**Fig. 3** Curative effect of monocanalicular (MI) and bicanalicular intubation (BI)

Several studies have dealt with the therapeutic effect in intubation. However, most of these evaluate each type of intubation separately, and the effect in the case of MI is within the range of 67.6% to 97.1%, and for BI from 62.2% to 100.0% [8, 10, 13, 17, 21, 25]. It is difficult to compare the results mainly due to the lack of uniformity concerning the definition of the effect. Some consider the effect to be merely the absence of lacrimation or secretion of the eye, or both simultaneously [8, 14], others describe it as a subsidence of clinical symptoms with generated drainage of the lacrimal pathways [6, 21, 25]. Sometimes the effect is divided into full, partial and none [10, 13]. In our evaluation we defined the therapeutic effect "strictly" as a condition without subjective or objective manifestations of lacrimation and secretion of the ocular aperture, simultaneously with full drainage of the lacrimal pathways as confirmed by

FDT.

Some authors directly compare the therapeutic results of both types of intubations. Lee et al. evaluate 30 MI procedures via the inferior canaliculus and 30 BI. The average age upon performance of MI was 23.1 months, and in the case of BI 23.3 months. All cannulas in the case of MI were removed under local anaesthesia, in the case of BI 66.7% of cannulas were removed under general anaesthesia. The authors define the therapeutic effect as a "complete subsidence of symptoms" with a result of 90.0% for MI and 93.3% for BI, in which no significant difference is found between the two types of intubation [14]. Komínek et al. present a cohort of 35 MI via the inferior canaliculus and 35 BI in children aged 10 – 30 months. The cannulas were removed under local anaesthesia 3 – 4 months after intubation, and the therapeutic effect was defined as full subsidence of symptoms or only residual symptoms always with FDT 0-1. The success rate for MI is 97.1%, for BI 88.6%, and no statistically significant difference was found between the two techniques [13]. Fayet et al. processed a cohort of 43 MI via the upper anal and 77 BI. Average age at the time of operation for all intubations was 5.4 years, and on average the cannulas were removed 5.1 months after intubation in the case of MI, and 7.0 months after intubation for BI. A final condition without lacrimation was evaluated with a result of 67.6% for MI and 62.3% for BI, a condition of intermittent lacrimation in 23.6% for MI and 30.2% for BI, and a condition of persistent

lacrimation in 8.8% for MI and 7.5% for BI [8].

The main discussed issue is a comparison between the therapeutic effect of MI and BI in congenital nasolacrimal duct obstruction. The above studies, which directly compare the effect of both types of intubation find no statistically significant difference between the two techniques [13, 14]. The results of our evaluation also are without any significant difference between the two types of intubation, with an effect of 97.1% for MI and 95.8% for BI. A certain advantage of MI is work only on one lacrimal canaliculus. The entire procedure is thereby less demanding in terms of time in comparison with BI, presents a lower risk of damage to both canaliculi, and the removal of the cannula is also simpler. For these reasons at our centre we have a slight preference for MI, which is the method of first choice upon intubation of the nasolacrimal duct.

## CONCLUSION

Upon congenital nasolacrimal duct obstruction, MI and BI rank among the standard procedures in the lacrimal pathways. The therapeutic effect of these operations is high, without a significant difference between the two techniques. Selection of the type of intubation is within the competence of the operating team, taking into account the technical facilities, experience and customs of the given centre.

## LITERATURE

1. **Beigi, B., O'Keefe, M.:** Results of Crawford tube intubation in children. *Acta Ophthalmol*, 71; 1993: 405–407.
2. **Crawford, J.S.:** Intubation of obstruction in the lacrimal system. *Canad J Ophthalmol*, 12; 1977: 289–292.
3. **Červenka, S., Komínek, P.:** Silikonová intubace – léčba komplikovaných stavů vrozené neprůchodnosti slzných cest. *Čes a Slov Oftal*, 53(2); 1997: 122–127.
4. **Dortzbach, R.K., France, T.D., Kushner, B.J., et al.:** Silicone intubation for obstruction of the nasolacrimal duct in children. *Am J Ophthalmol*, 94; 1982: 585–590.
5. **El-Essawy, R.:** Effect of timing of silicone tube removal on the result of duct intubation in children with congenital nasolacrimal duct obstruction. *Ophthal Plast Reconstr Surg*, 29(1); 2013: 48–50.
6. **Engel, J.M., Hichie-Schmid, C., Khammar, A., et al.:** Monocanalicular silastic intubation for the initial correction of congenital nasolacrimal duct obstruction. *J AAPOS*, 11; 2007: 183–186.
7. **Fayet, B., Bernard, J.A.:** A monocanalicular stent with self-stabilizing meatic fixation in Sumery of excretory lacrimal ducts. Initial results. *Ophthalmologie*, 4; 1990: 351–357.
8. **Fayet, B., Bernard, J.A., Assouline, M., et al.:** Bicanalicular versus monocanalicular silicone intubation for nasolacrimal duct impotency in childhood. *Orbit*, 12; 1993: 149–156.
9. **Goldstein, S.M., Goldstein, J.B., Katowitz, J.A.:** Comparison of monocanalicular stenting and balloon dacryoplasty in secondary treatment of congenital nasolacrimal duct obstruction after failed primary probing. *Ophthal Plast Reconstr Surg*, 20; 2004: 352–357.
10. **Kaufman, L.M., Guay-Bhatia, L.A.:** Monocanalicular intubation with Monoka tubes for the treatment of congenital nasolacrimal duct obstruction. *Ophthalmology*, 105; 1998: 336–341.
11. **Komínek, P., Červenka, S., Novák, V.:** Intubace odvodných slzných cest – přehled některých technik. *Čes a Slov Oftal*, 53(1); 1997: 32–39.
12. **Komínek, P., Červenka, S., Novák, V.:** Intubation of the lacrimal pathways. *Ophthalmologica*, 214; 2000: 381–384.
13. **Komínek, P., Červenka, S., Pniak, T., et al.:** Monocanalicular versus bicanalicular intubation in the treatment of congenital nasolacrimal duct obstruction. *Graefes Arch Clin Exp Ophthalmol*, 249; 2011: 1729–1733.
14. **Lee, H., Ahn, J., Lee, J.M., et al.:** Clinical effectiveness of monocanalicular and bicanalicular silicone intubation for congenital nasolacrimal duct obstruction. *J Craniofac Surg*, 23(4); 2012: 1010–1014.
15. **Lim, C.S., Martin, F., Beckenham, T., Cumming, R.G.:** Nasolacrimal duct obstruction in children: outcome of intubation. *J AAPOS*, 8; 2004: 466–472.
16. **Meyer, D.R., Antonello, A., Linberg, J.V.:** Assessment of tear drainage after canalicular obstruction using fluorescein dye disappearance. *Ophthalmology*, 97; 1990: 1670–1674.
17. **Migliori, M.E., Putterman, A.M.:** Silicone intubation for the treatment of congenital lacrimal duct obstruction: successful results removing the tubes after six weeks. *Ophthalmology*, 95; 1988: 792–795.
18. **Noda, S., Hayasaka, S., Setogawa, T.:** Congenital nasolacrimal duct obstruction in Japanese infants: its incidence and treatment with massage. *J Pediatr Ophthalmol Strab*, 28; 1991: 20–22.
19. **Nucci, P., Capoferri, C., Alfarano, R., et al.:** Conservative management of congenital nasolacrimal duct obstruction. *J Pediatr Ophthalmol Strab*, 26; 1989: 39–43.
20. **Pediatric Eye Disease Investigator Group.:**

- Primary treatment of nasolacrimal duct obstruction with nasolacrimal duct intubation in children younger than 4 years of age. *J AAPOS*, 12; 2008: 451–455.
21. **Pelit, A., Caylakli, F., Yaycioglu, R.A., et al.:** Silicone intubation with the Ritleng method using intranasal endoscopy to treat congenital nasolacrimal duct obstruction. *Int J Pediatr Otorinolafyngol*, 73; 2009: 1536–1538.
  22. **Quickert, M.H., Dryden, R.M.:** Probes for intubation in lacrimal drainage. *Tr Am Acad Ophth Otol*, 74; 1970: 431–433.
  23. **Ratliff, C.D., Meyer, D.R.:** Silicone intubation without intranasal fixation for treatment of congenital nasolacrimal duct obstruction. *Am J Ophthalmol*, 118; 1994: 781–785.
  24. **Takahashi, Y., Kakizaki, H., Chang, W.O., et al.:** Management of congenital duct obstruction. *Acta Ophthalmol*, 88; 2010: 506–513.
  25. **Welsh, M.G., Katowitz, J.A.:** Timing of silastic tubing removal after intubation for congenital nasolacrimal duct obstruction. *Ophthal Plast Reconstr Surg*, 5(1); 1989: 43–48.