

# Ocular Disturbances as the First Sign of Decompensated Arterial Hypertension

A. Stepanov, J. Studnička, L. Hejsek,  
N. Jirásková, P. Rosival

Department of Ophthalmology, University Hospital Hradec Králové  
Head: prof. MUDr. Pavel Rozsival, CSc., FEBO

## SUMMARY

Arterial hypertension is a serious health problem. Decompensation of blood pressure may cause many ocular complications. We present three case reports of men with decompensated blood pressure and associated ocular complications. Successful compensation of blood pressure leads to objective improvement of fundus changes and vision.

**Key words:** arterial hypertension, hypertonic angiopathy, retinopathy, neuropathy

Čes. a slov. Oftal., 70, 2014, No. 5, p. 190–194

## INTRODUCTION

We indicate repeated increase of blood pressure (BP) > 140/90 mmHg measured minimally at two different visits (21) as arterial hypertension. In its high prevalence within the adult population, arterial hypertension represents a serious health problem. In Western industrial countries approximately every second adult lives with blood pressure higher than 140/90 mmHg (12), and overall hypertension afflicts approximately one billion people worldwide (4, 20, 22). The Czech Republic ranks amongst those countries with a high incidence of this disorder. In a randomly selected population sample within the age range of 25–64 years, a 40% prevalence of hypertension was determined, at the age above 65 years hypertension afflicts minimally 60% of the population (5). Hypertension may manifest itself asymptotically for several years before it damages the functions of organs, and its clinical course is mostly without symptoms. Only upon a massive increase in pressure do non-specific complaints such as headache, dizziness and epistaxis occur. If hypertension is not diagnosed in a timely manner, it is often not manifested until the occurrence of complications, for example changes on the ocular fundus.

Hypertonic retinopathy is a condition characterised by a spectrum of retinal changes in patients with high systemic arterial blood pressure (16). It was first described by Liebricht in 1859 (11). Data from various international

studies shows that signs of hypertonic retinopathy are present in 3–14% of adult individuals aged > 40 years (7, 8, 9, 15, 16, 18, 19, 20). A higher incidence has been determined in men (13). Timely identification of hypertonic retinopathy is an important step in stratification of the risk in patients with hypertension (2, 3).

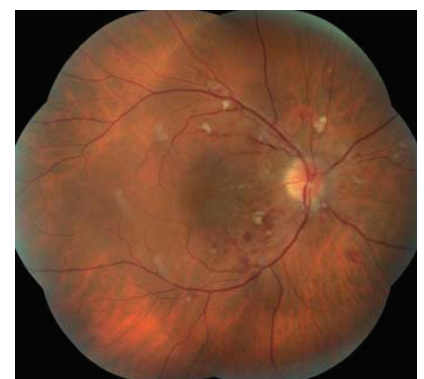The usual characteristics of chronic hypertonic retinopathy are: constriction of the arterioles, cotton wool spots, flame-shaped surface haemorrhages, hard exudates and macular edema. In the case of malignant hypertension we also observe signs of neuropathy and choroidopathy on the ocular fundus. The majority of these changes abate over time in the case of compensation of blood pressure (10).

## CASE REPORT 1

The patient, a 39 year old man, was examined at the Department of Ophthalmology at the University Hospital in Hradec Králové due to deterioration of vision in the right eye. From the anamnesis it ensues that the patient had hitherto been treated for dyslipidemia and had regularly used Simvcard 40 mg in a dose of 1 tablet per day. He had experienced headaches for approximately six months without other accompanying complaints. His body mass index was 35.3. His previous ocular anamnesis was without any remarkable features. He had noticed ocular complaints for 14 days and perceived a progressively increasing black stain in the centre of the visual field of the right eye. Initial best corrected visual acuity (BCVA) in the

right eye was 20/50. Visual acuity of the left eye was 20/32, and was not improved by correction. Upon measurement of blood pressure, values of 190/130 mmHg were determined.

The finding in the anterior segment of the eye was bilaterally commensurate to age. Cotton wool spots dominated on the ocular fundus, with blurred edges of the discs of the optic nerve and diffuse intraretinal haemorrhages. Constriction of the retinal arterioles and their increased tortuosity, positive phenomena of crossing was determined in the capillaries. In the central region there was bilateral indication of a star-shaped figure, hard exudates, in the right eye with swelling of the macula (fig. 1, 2). Optical coherence tomography (OCT) (HD OCT Cirrus, Zeiss) of the central region of the right eye demonstrated a finding of loose liquid between the neuroretina and



**Fig. 1** Right eye. Disc of the optic nerve with blurred edges. Cotton wool spots and diffuse intraretinal haemorrhages. In the central region there is an indication of a star-shaped figure, macular edema.

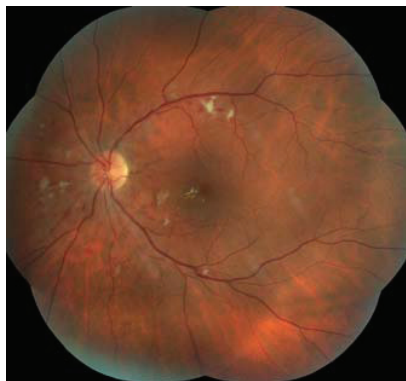

Fig. 2 Similar finding on ocular fundus of left eye

the retinal pigment epithelium (RPE), neuroretinal edema, which continued to the papilla (fig. 3). Central retinal thickness (CRT) was 569  $\mu\text{m}$ . In the left eye the finding on OCT of the macula was commensurate to age. The patient was sent to the Internal Clinic at the University Hospital Hradec Králové for configuration of antihypertensive therapy. Further observation of the development of the disorder was not possible, because the patient did not attend the planned follow-up.

## CASE REPORT 2

The patient, a 59 year old man, was admitted for further examination of an ocular finding at the Department of Ophthalmology at the University Hospital Hradec Králové, due to deterioration of vision in both eyes. He had hitherto been treated generally for psoriasis, which had been stable for the last 20 years, and stated pains in the shoulder joints and cervical spine. For approximately two months he had observed a deterioration of vision in both eyes. Initial BCVA in the right eye was 20/80, in the left 20/100. On the day of admittance, upon measurement of BP values of 210/120 mmHg were determined. On the anterior segment of the eye the bilateral finding was commensurate to age. Upon an examination of the ocular fundus we determined blurred edges and congested discs of the optic nerve, linking to several cotton wool spots. In both eyes there was evident swelling of the macula, in the periphery of the retina we observed diffuse intraretinal haemorrhages, constriction of the

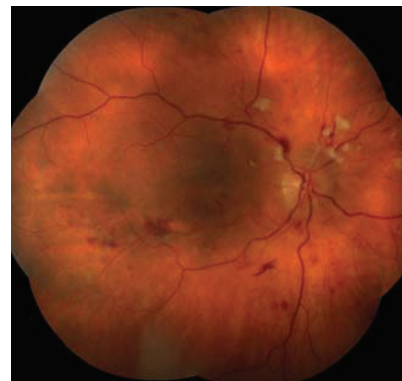

Fig. 4 Right eye. Pronounced hypertensive retinopathy, stage 3-4 according to Keith.

retinal arterioles and their increased tortuosity, with positive phenomena of crossing (fig. 4). Optical coherence tomography of the central region bilaterally showed cystic neuroretinal edema (fig. 5). Central retinal thickness (CRT) of the right eye was 463  $\mu\text{m}$ , in the left eye 600  $\mu\text{m}$ . We concluded a condition of hypertensive neuroretinopathy with macular edema bilaterally. The patient was transferred according to his place of residence to the Cardiology Department at the Pardubice Regional Hospital for the configuration of antihypertensive therapy. At a follow-up examination one month after the commencement of general therapy: Agen 5 mg (amilpdpine) 0-0-1, Loradur (amiloride 5 mg and hydrochlorothiazide 50 mg)  $\frac{1}{2}$ -0-0, Betaloc SR 200 mg (metoprolol)  $\frac{1}{2}$ -0-0, blood pressure was compensated to values of 130/85 mmHg and the patient started an improvement of vision. BCVA in the right eye was 20/63, in the left eye 20/80. On the ocular fundus we recorded a regression of the finding – in the macula of the right eye the edema had virtually receded and the size and scope of intraretinal haemorrhage had been reduced bilaterally (fig. 6). The OCT finding on the central region confirmed regression of macular edema (fig. 7).

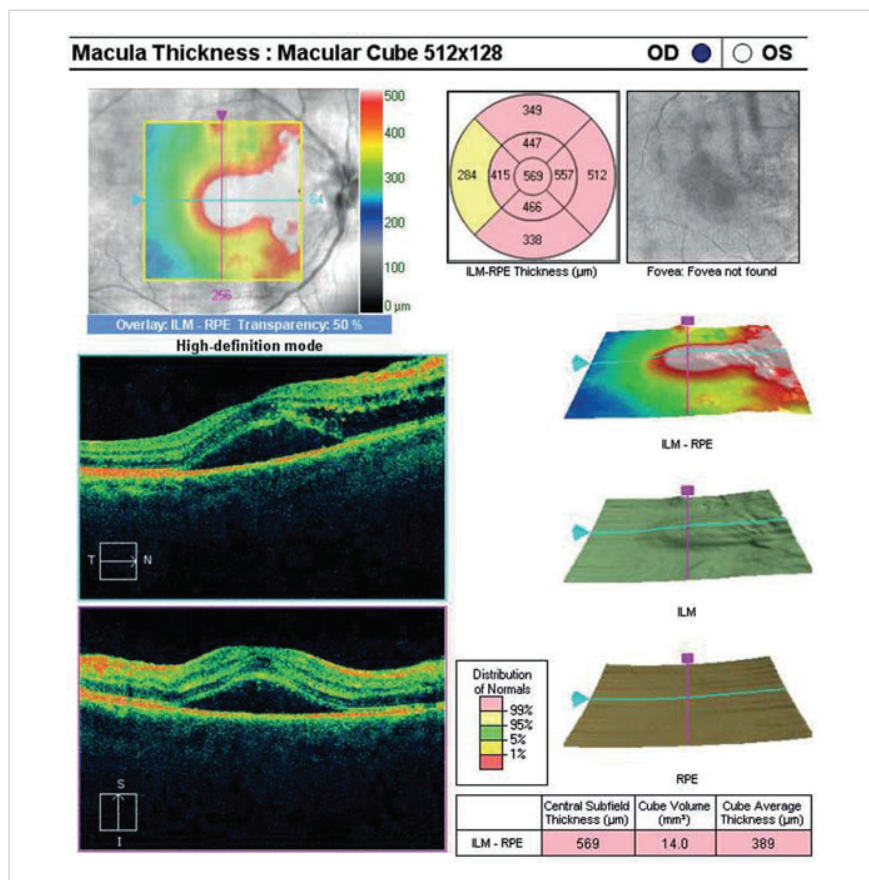
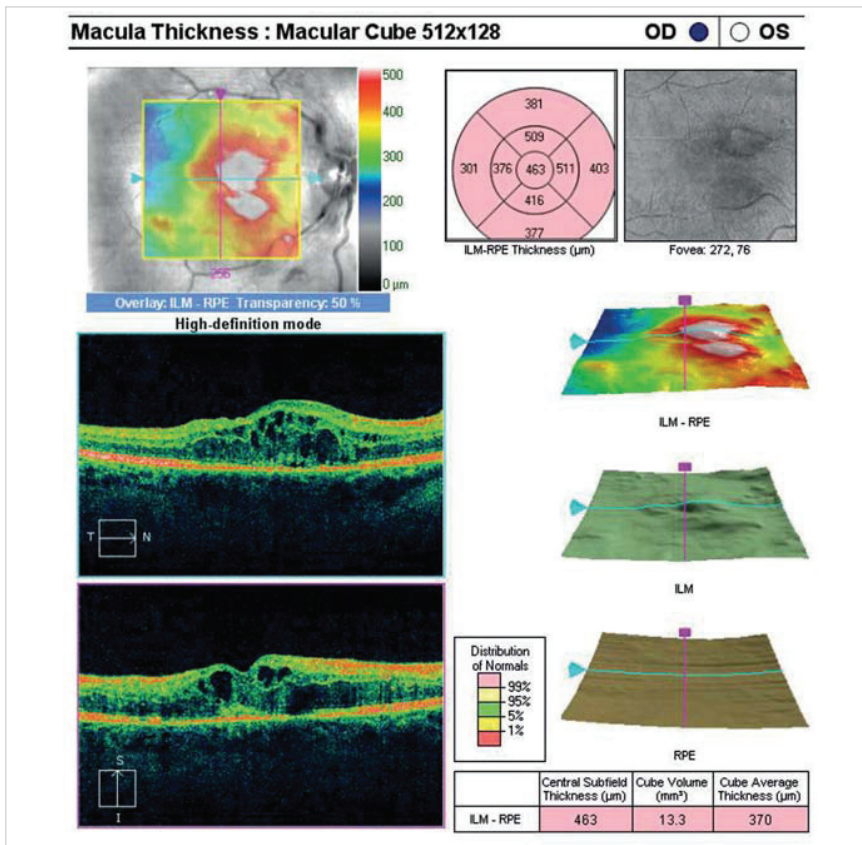


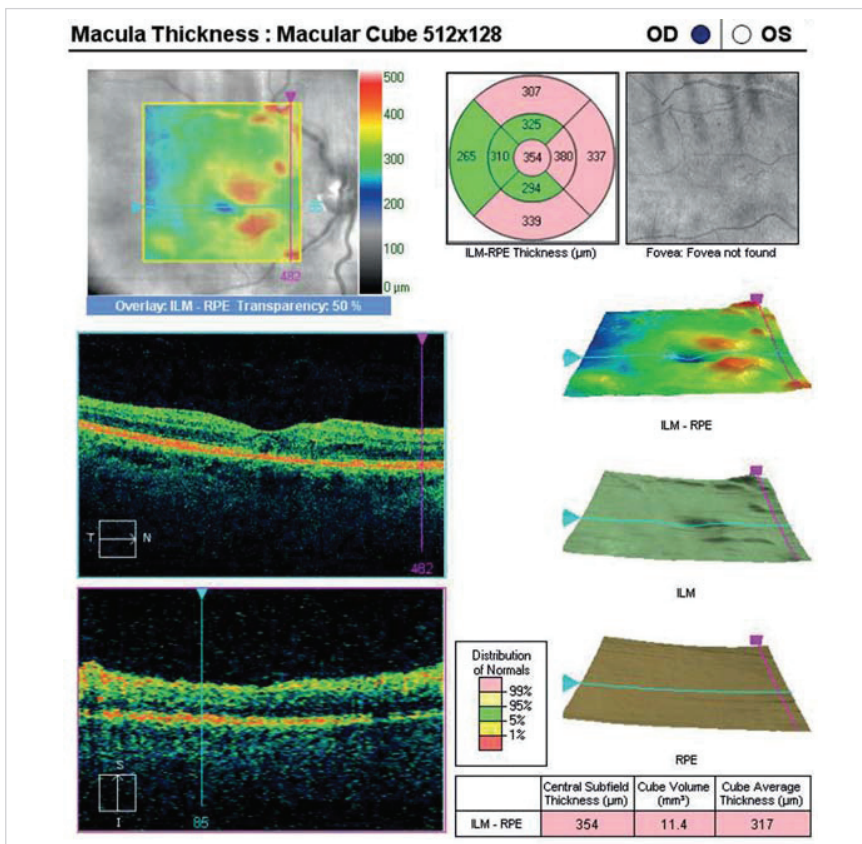
Fig. 3 OCT of central region of right eye. Finding of loose liquid between neuroretina and retinal pigment epithelium (RPE), neuroretinal edema, which continues in the direction towards the disc of the optic nerve.

## CASE REPORT 3

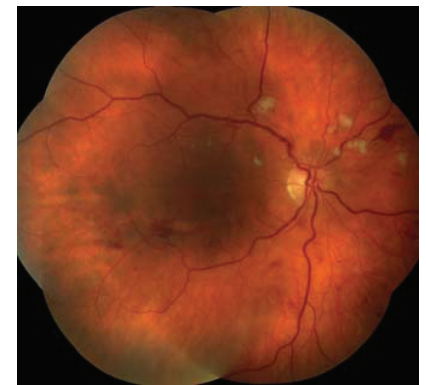The patient, a 40 year old man, was sent to the Department of Ophthalmology at the University Hospital Hradec Králové for examination of the ocular fundus following one week of antihypertensive therapy. From the anamnesis it ensued that for approximately one month the patient had noticed respiratory difficulties, a dry cough and tightening of the chest. At the Internal Clinic at the University Hospi-



**Fig. 5** OCT of central region of right eye. Cystic neuroretinal edema.

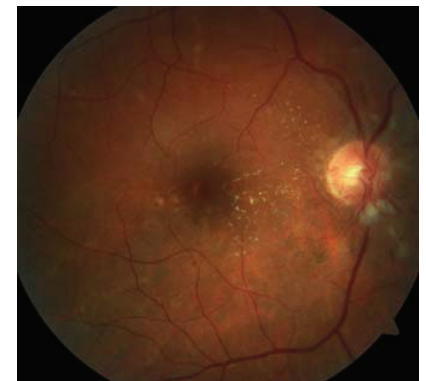

**Fig. 7** OCT of central region of right eye. Regression of neuroretinal edema, foveolar depression formed.

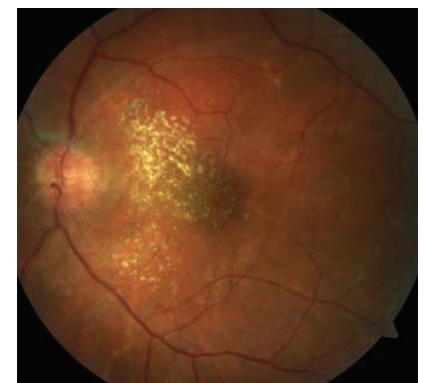


**Fig. 6** Right eye. Regression of finding, edema virtually receded in central region, size and scope of intraretinal haemorrhage decreasing

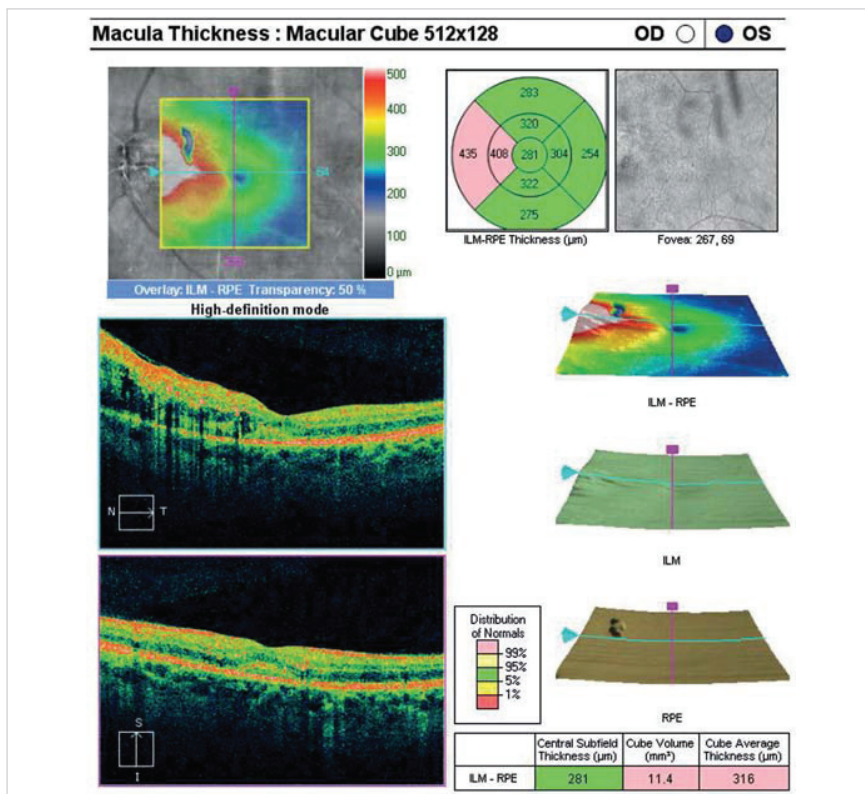
tal Hradec Králové he was examined with the following conclusion: malignant hypertension with blood pressure values of 250/170 mmHg. An x-ray examination of the chest showed an enlargement of the width of the heart shadow, finding of engorgement and exudation in the left lung. Due to the above complaints, the following therapy was initiated: Bisoprolol 2.5 mg 1-0-0, Verospiron 25 mg 1-0-0 (spi-



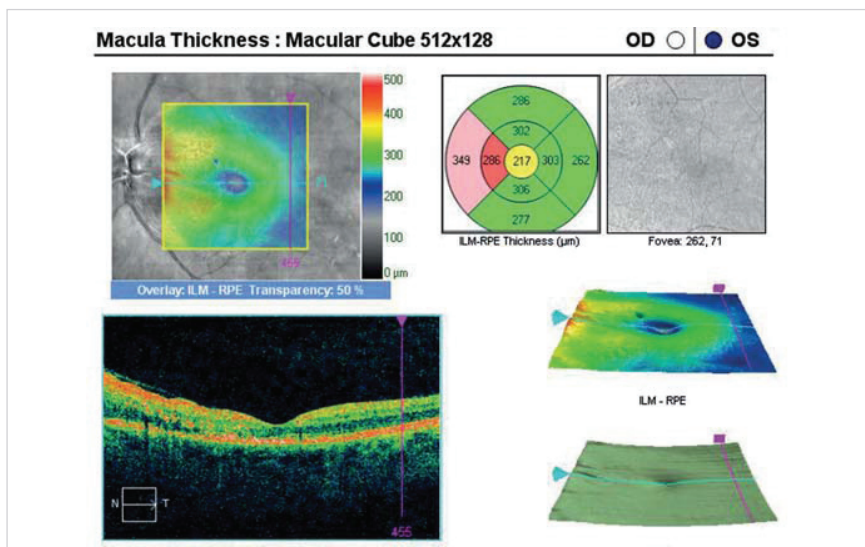
**Fig. 8** Right eye. Pronounced hypertensive retinopathy, stage 3 according to Keith. Dominant accentuation of capillary network on papilla.



**Fig. 9** Analogous finding on ocular fundus of left eye with more pronounced exudation in macula.



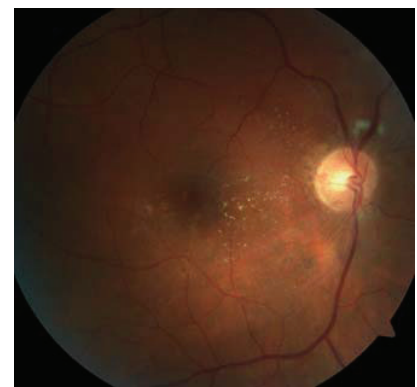**Fig. 10** OCT of central region of left eye. Neuroretinal edema, which continues in the direction towards the disc of the optic nerve.



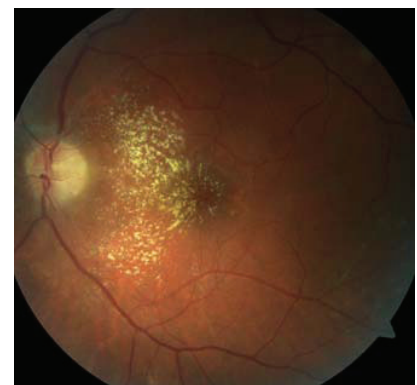
**Fig. 13** OCT of central region of left eye. Regression of neuroretinal edema.

**Table 1** Keith-Wagener-Barker classification.

Level 1	Slight constriction, sclerosis and tortuosity of arterioles
Level 2	Medium to pronounced constriction of arterioles
	Disappearance of ophthalmoscopic reflexes
	Positive phenomenon of crossing
Level 3	Stenosis of retinal arterioles and focal constriction of capillaries
	Retinal swelling
	Cotton wool spots
	Retinal haemorrhage
Level 4	All features of group 3 plus edema of papilla of optic nerve



**Fig. 11** Right eye. Improvement of condition following compensation of blood pressure.



**Fig. 12** Left eye. Improvement of condition.

ronolactone), Cardilopin 10 mg -0-0 (amlodipine). Of ocular complaints the patient perceived deterioration of visual acuity in the left eye persisting for one month. Initial BCVA in the right eye was 20/20 in the left eye 20/40. At our examination blood pressure was already compensated – 130/85 mmHg. The finding on the anterior segment of the eye was bilaterally commensurate to age. Accentuation of the capillary network on the papillas dominated on the ocular fundus, with isolated peripapillary cotton wool spots. In the capillaries we observed pronounced sclerotic changes, arteries with an appearance of silver wire, veins wide with pronounced phenomena of crossing. In the central region there were evident hard exudates and splattered haemorrhages (fig. 8, 9). Optical coherence tomography of the central region of the left eye showed neuroretinal edema in the direction from the papilla to the macula (fig. 10). In the right eye the finding on OCT of the central region was commensurate to age. At a follow-up examination after one month, BCVA was unchanged, but there was a visible improvement of the objective condition on the ocular fundus. The capillary network on the

papillars was no longer so pronounced, there was a bilateral reduction in the size and scope of the cotton wool spots and intraretinal haemorrhage, although hard exudates were still evident. At this follow-up examination, blood pressure was compensated to values of 125/80 mmHg. On OCT of the left eye we observe a regression of neuroretinal edema (fig. 13).

## DISCUSSION

According to the level of BP at the first measurement (without medication), we differentiate between 1st degree arterial hypertension (slight hypertension) with BP values of 140-159/90-99 mmHg, 2nd degree hypertension (medium-severe) with BP 160/179/100-109 mmHg and 3rd degree hypertension (severe arterial hypertension) with BP values of > 180/110 mmHg (12). In our case we recorded 3rd degree arterial hypertension in all patients. Arterial hypertension may be the source

of numerous ocular complications. Some are entirely without symptoms and are generally determined by chance at a routine eye examination, others cause mild to severe loss of vision of the afflicted eye. The first and broadest classification of hypertensive changes on the ocular fundus is the classification according to Keith (6) (table 1). In the cases we present, we recorded severe changes on the ocular fundus bilaterally in all patients, according to Keith degree 3-4.

With successful treatment of hypertension, changes on the retina and on the disc of the optic nerve can recede completely, however, arterial constriction and the phenomenon of crossing are irreversible (10). In our cases numbers 2 and 3 also, at the planned follow-up following compensation of blood pressure vision improved and there was a partial regression of pathological changes on the ocular fundus.

As regards local ocular therapy, in the case of malignant hypertension

with pronounced papillary edema, the effectiveness of intravitreal injection of VEGF (Vascular Endothelial Growth Factor) inhibitors is demonstrated (1). In the patients we described, this option was not chosen due to the absence of pronounced papillary edema and the regression of the pathological changes following compensation of arterial hypertension.

## CONCLUSION

In certain cases, ocular complaints are the first sign of decompensation of arterial hypertension. The treatment of arterial hypertension requires good co-operation between the ophthalmologist and the internist. With successful treatment of hypertension, changes on the retina and on the disc of the optic nerve can regress completely. In the cases we present, following compensation of blood pressure there was an improvement of vision and the objective finding on the ocular fundus.

## LITERATURE

1. **Abdelrahman, GS.:** Intravitreal bevacizumab in persistent retinopathy secondary to malignant hypertension. *Saudi J Ophthalmol*, 2013; 27: 25-29.
2. **Grosso, A., Veglio, F., Porta, M. et al.:** Hypertensive retinopathy revisited: some answers, more questions. *Br J Ophthalmol*, 2005; 89: 1646-1654.
3. **Chatterjee, S., Chattopadhyaya, S., Hope-Ross, M. et al.:** Hypertensive and the Eye: changing perspective. *J Hum Hypertens*, 2002; 16(10): 667-75.
4. **Chobanian, AV.:** Control of hypertension—an important national priority. *N Engl J Med*, 2001; 345: 534-535.
5. **Filipovský, J., Widimský, J., Ceral, J. et al.:** Diagnostické a léčebné postupy u arteriální hypertenze. Kapitoly z kardiologie, 2013.
6. **Keith, N., Wagener, HP., Banker, N.:** Some different types of essential hypertension. Their course and prognosis. *AMJ Med Sci*, 1939; 197: 332.
7. **Klein, R., Klein, BEK., Moss, SE.:** The relation of systemic hypertension to changes in the retinal vasculature. The Beaver Dam Eye Study. *Trans Am Ophthalmol*, 1997; 95: 329-350.
8. **Klein, R., Klein, BEK., Moss, SE. et al.:** Hypertension and retinopathy, arteriolar narrowing and arteriovenous nicking in a population. *Arch Ophthalmol*, 1994; 112: 92-98.
9. **Klein, R., Sharrett, AR., Klein, BEK et al.:** Are retinal arteriolar abnormalities related to atherosclerosis? The Atherosclerosis in Communities Study. *Arterioscler Thromb Vasc Biol*, 2000; 20: 1644-1650.
10. **Kumudini, S., Vikas, K., Priyadarshini, M. et al.:** Hypertensive retinopathy. *Clinical Queries Nephrology*, 2013; 2: 136-139.
11. **Liebreich, R.:** Ophthalmoscopic findings in Bright's disease. *Albrecht von Graefes Arch Ophthalmol*, 1859; 5: 265-268.
12. **Mancia, G., Fagard, R., Narkiewicz, K et al.:** ESH-ESC Guidelines 2007 Leitlinien der European Society of Hypertension. *J Hypertension*, 2007; 25: 1751-1762.
13. **Ojaimi, E., Nguyen, TT., Klein, R. et al.:** Retinopathy signs in people without diabetes. The multi-ethnic study of atherosclerosis. *Ophthalmology*, 2011; 118: 656-662.
14. **Sharp, PS., Chaturvedi, N., Wormald, R. et al.:** Hypertensive retinopathy in Afro-Caribbeans and Europeans. Prevalence and risk factor relationships. *Hypertension*, 1995; 25: 1322-1325.
15. **Stolk, RP., Vingerling, JR., de Jong, PT. et al.:** Retinopathy, glucose, and insulin in an elderly population. The Rotterdam Study. *Diabetes*, 1995; 44: 11-15.
16. **Walsh, JB.:** Hypertensive retinopathy: description, classification and prognosis. *Ophthalmology*, 1982; 89: 1127-1131.
17. **Wang, JJ., Mitchell, P., Leung, H. et al.:** Hypertensive retinal vessel wall signs in the general older population: the Blue Mountains Eye Study. *Hypertension*, 2003; 42: 534-541.
18. **Wong, TY., Klein, R., Sharret, AR. et al.:** The prevalence and risk factors of retinal microvascular abnormalities in older people. The Cardiovascular Health Study. *Ophthalmology*, 2003; 110: 658-666.
19. **Yu, T., Mitchell, P., Berry, G. et al.:** Retinopathy in older persons without diabetes and its relationship to hypertension. *Arch Ophthalmol*, 1998; 116: 83-89.
20. **Gorelick, PB.:** New horizons for stroke prevention PROGRESS and HOPE. *Lancet Neurology*, 2002; 1: 149-156.
21. **Karen, I., Widimský, J.:** Doporučené postupy pro praktické lékařství, Doporučení diagnostických a léčebných postupů u arteriální hypertenze., 2008, Společnost všeobecného lékařství, U Hranic 16, Praha 10.
22. **Wolf-Maier, K., Cooper, RS., Banegas, JR. et al.:** Hypertension prevalence and blood pressure levels in 6 European countries, Canada, and the United States. *JAMA*, 2003; 289: 2363-2369.