

Frosted Branch Angiitis Syndrome

K. Janurová¹, P. Žiak¹, M. Šesták¹, D. Sanchez-Chicharro¹, R. Šafrová²

¹Department of Ophthalmology, Jesenius Faculty of Medicine, Comenius University in Martin and University Hospital Martin

Head: MUDr. Peter Žiak, PhD.

²Dr. R. Šafrová Ophthalmology Outpatient Clinic, Trstená

First author:

MUDr. Katarína Janurová

Department of Ophthalmology, Jesenius Faculty of Medicine, Comenius University and University Hospital Martin Kollárova 2

036 59 Martin

Slovenská republika

e-mail: katarina.kabacova@seznam.cz

SUMMARY

The authors present a case report of a 20-year-old patient with an atypical clinical picture of bilateral vasculitis associated with bilateral macular oedema and decrease in visual acuity. On basis of the clinical picture, frosted branch angiitis was diagnosed. The patient was instructed to continue the broad-spectrum antibiotic therapy prescribed by an ophthalmic practitioner of the appropriate catchment area. The visual acuity progressively improved and after application of systemic corticosteroid therapy the patient's health state improved completely.

According to the author's knowledge, this is the first diagnosed case of frosted branch angiitis in the Slovak Republic.

Key words: frosted branch angiitis, vasculitis, angiitis

Čes. a slov. Oftal., 70, 2014, No. 5, p. 201–205

INTRODUCTION

Bilateral vasculitis in a 6 year old Japanese boy was described by Ito et al. in 1976. The clinical picture of vasculitis was reminiscent of frosted tree branches, and as a result the authors used the name frosted branch angiitis (1). This pathology has not been described to date in Slovakia. In the Czech Republic Říhová et al. first described this pathology in 2004, and proposed the name frosted branches of retinal blood vessels syndrome (2).

Frosted branch angiitis syndrome is clinically manifested as anterior uveitis, vitritis and vasculitis. The branches of the retinal blood vessels are coated with an inflammatory infiltrate from the disc of the optic nerve (DON) to the periphery, with veins afflicted more frequently than arteries. Upon examination by fluorescence angiography (FAG), symptoms of later infiltration from blood vessels are present, but without symptoms of vascular occlusion. In the later stages, geographic atrophic lesions have been observed in the periphery of the retina in some patients. The majority of authors state a very good therapeutic effect of generally administered corticosteroids. Frosted branch angiitis syndrome most frequently afflicts young and healthy individuals. Some of these have overcome influenza a number of weeks before the ocular complaints (1).

Kleiner (1997) noted the fact that similar ocular findings as in frosted branch angiitis syndrome may occur also in patients with a systemic or hematologic pathology, in immunocompetent or immunodeficient individuals in connection with infection, most frequently viral (3).

If infiltration of the blood vessels is caused by malignant cells upon lymphoma or leukaemia, this represents a syndrome similar to frosted branches. If the finding is a manifestation of immune complex vasculitis caused by a viral infection or autoimmune disease, the pathology is referred to as secondary vasculitis with frosted branches. If the etiological agent is not demonstrated, this represents acute idiopathic vasculitis with frosted branches (4). In this case, vasculitis is caused by immune processes triggered by as yet unclear stimuli.

In our study we present a case report of a patient with a clinical picture of frosted branch angiitis syndrome.

CASE REPORT

A healthy 20 year old man overcame a viral pathology of the upper respiratory tracts in mid-December 2008. 4 weeks later, in mid-January 2009, he was examined due to bilateral deterioration of vision persisting for 3 days at the outpatient clinic of the district ophthalmologist. The district ophthalmologist determined a working diagnosis of bilateral diffuse retinitis of unclear etiology, and recommended

the following therapy for the patient: generally Rovamycin 3 MIU, 1 tablet every 12 hours, Tebokan 1 tablet 3x daily, and Unicophlen drops (gtt.) 5x daily applied locally to both eyes. Due to the unusual ocular finding and diagnostic inconclusiveness, the patient was advised to attend an examination at the Department of Ophthalmology of the Jesenius Faculty of Medicine of Comenius University and the University Hospital in Martin the next day.

The patient was examined in the outpatient department of the Department of Ophthalmology of the Jesenius Faculty of Medicine of Comenius University and the University Hospital in Martin on 16 January.

The personal anamnesis of the 20 year old man was negative, except for the current deterioration of vision and the virus 4 weeks previously. As a student of the military academy, he had regularly undergone health checks (including ocular examination) before contracting the disease, without a pathological finding. We did not record any more serious ocular or systemic pathologies in the family anamnesis.

From an ophthalmological perspective, the patient had not experienced any ocular complaints to date. Upon the first examination at our outpatient clinic, natural vision was bilaterally 6/38, best corrected visual acuity (BCVA) bilaterally 6/18. Intraocular pressure was within the norm (12 and 13 mmHg). There were mild sym-

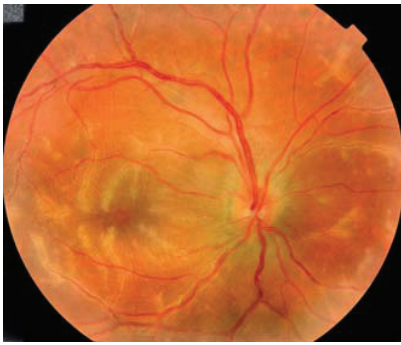


Fig. 1 Right eye of patient upon admittance
Inflammatory infiltrates around the branches of the retinal blood vessels, DON with slightly blurred boundaries at the upper and lower pole. BCVA: 6/18.

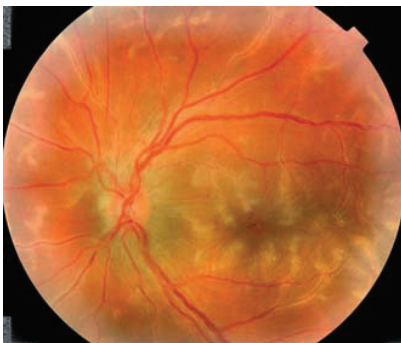

Fig. 2 Left eye of patient upon admittance
Inflammatory infiltrates around the branches of the retinal blood vessels, DON with slightly blurred boundaries at the upper and lower pole, with retinal haemorrhages in the centre of the macular region. BCVA: 6/18.

ptoms of anterior uveitis bilaterally in the anterior segment (minor non-granulomatous precipitates on the corneal endothelium, cells in the anterior chamber), the pupils were loose, without posterior synechiae, the lenses clear. The vitreous body was slightly turbid, DON edematous, the macular region edematous, inflammatory infiltrates dominated in the clinical picture around the branches of the retinal blood vessels, accompanied by retinal haemorrhages (fig. 1, 2).

Upon examination by optical coherence tomography (OCT) (Stratus, Zeiss), the foveolar contour was preserved, the neuroretina in the region of the fovea was coarsened, elevated, with present non-reflective cystoid cavities. Thickness of foveola in the right eye was 507 μm , in the left eye 552 μm (fig. 3).

In the examination we determined a working diagnosis of frosted branch angiitis syndrome, and the patient was hospitalised. We focused further laboratory and general examinations on determining the specific type of the syndrome and excluding or confirming the infectious etiology of vasculitis, or its connection with a haematological or other general pathology.

On the basis of the fact that the infiltrates around the branches of the retinal blood vessels did not appear unilaterally but bilaterally, and the examination of the blood count and differential blood count was within the framework

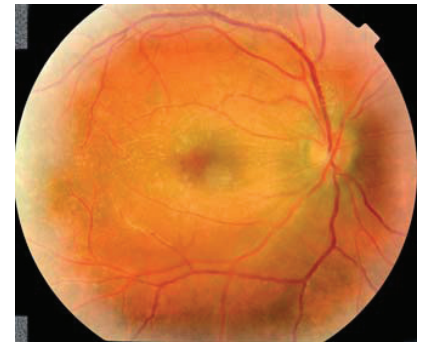


Fig. 4 Right eye of patient on 4th day of hospitalisation
Inflammatory infiltrates reduced, haemorrhages partially reabsorbed

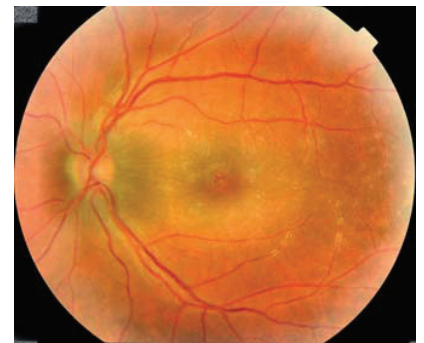


Fig. 5 Left eye of patient on 4th day of hospitalisation
Inflammatory infiltrates almost entirely reabsorbed, haemorrhages partially reabsorbed

of physiological values, we excluded infiltration of the blood vessels with malignant cells on the day of admittance. This did not concern a haematological pathology, but immune complex vasculitis, without a demonstrated etiological agent. Despite the fact that the majority of authors (1, 3, 5, 8, 10, 11, 12) state an improvement of the clinical picture and vision in this clinical unit following periocularly and generally administered corticoids, due to the potential influence on the results of flow cytometry, we did not apply corticotherapy until the 4th day of hospitalisation (upon an improvement of the finding also without corticotherapy).

Upon admittance we added Ibalgin 400 mg 1 tablet 3x daily and Ascorutin 2 drg. 3x daily to the treatment stipulated by the district ophthalmologist (Rovamycin 3 MIU, 1 tablet every 12 hours, Tebokan 1 tablet 3x daily, Unicophlen gtt. 5x daily applied locally to both eyes). Within the first days of observation, best corrected visual acuity and the finding on the ocular fundus improved markedly. On the 4th day of hospitalisation, BCVA had improved bilaterally to 6/12 before

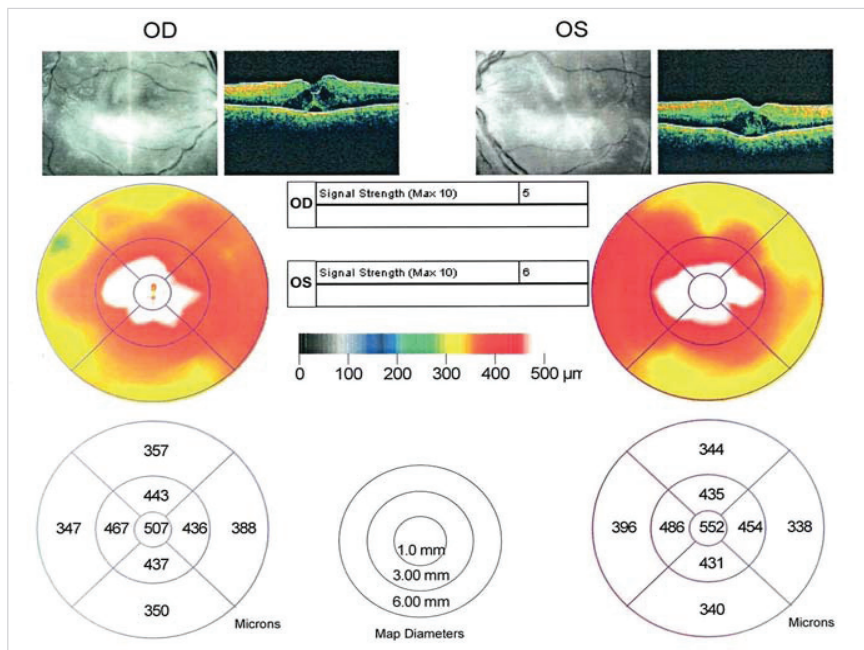


Fig. 3 OCT finding of patient upon admittance
Preserved foveolar contour, neuroretina elevated in the region of the fovea, with cystoid non-reflective cavities. Thickness of foveola in right eye 507 μm , in left eye 552 μm .

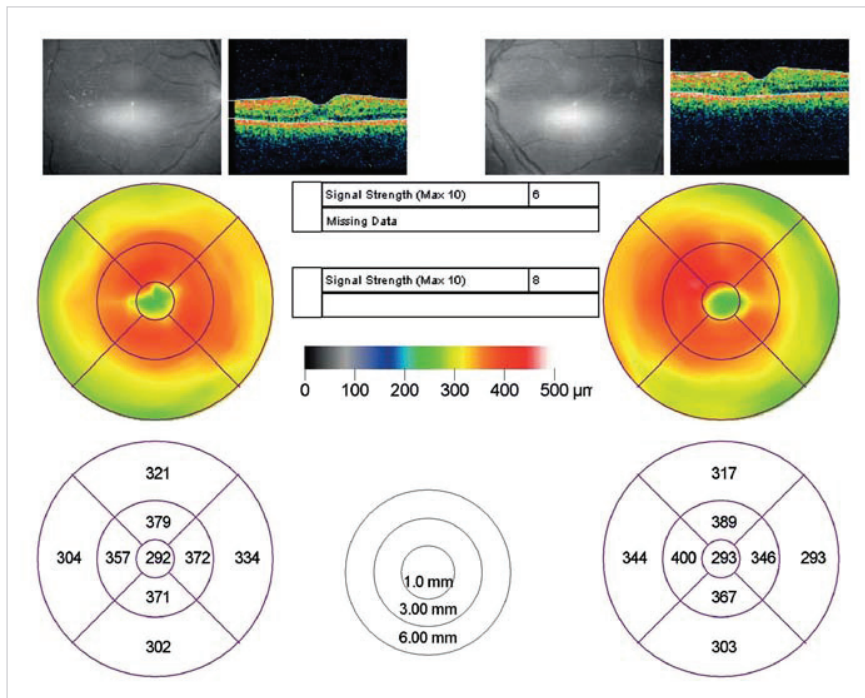


Fig. 6 OCT images of patient on 4th day of hospitalisation
Decrease in edema in foveola in right eye by 215 μm, in left eye by 259 μm

the application of corticotherapy, the inflammatory infiltrates had virtually disappeared, and the haemorrhages had been partially reabsorbed (fig. 4, 5). Edema in the foveola of the right eye had decreased by 215 μm, in the left eye by 259 μm (fig. 6). Despite the partial improvement in the ocular finding, we implemented

rapy we continued with Prednisone 1 mg/kg/day, following adjustment of the ocular finding we began to reduce the dose of Prednisone on the 7th day by 10 mg every 3 days, to a maintenance dose of 10 mg every second day, generally for a period of 2 months. During therapy by corticoids we did not record any second-

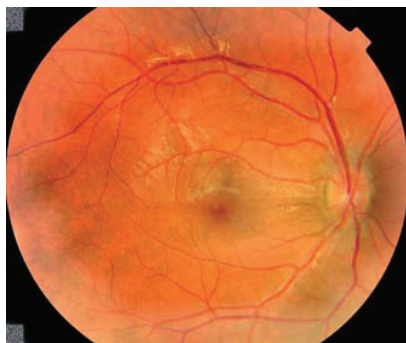

Fig. 7 Right eye of patient at first follow-up examination after discharging DON bordered, pink, without edema, inflammatory exudates to haemorrhages completely disappeared, frilling of lamina limitans interna, slight

the planned commencement of corticotherapy following the taking of a blood samples for examinations of flow cytometry and phagocytic activity on the 4th day of hospitalisation. Over the course of three days, we intravenously applied Solumedrol in a dose of 250 mg/day. In corticother-

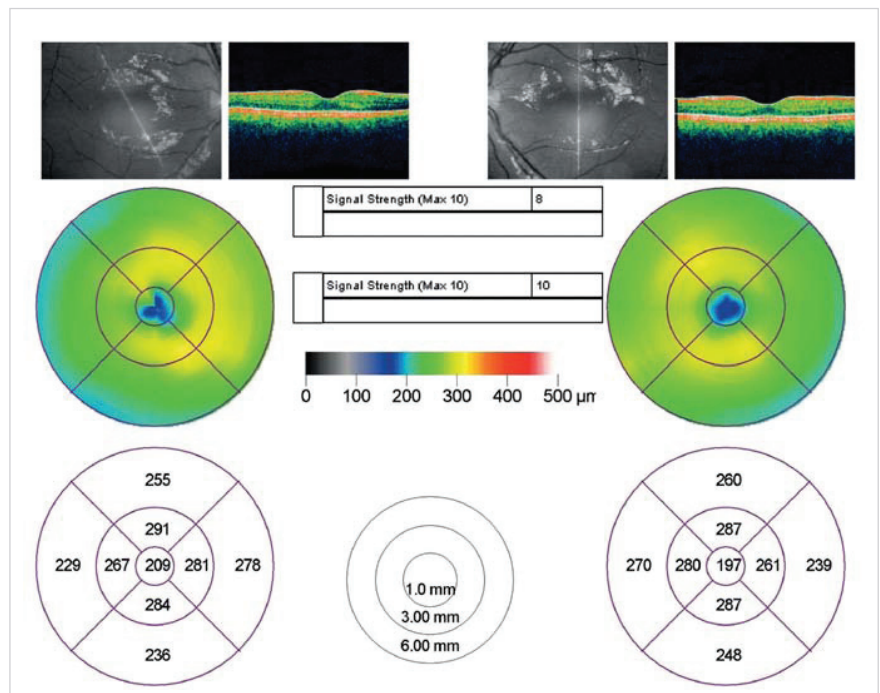


Fig. 9 OCT finding of patient at first follow-up examination after discharging Physiological finding, neuroretina without edema, without cystoid non-reflective cavities or microcystic remodelling

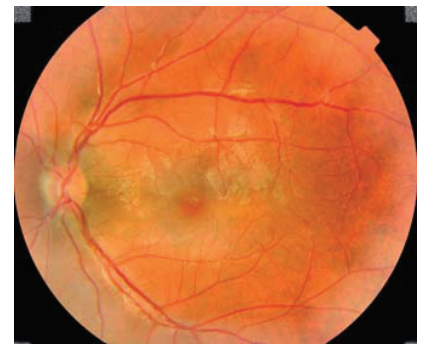

Fig. 8 Left eye of patient at first follow-up examination after discharging DON bordered, pink, without edema, inflammatory exudates to haemorrhages completely disappeared, in macula frilling of lamina limitans interna, slight atrophy of RPE in foveolar region.

ry adverse effects or complications. The result of electrophoresis of proteins in serum, the immunochemical examination, examination of flow cytometry, phagocytic activity and the quantiferon test excluded immune disorder. Rheumatoid factor, anti-nuclear antibodies (ANA) and anti-neutrophil cytoplasmic antibodies (ANCA), serological examination of antibodies against borrelias, mycoplasmas, yersinias, herpes simplex virus (HSV), herpes zoster virus (HZV), cytomegalovirus (CMV), Epstein-Barr virus (EBV), rubella and VDRL were negative.

Within the framework of differential diagnostics to eliminate sarcoidosis performed by X-ray examination of the chest, pneumological examination and examination of cellular immune status from bronchoalveolar lavage on the recommendation of a pneumologist, the results were however also negative. Positive findings were antibodies of class IgA and IgG against *Chlamydia trachomatis*. As a result an infectologist was consulted, who despite the completion of the course of Rovamycin once more recommended re-treatment of the patient with Deoxymykoin in a dose of 100 mg 2x daily. At the first follow-up examination after discharging on 9 February 2009, BCVA was 6/4 bilaterally, the anterior segment was physiological, without symptoms of inflammation, the vitreous body clear, DON bordered, pink, retinal blood vessels were without symptoms of vasculitis, exudates completely reabsorbed, with only slight atrophy of the retinal pigment epithelium (RPE) in the foveolar region, in the entire macula frilled lamina limitans interna, other finding without pathology, haemorrhages completely reabsorbed (fig. 7, 8). According to the OCT images foveolar contour is present, cystoid non-reflective cavities are not present, neither is microcystic remodelling of the neuroretina (fig. 9). At a further follow-up examination after six months the patient is subjectively without ocular complaints, corrected visual acuity bilaterally 6/4, local finding without change.

DISCUSSION

Frosted branch angiitis syndrome was first observed in Japan in 1976 (1). The largest proportion of patients is amongst the Japanese (75%). Until 1988 no patient outside Japan had been diagnosed with this condition (5). The patient we present is the first described case in Slovakia. The disorder usually afflicts younger, otherwise healthy individuals. In 2004, Walker presented characteristic bimodal distribution with one peak in childhood age and the second in the third decade of life (5). The youngest patient in whom frosted branch angiitis syndrome has been diagnosed was 2 years old (8), and the oldest 42 (10). There is a marked predominance of women (61%) in the number of cases as opposed to men (39%). Our patient was a man aged 20 years, and with the exception of the fact that he had overcome influenza approximately one

month before the first symptoms of deterioration of vision, he had not been treated for any condition.

The most frequently occurring symptom of frosted branch angiitis syndrome is subacute loss of vision. Visual acuity may be substantially reduced, even to mere light perception. Almost 75% of patients in the described cases were afflicted bilaterally. Typical frosted branch angiitis syndrome has a conspicuous basic image, bilateral retinal vasculitis with perivascular exudates, with an image of frozen branches. The branches of the retinal blood vessels are coated from the disc of the optic nerve to the periphery, with veins affected more frequently than arteries. Intraretinal haemorrhages are sometimes also present, with mild to medium uveitis and vitritis. According to the scope of the pathology, infiltration of the macula and edema of the disc of the optic nerve may be present. On the basis of the data from the literature, we believe that our patient met the criteria for frosted branch angiitis syndrome. Upon examination by fluorescence angiography (FAG), symptoms of later infiltration from the blood vessels are usually present, but without reduced flow of blood or symptoms of vascular occlusion. In the acute phase of the disorder we did not implement FAG examination for technical reasons.

The majority of authors (1, 3, 5, 8, 10, 11, 12) state a very good therapeutic effect of generally administered corticosteroids. However, on the basis of their experiences, Kadoya et al. (6), Isoe et al. (7), Browning et al. (9), Yoshida et al. (13), Narita et al. (14), Vander et al. (15) and others have expressed doubts with regard to the significance of corticosteroids in the case of this disorder. Browning (9) described a unilateral mild form of frosted branch periphlebitis in a healthy, 28 year old woman. Regression of papillitis and vasculitis occurred following a subconjunctival injection of 30 mg Triamcinolone. Vander et al. (15) describe a regression of vasculitis only following local therapy by corticosteroids. In our patient we recorded a rapid improvement of visual functions and the objective finding before the commencement of corticotherapy. The patient used antiphlogistics and antibiotics generally. Positive antibodies of class IgA and IgG against *Chlamydia trachomatis* were determined. Rovamycin recommended by the district ophthalmologist may have been effective.

Following the completion of the course of Rovamycin, the patient was re-treated with Deoxymykoin upon the recommendation of the infectologist.

An image of vasculitis with a clinical picture of frozen branches of retinal blood vessels has also been described in patients with a general disorder. Ridley et al. (16) determined a diagnosis of large-cell intraocular lymphoma on the basis of an examination of a sample of the vitreous body in 1992. Kim et al. (17) described a unilateral image of this syndrome in an 18 year old patient with acute lymphoblastic leukaemia. Quillen et al. (18) described this syndrome in a 37 year old man with Crohn's disease, as did Jokhura et al. (19) in a female patient with aseptic meningitis. Generally administered corticoids had a favourable influence on the ocular and neurological symptoms. Further studies point to a possible connection between retinal vasculitis and an infectious etiology. Greek authors (20) demonstrated HSV2 in a 30 years old man with vasculitis with frozen branches in the anterior chamber fluid using the PCR method. Recurrence of the pathology has not yet been described.

We do not have any information from our patient, who is currently working abroad, concerning general or ocular complaints. According to the available data, the prognosis is not always favourable. Kleiner et al. (4) describe the formation of disciform scars in a patient with frosted retina periphlebitis. They also described later complications, neovascularisations as a consequence of vein occlusion and in one patient they recorded a retinal crack, with ablation of the posterior vitreous membrane with adhesion to the retina. Ito et al. (1) describe atrophy of the DON. From the works published to date, it is evident that a clinical picture of retinal vasculitis with frozen branches may be caused by various diseases. Kleiner noted this fact in 1997 (3). On the basis of the data from the literature, we believe that in our patient this concerned a case of secondary vasculitis with frozen branches, with positive serology for *Chlamydia trachomatis*.

CONCLUSION

The precise cause of frozen branch angiitis syndrome is unknown. The typical inception following a multifactorial prodromal pathology leads to the presupposition that this concerns a hypersensitive reaction to various infectious

agents, which may trigger the origin of frozen branch angiitis syndrome via the formation of immune complexes. In patients with a severe disruption of central visual acuity, this fact supports an indication for systemic corticotherapy. Because the results of central visual acuity in patients with or without syste-

mic corticotherapy are not clear, to date no criteria have been set for treatment by corticoids in a patient with frozen branch angiitis syndrome. It is necessary to consider frozen branch angiitis syndrome to be a clinical ocular syndrome or a clinical symptom of a general pathology. It is necessary to approach

patients with this pathology individual and to investigate the possible cause. Until the determination of the etiology, it is necessary to consider the method of treatment on the basis of the seriousness of the deterioration in central visual acuity and also of the clinical picture.

LITERATURE

1. **Ito, Y., Nakano, M., Kyu, N. et al.:** Frosted branch angiitis in a child. *Jpn. J Clin Ophthalmol*, 30; 1976: 797–803.
2. **Říhová, E., Šišková, A., Kovařík, Z. et al.:** Syndrom omrzlych větví retinálních cév. *Čes. a Slov. Oftal*, 2; 2004: 98–103.
3. **Kleiner, R. C.:** Frosted branch angiitis: clinical syndrome or clinical sign? *Retina*, 17; 1997: 370–371.
4. **Říhová, E.:** Uvea. In Kuchynka, P. et al. (Ed), *Oční lékařství*, Praha, Grada, 2007: 427–477.
5. **Walker, S. et al.:** Frosted branch angiitis: a review. *Eye*, 18; 2004: 527–533.
6. **Kadoya, K., Obara, J., Chikuda, M. et al.:** A case of frosted – branch angiitis in an adult. *Nihon Ganka Kiyō (Folia Ophthalmol Jpn)*, 4; 1987: 273–278.
7. **Isoe, J., Yamamoto, T.:** Two juvenile case of frosted-branch angiitis of the retina. *Ganka Rinsho Ito (Jpn Rew Clin Ophthalmol)*, 84; 1990: 1507–1511.
8. **Hikichi, T., Yoshida, A., Nara, Y. et al.:** A case of frosted retinal periphlebitis in a 21/2-year-old girl. *Nihon Ganka Kiyō (Folia Ophthalmol Jpn)*, 40; 1989: 1752–1755.
9. **Browning D. J.:** Mild frosted branch periphlebitis. *Am J Ophthalmol*, 114; 1992: 505–506.
10. **Ohta, A., Oguro, Y., Satoh, K. et al.:** Unilateral frosted branch retinal angiitis. *Am J Ophthalmol*, 112; 1991: 477–478.
11. **Watanabe, Y., Taked, N., Adachi – Usami, E.:** A case of frosted branch angiitis. *Br Y Ophthalmol*, 71; 1987: 553–558.
12. **Atmaca, LS., Gunduz, K.:** Acute frosted retinal periphlebitis. *Acta Ophthalmol*, 71; 1993: 856–859.
13. **Yoshida, S., Kadoga, K., Osada, M. et al.:** Longterm followup in a case of frosted retina vasculitis. *Ganka Rinsho Iho (Jpn Rev Clin Ophthalmol)*, 84; 1990: 296–302.
14. **Narita, K., Sato, A.:** Systemic acyclovir was effective in a case of recurrent retinal angiitis. *Rinsho Ganka (Jpn J Clin Ophthalmol)*, 44; 1990: 739–743.
15. **Vander, J. F., Masciulli, L.:** Unilateral frosted branch angiitis. *Am J Ophthalmol*, 112; 1991: 477–478.
16. **Ridley, M. E., McDonald, H.R., Sternberg, P.jr. et al.:** Retinal manifestation of ocular lymphoma (reticulum cell sarcoma). *Ophthalmology*, 99; 1992: 1153–1161.
17. **Kim, T.S., Duker, J.S., Hedges, T.R.:** Retinal angiopathy resembling unilateral frosted branch angiitis in a patient with relapsing acute lymphoblastic leukemia. *Am J Ophthalmol*, 117; 1994: 806–807.
18. **Quillen, D. A., Stathopoulos, N. S., Blankenship, G. W. et al.:** Lupus associated frosted branch periphlebitis and exudative maculopathy. *Retina*, 17; 1997: 449–454.
19. **Jokhura, K., Hara, A., Hattori, O. et al.:** Frosted branch angiitis associated with aseptic meningitis. *Eur J Neurol*, 47; 2000: 241.
20. **Markomichelakis, N. N., Barampouti, F., Zafirakis, P. et al.:** Retinal vasculitis with frosted branch angiitis – like response due herpes simplex virus type 2. *Retina*, 19; 1999: 455–457.