

RETINAL CHANGES IN PATIENTS WITH COVID-19 AND DIFFERENT EXPRESSIVENESS OF METABOLIC CHANGES

Hutsaliuk Kateryna^{1,2}, Skalska Nataliia³, Ulianova Nadiia^{2,4}

¹The Regional Ophthalmology Center, ME "Volyn Regional Clinical Hospital" of the Volyn Regional Council, Lutsk, Ukraine

²The Filatov Institute of Eye Diseases and Tissue Therapy of the National Academy of Medical Sciences of Ukraine, Odesa, Ukraine

³Infectious Department, ME "Volyn Regional Clinical Hospital" of the Volyn Regional Council, Lutsk, Ukraine

⁴Department of Post-traumatic eye pathology, SI "The Filatov Institute of Eye Diseases and Tissue Therapy of the National Academy of Medical Sciences of Ukraine", Odesa, Ukraine

The authors of the study declare that no conflict of interest exists in the compilation, theme and subsequent publication of this professional communication, and that it is not supported by any pharmaceutical company.

The results of our work were presented at the "Euretina 2022", Hamburg, Germany, September 1–4, 2022.

Submitted to the Editorial Board: November 27, 2023

Accepted for publication: January 31, 2024

Available on-line: February 28, 2024



Dr. Hutsaliuk Kateryna
Pryvokzalna st. 10a/61
Lutsk
Volyn region
E-mail: galej_kamy@tdmu.edu.ua

SUMMARY

Aims: To study the relationship between the severity of COVID-induced metabolic changes and the structure and frequency of retinal changes, according to funduscopy data in patients with different clinical courses of COVID-19.

Materials and methods: 117 patients with COVID-19 were examined. While examining patients, severity of the course of COVID-19, the expressiveness of changes in the metabolic status were determined; fundus image registration was performed with portable fundus cameras Pictor Plus Fundus Camera and VistaView (Volk Optical).

Results: As a result of the research, retinal changes were found in 49 (41.9%) patients with COVID-19. In 8 (16.3%) cases, clinically significant (vitreous hemorrhage, prethrombosis of the central retinal vein or branches of the central retinal vein, thrombosis of the central retinal vein or branches of the central retinal vein) COVID-induced retinal and ophthalmological changes were observed, which caused a decrease in visual acuity. In 41 (83.7%) cases, clinically insignificant changes (cotton wool spots, narrowed retinal vessels, intraretinal and petechial hemorrhages, tortuosity and dilatation of retinal venules) COVID-induced retinal changes were observed. Clinically significant retinal changes occur in patients with a statistically significantly higher level of D-dimer and a greater percentage of lung parenchyma lesion than in the group of patients with clinically insignificant retinal changes ($p < 0.05$).

Conclusions: The structure of retinal changes in patients with COVID-19 correlates with the severity of the clinical course of the disease and changes in the metabolic status of patients. Metabolic changes are correlated with retinal changes and can be predictive for preventing general vascular complications in COVID-19.

Key words: retina, ophthalmoscopy, retinal vessels, COVID-19, metabolism

Čes. a slov. Oftal., 80, 2024, No. x, p.

INTRODUCTION

The course of COVID-19 is also accompanied by ophthalmological manifestations. Among retinal changes, the most frequently diagnosed are cotton wool spots [1–9], intraretinal and petechial hemorrhages along the course of retinal vessels [1,3–9], tortuosity and dilatation

of retinal venules [1,2,6], central retinal vein thrombosis [2,9,10], central retinal artery occlusion [3,10,11], acute macular neuroretinopathy [2,9,10], COVID-19-induced maculopathy [2]. However, there are studies in which no retinal changes were detected during COVID-19 [12].

In turn, in a limited number of works, clinical parallels are made between metabolic changes in patients'

organisms and the presence and/or expressiveness of retinal changes. A number of authors [13,14] note that ophthalmic manifestations of COVID-19 occur with elevated levels of fibrinogen, C-reactive protein, ferritin, and D-dimer [15], laboratory-diagnosed anemia in patients with severe COVID-19 [16], increased levels of C-reactive protein, number of platelets, ferritin and aspartate transaminase [17], increased levels of ferritin, D-dimer, procalcitonin, interleukin-6, C-reactive protein, fibrinogen [13,18], increased levels of fibrinogen, D-dimer, prothrombin time [13,19–22]. On the other hand, there are data on COVID-19-associated ophthalmological manifestations [20,23–25] which were not accompanied by any metabolic changes.

The limited and inconsistent data on the correlational relationship between retinal changes and metabolic changes do not allow a full understanding of the mechanisms of retinal changes in COVID-19, making it difficult to determine their relationship with the different clinical courses of this infectious disease, and complicating the choice of tactics for the correction of retinal changes in COVID-19. Such data would make it possible to diagnose the degree of severity of the main infectious disease, as well as to timely correct ophthalmological manifestations or make corrections in the treatment of diseases that require long-term therapy and were diagnosed before the disease of COVID-19 [26–29].

The purpose of our work is to study the relationship between the severity of COVID-induced metabolic chan-

ges and the structure and frequency of retinal changes, according to funduscopy data in patients with different clinical courses of COVID-19.

MATERIALS AND METHODS

The research was conducted on the basis of the Infectious Disease Department and the Regional Ophthalmology Center of the ME "Volyn Regional Clinical Hospital of the Volyn Regional Council" from October 2020 to December 2021. The study is prospective, uncontrolled and cross-sectional. 117 patients (234 eyes) aged 42 to 82 years (positive PCR test for COVID-19) were under observation. All clinical observations were carried out with the informed consent of the patients – Ethics Committee Protocol № 4 of November 13, 2023.

All patients were divided into two groups: 1) without retinal changes in COVID-19 (68 patients, 136 eyes); 2) with the presence of retinal changes (49 patients, 98 eyes) (subgroup 1 (8 patients, 16 eyes) – significant retinal changes, subgroup 2 (41 patients, 82 eyes) – insignificant) (Table 1).

According to the severity of the clinical course of COVID-19, patients corresponded to four groups (Table 1) in accordance with the recommendations of the Ministry of Health of Ukraine [30,31]. **Group 1** (34 patients) included patients with an extremely severe course of COVID-19, with signs of severe pneumonia, acute

Table 1. Clinical characteristics of groups of patients

Clinical characteristics of groups of patients					
Indicator		Without retinal changes (n=68)	With clinically significant retinal changes (n=8)	With clinically insignificant retinal changes (n=41)	The level of significance of the difference, p
Age (years)		61.1 ±10.2	69.9 ±11.9	61.8 ±9.1	0.067
Female (n, %)		43 (63.2)	4 (50)	19 (46.3)	0.211
Male (n, %)		25 (36.8)	4 (50)	22 (53.7)	
Lung parenchyma damage (%)		41 (35–54.5) ³	68 (55.5–72)	51 (24.8–68) ¹	0.039
Blood saturation level (%)		94 (89.5–96)	90.5 (82–97.5)	94 (86–94)	0.385
Oxygen flow rate (l/min) to maintain blood saturation at a normal level		10 (6–15)	12.5 (7–16)	10 (0–16)	0.830
Systolic blood pressure (mmHg)		21 (30.9)	1 (12.5)	14 (34.1)	0.479
Diastolic blood pressure (mmHg)		6 (8.8)	2 (25.0)	7 (17.1)	0.260
Clinical course, group (n, %)	1	10 (14.7) ^{2,3}	6 (75.0) ¹	18 (43.9) ¹	< 0.001
	2	16 (23.5)	1 (12.5)	9 (22.0)	
	3	26 (38.2)	1 (12.5)	3 (7.3)	
	4	16 (23.5)	–	11 (26.8)	

Note: at an oxygen flow rate to maintain blood saturation at a normal level of 0–5 l/min, oxygen was supplied through nasal cannulas, 5–10 l/min – through a mask without a respiratory bag, 10–20 l/min – through a mask with a respiratory bag, more than 20 l/min – both invasive and non-invasive ventilation.

Mean ±SD or median and interquartile range (QI – QIII) are given. Analysis of variance or non-parametric Kruskal-Wallis test was used to compare groups, and post hoc comparison was performed using Dunn's test. For qualitative characteristics, the chi-square test was used, the posterior comparison was carried out taking into account the Bonferroni correction:

1 – the difference from the retinal changes group is not statistically significant, $p < 0.05$;

2 – the difference from the significant retinal changes group is statistically significant, $p < 0.05$;

3 – the difference from the Insignificant retinal changes group is statistically significant, $p < 0.05$

respiratory distress syndrome, treatment with artificial lung ventilation. **Group 2** (26 patients) included patients with a severe course of COVID-19, with signs of severe pneumonia, plus one of the following: respiratory rate > 30 breaths/min; severe respiratory distress; or SpO₂ < 90%, no artificial ventilation was used.

Group 3 (30 patients) – patients with moderate severity of COVID-19, without signs of severe pneumonia, SpO₂ ≥ 90%, with decompensated concomitant pathology.

Group 4 (27 patients) included patients with moderate severity of COVID-19 without signs of severe pneumonia, SpO₂ ≥ 90%, with concomitant pathology in a state of compensation. Vital signs and blood oxygen saturation levels were monitored in patients from the moment of admission to the hospital until the moment of their discharge or death.

In patients with COVID-19, concomitant pathology was detected: hypertension (HD) of various degrees – 36 (9.8%), diabetes mellitus (DM) type 1 or 2 – 15 (4.1%).

Laboratory studies were performed at the laboratory of the Volyn Regional Clinical Hospital at the time of hospitalization of the patients.

Fundus image registration was carried out with portable fundus cameras Pictor Plus Fundus Camera, Volk Optical and VistaView, Volk Optical. The following retinal changes were diagnosed: cotton wool spots, narrowed retinal vessels, vitreous hemorrhage, intraretinal and petechial hemorrhages, prethrombosis of the central retinal vein or branches of the central retinal vein, thrombosis of the central retinal vein or branches of the central retinal vein, tortuosity and dilatation of the retinal venules. Clinically significant retinal and ophthalmological changes included changes accompanied by a decrease in visual acuity: vitreous hemorrhage, prethrombosis of the central retinal vein or branch of the central retinal vein, thrombosis of the central retinal vein or branch of the central retinal vein. Clinically insignificant (asymptomatic) changes included changes that were not accompanied by a decrease in visual acuity: cotton wool spots, narrowed retinal vessels, intraretinal and petechial hemorrhages, tortuosity and dilatation of retinal venules.

While examining patients, the content of leukocytes, lymphocytes, erythrocytes, and platelets in the blood, fasting glucose level, hemoglobin level, C-reactive pro-

tein level, International Normalized Ratio (INR), procalcitonin level, D-dimer level were determined. Diastolic and systolic blood pressure, blood saturation level, lung parenchyma lesion area were also determined.

After conducting all the laboratory and instrumental studies, the relationship between the expressiveness of metabolic changes, the severity of the course of COVID-19 and the presence and structure of retinal and ophthalmological changes in patients were evaluated.

When conducting the analysis for quantitative indicators, their distribution was checked for normality (Shapiro-Wilk test). In the case of a normal distribution, the mean (X) and standard deviation (±SD) were calculated, and for a non-normal distribution, the median (Me) and interquartile range (QI – QIII) were calculated. For qualitative indicators, the frequency (%) and, if necessary, the 95% probability interval (95% CI) were calculated. The Mann-Whitney test was used to compare the mean values in the two groups for quantitative indicators. To compare mean values in more than two groups for quantitative indicators in the case of a normal distribution law, the criterion of variance analysis was used, and in the case of a non-normal distribution law, the Kruskal-Wallis test was used. The chi-square test was used to compare qualitative indicators, and the Bonferroni correction was used when comparing more than two groups.

Methods of constructing and analyzing logistic regression models were used to quantitatively assess the relationship between factor characteristics and the risk of clinically significant retinal changes. The influence of factor characteristics was assessed by the value of the odds ratio (OR), for which 95% CI was calculated. Adequacy of the models was assessed by the area under the ROC curve of the model and its 95% CI.

Calculations were performed for a two-sided critical region, the critical level of significance was taken equal to 0.05.

RESULTS

As a result of the conducted studies, in 8 (17.0%) cases, clinically significant COVID-induced retinal and ophthalmological changes, which caused a decrease in visual

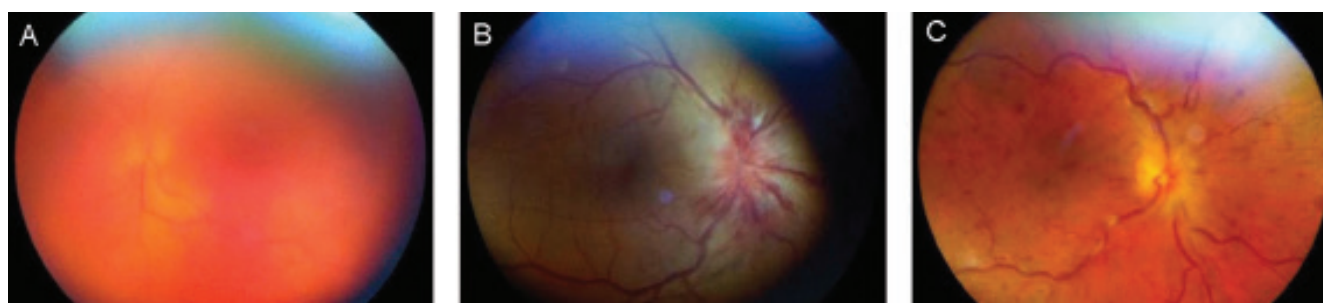


Figure 1. (A) Vitreous hemorrhage, (B) Prethrombosis of the central retinal vein or branch of the central retinal vein, (C) Thrombosis of the central retinal vein or branch of the central retinal vein

acuity, were observed. Funduscopy revealed: vitreous hemorrhage (Figure 1A), prethrombosis of the central retinal vein or branch of the central retinal vein (Figure 1B), thrombosis of the central retinal vein or branch of the central retinal vein (Figure 1C).

Clinically insignificant changes were detected in 39 cases (83.0%), namely: cotton wool spots (Figure 2A), narrowed retinal vessels (Figure 2B), intraretinal and pe-

teelial hemorrhages (Figure 2C), tortuosity and dilatation of retinal venules (Figure 2D).

Further, the peculiarities of metabolic changes in patients with the presence and absence of retinal changes, and in the presence of significant and insignificant retinal changes were investigated. It was found that in patients with retinal changes, the content of lymphocytes was statistically significantly lower by 30.8%, the level of

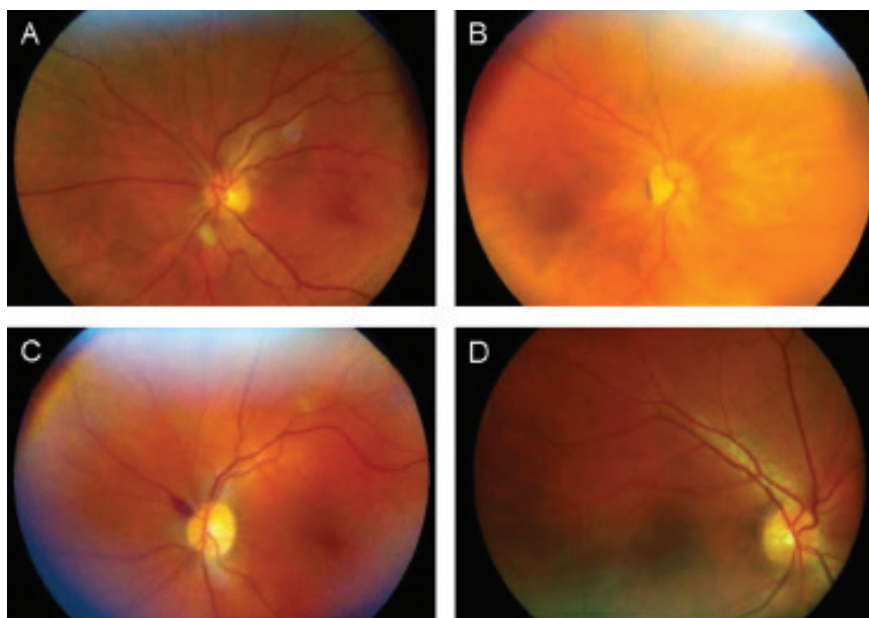


Figure 2. (A) Cotton wool spots, (B) Narrowed retinal vessels, (C) Intraretinal and petechial hemorrhages, (D) Tortuosity and dilatation of retinal venules

Table 2. Distribution of the presence of retinal changes in patients with COVID-19, depending on metabolic changes

Indicator	Without retinal changes	With retinal changes	The level of significance of the difference between groups, p
	(n=68)	(n=49)	
Age, years	62 (53.5–69)	63 (58.75–69.25)	0.416
Leukocytes level, amount *10 ⁹ /l	6.85 (5.1–12.5)	7.2 (5.675–10.95)	0.611
Lymphocytes level, %	1.3 (0.9–1.6)	0.9 (0.6–1.3)	0.003
Erythrocyte level, amount *10 ¹² /l	4.615 (4.4–4.895)	4.6 (4.2–5.16)	0.726
Hemoglobin level, g/l	135.5 (127.5–147.5)	142 (128.75–150.5)	0.182
Platelet level, amount *10 ¹² /l	2 (146–243.5)	198 (148.25–251)	0.643
C-reactive protein level, mg/ml	33.845 (15.44–89.5)	57.16 (16.22–109.74)	0.586
INR, Un	1.14 (1.07–1.3)	1.2 (1–1.35)	0.98
Procalcitonin level, ng/ml	0.225 (0.09–0.665)	0.17 (0.0275–0.605)	0.225
D-dimer level, µg/ml	0.5 (0.285–1.115)	0.87 (0.298–2.175)	0.145
Fasting blood glucose level, mmol/ml	8.04 (6.335–9.725)	6.62 (5.373–10.095)	0.047
Damage to the lung parenchyma, %	41 (36–54.5)	62 (42.25–68.75)	0.004
Blood saturation level, %	94 (89.5–96)	94 (86–94.25)	0.167
Systolic blood pressure, mmHg	130 (127.5–140)	130 (123.75–140)	0.729
Diastolic blood pressure, mmHg	80 (80–90)	80 (80–90)	0.457

Notes: comparisons were made using the Mann-Whitney test

glucose in the blood was lower by 17.6%, and the area of lesions of the lung parenchyma was larger by 51.2% according to computer tomography data. Differences in other studied indicators, including D-dimer, were not statistically significant (Table 2, Graphs 1–3).

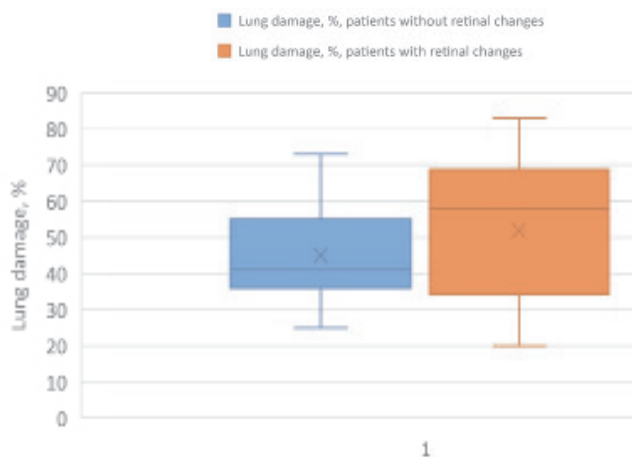
Regarding clinically significant and clinically insignificant retinal changes: clinically significant retinal changes occur in patients with a statistically significantly higher level of D-dimer and a greater percentage of lung parenchymal lesions, than in the group of patients with clinically insignificant retinal changes (Table 3, Graphs 4–5).

It should be noted that the observation groups of patients without retinal changes, with significant and insignificant retinal changes did not statistically significantly differ from each other in the presence of concomitant pathology, namely hypertension (0.479), diabetes mellitus

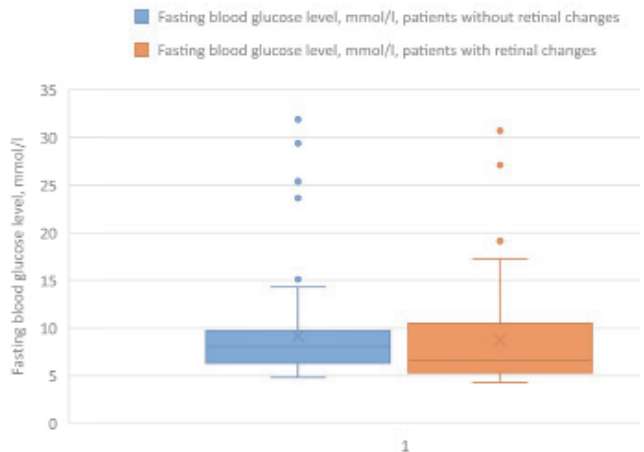
type 1 and 2 (0.260). It was also established that patients with an extremely severe course of COVID-19 (Group 1) had more significant and non-significant retinal changes compared to other groups; the statement is statistically reliable ($p < 0.001$). Groups 2–4 of the clinical course of COVID-19 (Table 1) did not differ in the presence of retinal changes ($p > 0.5$).

To predict the course of COVID-19 and the occurrence of possible complications, an analysis of the relationship of the risk of the occurrence of clinically significant retinal changes for each factor characteristic of metabolic changes in patients with COVID-19 was performed (Table 4). At the same time, the method of building univariate logistic regression models was used.

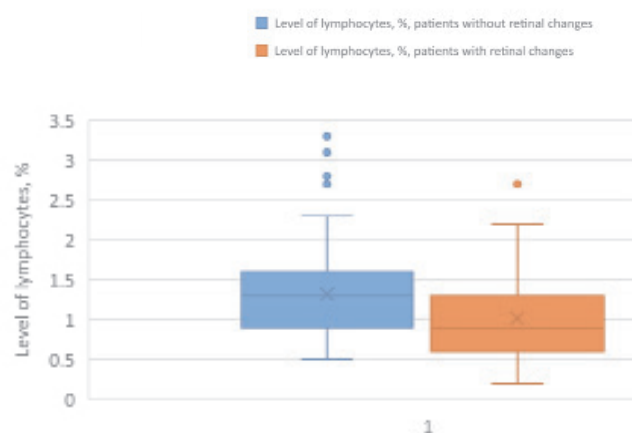
Univariate analysis revealed an increase ($p = 0.025$) in the risk of clinically significant retinal changes in patients with COVID-19 with patient age, OR = 1.10 (95 % CI 1.01–1.20)



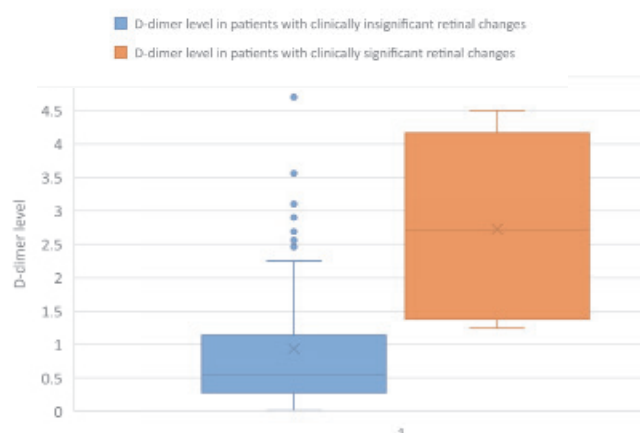
Graph 1. The percentage of lung parenchyma damage in the group of patients without retinal changes and with retinal changes. Median value, first and third quartile values, minimum and maximum values are indicated



Graph 2. Fasting blood glucose level in patients in the group of patients without retinal changes and with retinal changes. Median value, first and third quartile values, minimum and maximum values are indicated



Graph 3. The level of lymphocytes in the blood of patients in the group of patients without retinal changes and in the presence of retinal changes. Median value, first and third quartile values, minimum and maximum values are indicated



Graph 4. D-dimer level in the group of patients without clinically significant retinal changes and in the presence of clinically significant retinal changes. Median value, first and third quartile values, minimum and maximum values are indicated

Table 3. Distribution of presence of clinically significant and clinically insignificant retinal changes in patients with COVID-19, depending on metabolic changes

Indicator	There are clinically insignificant retinal changes (n=109)	There are clinically significant retinal changes (n=8)	The level of significance of the difference, p
Age, years	63 (56–69)	66.5 (60.5–76)	0.124
Leukocytes level, amount *10 ⁹ /l	7 (5.3–12.225)	8.95 (5.6–10.65)	0.654
Lymphocytes level, %	1.1 (0.775–1.4)	1.4 (0.8–1.8)	0.338
Erythrocyte level, amount *10 ¹² /l	4.6 (4.235–4.943)	5.015 (4.425–5.345)	0.165
Hemoglobin level, g/l	137 (127.75–148)	146 (137–153.5)	0.193
Platelet level, amount *10 ¹² /l	203 (148.25–244.25)	170.5 (13.5–255)	0.397
C-reactive protein level, mg/ml	33.42 (15.99–93.72)	81.01 (20.01–143.985)	0.288
INR, Un	1.14 (1.07–1.3)	1.2 (1.035–1.595)	0.52
Procalcitonin level, ng/ml	0.22 (0.07–0.688)	0.085 (0.07–0.385)	0.356
D-dimer level, µg/ml	0.54 (0.28–1.14)	2.705 (1.495–3.83)	<0.001
Fasting blood glucose level, mmol/ml	7.18 (6.8–9.715)	7.27 (6.53–9.43)	0.854
Damage to the lung parenchyma, %	45 (36–62)	68 (55.5–72)	0.004
Blood saturation level, %	94 (88–96)	90.5 (82–97.5)	0.661
Systolic blood pressure, mmHg	130 (125–140)	130 (130–14)	0.322
Diastolic blood pressure, mmHg	80 (80–90)	80 (80–90)	0.883

Notes: comparisons were made using the Mann-Whitney test

Table 4. Distribution of coefficients of univariate logistic regression models for predicting the risk of clinically significant retinal changes

Factor sign		The value of the coefficient of the model, b ± m	The level of significance of the difference of the model coefficient from 0.5 p	Odds ratio indicator, OR (95 CI)
Sex	F	Reference		
	M	0.28 ± 0.73	0.706	–
Leukocytes level, amount *10 ⁹ /l		0.096 ± 0.043	0.025	1.10 (1.01–1.20)
Lymphocytes level, %		0.037 ± 0.067	0.583	–
Erythrocyte level, amount *10 ¹² /l		0.42 ± 0.55	0.446	–
Hemoglobin level, g/l		0.40 ± 0.44	0.360	–
Platelet level, amount *10 ¹² /l		0.025 ± 0.021	0.224	–
C-reactive protein level, mg/ml		–0.003 ± 0.004	0.440	–
INR, Un		0.003 ± 0.004	0.506	–
Procalcitonin level, ng/ml		0.45 ± 0.62	0.464	–
D-dimer level, µg/ml		–0.76 ± 0.91	0.406	–
Fasting blood glucose level, mmol/ml		1.12 ± 0.32	< 0.001	3.1 (1.7–5.8)
Damage to the lung parenchyma, %		–0.018 ± 0.077	0.816	–
Blood saturation level, %		0.084 ± 0.032	0.010	1.09 (1.02–1.16)
Systolic blood pressure, mmHg		–0.034 ± 0.042	0.416	–
Diastolic blood pressure, mmHg		0.010 ± 0.023	0.669	–
Leukocytes level, amount *10 ⁹ /l		0.008 ± 0.042	0.838	–
HD	No	Reference		
	Yes	–1.20 ± 1.09	0.271	–
DM 1 or 2 type	No	Reference		
	Yes	0.90 ± 0.87	0.300	–

HD – hypertension

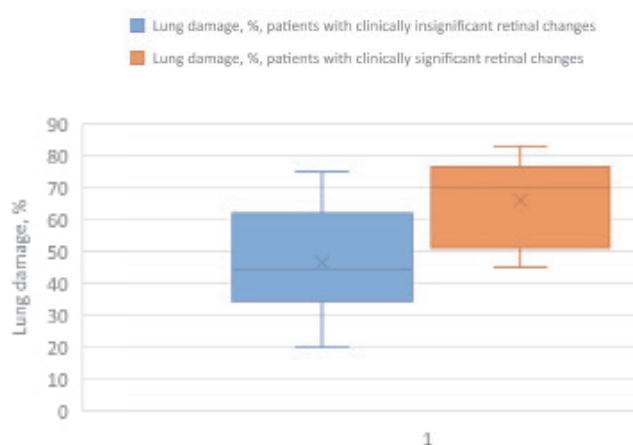
DM – diabetes mellitus

for each year. All patients with clinically significant retinal changes were older than 60 years.

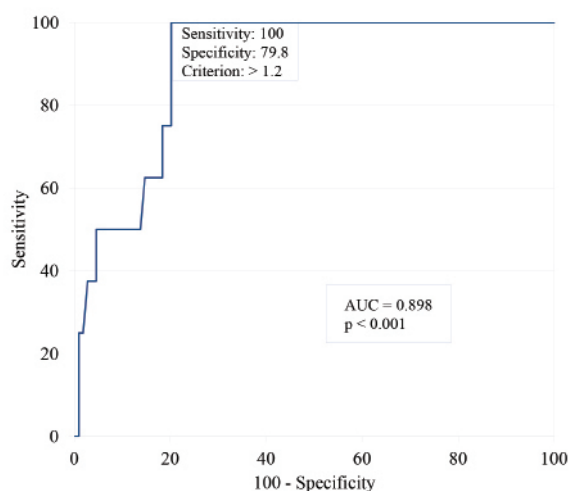
An increase ($p < 0.001$) in the risk of clinically significant retinal changes with an increase in D-dimer level was also found, OR = 3.1 (9 % CI 1.7–5.8) per unit of measurement (mcg/ml). Graph 6 shows the operating characteristics curve of this model.

AUC1 model operating characteristics curve = 0.90 (95 % CI 0.83–0.95), indicating a strong association of risk of clinically significant retinal changes in patients with COVID-19 with D-dimer levels. When choosing the optimal (according to the Youden Index) critical level of $Y_{crit} > 1.2$ measurement units ($\mu\text{g/ml}$), the sensitivity of the model is 100 % (95 % CI 63.1 %–100 %), the specificity is 79.8 % (95 % CI 71.1 %–86.9 %). All patients with clinically significant retinal changes had a D-dimer level $> 1.2 \mu\text{g/ml}$.

In addition, there was also an increase ($p = 0.010$) in the risk of clinically significant retinal changes with



Graph 5. The area of lung parenchyma damage in the group of patients without clinically significant retinal changes and in the presence of clinically significant retinal changes. Median value, first and third quartile values, minimum and maximum values are indicated



Graph 6. ROC curve for predicting the risk of clinically significant retinal changes by D-dimer level

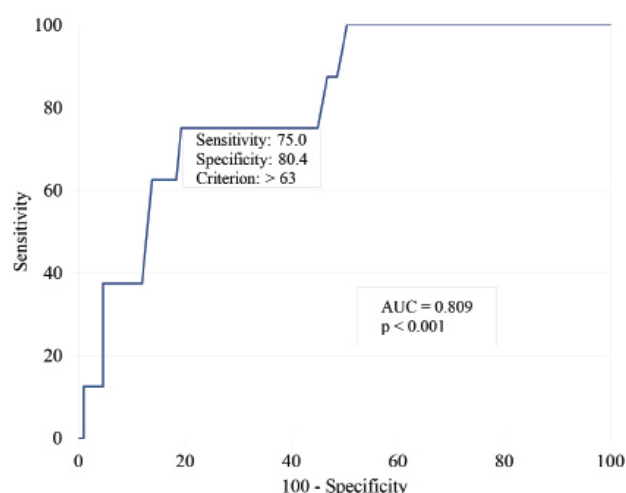
an increase in the degree of lung parenchymal damage in patients with COVID-19, OR = 1.09 (95 % CI 1.02–1.16) for each the percentage of growth of the lung parenchyma lesion area. Graph 7 shows the operational characteristics curve of this model.

The area under the curve of the operational characteristics of the model AUC2 = 0.81 (95 % CI 0.73–0.88), which indicates a strong relationship between the risk of clinically significant retinal changes and the degree of lung parenchymal damage. When choosing the optimal (according to the Youden Index) critical level of $Y_{crit} > 63$ %, the sensitivity of the model is 75 % (95 % CI 34.9 %–96.8 %), the specificity is 80.4 % (95 % CI 71.6 %–87.4 %). All patients with clinically significant retinal changes had lung parenchymal lesion area > 63 %.

DISCUSSION

So, today, the pathogenesis of COVID-19 in general has the characteristic features of an acute respiratory infection, with the involvement of all organs and systems of the human body in the process of moderately severe, severe and extremely severe course. As a result, the inflammatory process acquires a systemic character, which is included in the concept of “systemic inflammatory response syndrome”. As a result, we can single out a list of metabolic changes specific to this disease: a shift towards hypercoagulation due to increased levels of D-dimer, fibrinogen, C-reactive protein, procalcitonin, ferritin, erythrocyte sedimentation rate (ESR), the number of platelets and have a prognostically reliable connection with increased the risk of thrombotic complications in COVID-19 [26,27,32].

The most interesting, in context of thromboembolic complications, is the level of D-dimer. The pathophysiological chain of D-dimer formation is as follows: the fibrinolytic system splits the fibrin mesh after the formation of a thrombus; D-dimer, which consists of two D-fragments



Graph 7. ROC curve for predicting the risk of clinically significant retinal changes by the degree of lung parenchymal damage in patients with COVID-19

of fibrin, is formed as a result of activation of the plasmin enzyme. This indicates the presence of destroyed fibrin in the blood, that is, D-dimer reflects the activation of the coagulation and fibrinolysis systems [33].

Considering D-dimer as a marker of thromboembolic complications in COVID-19, we have the following data: excessive inflammation (cytokine storm, activation of vascular endothelium and macrophages), diffuse intravascular coagulation, immobilization, hypoxia due to excessive lung damage in COVID-19 can lead to massive thromboembolic complications [33]. Published data, concerning coagulopathy in COVID-19, showed an increase in the level of D-dimer, lactate dehydrogenase, slight or no changes in prothrombin and thromboplastin time, as well as an increase in the level of antiphospholipid antibodies [34–37].

Analyzing the general connection of D-dimer level with ophthalmic pathology in general, we can note the following correlations: the level of D-dimer is statistically significantly higher in patients with proliferative diabetic retinopathy than in patients with non-proliferative diabetic retinopathy [38,39]. Also, a statistically higher level of D-dimer was found in patients with leukemic retinopathy compared to the control group [40].

Taking into account all the above facts, we can conclude that today this infectious disease is one of the most common triggers of vascular symptomatic or asymptomatic changes in all organs and systems of the human body. The organ of vision is not an exception and is included in the cohort of extrapulmonary manifestations of COVID-19.

In order to investigate the occurrence of retinal changes in COVID-19, we delved into the details of how the COVID-19 virus enters the cells of the retina and have the following information: through interaction with Angiotensin-converting enzyme (ACE) receptors, the COVID-19 virus enters the cells of the human body [41], and retinal cells, in particular, due to simultaneous interaction with ACE and cluster of differentiation (CD) 147/basigin receptors [42]. Also, there are data on the presence of cellular receptors in the retina (Müller cells, ganglion cells, pigment epithelium, retinal microvessels) for various parts of the renin-angiotensin system (ACE, ACE2, prorenin and angiotensinogen receptors) [42]. In particular, there are also data on the presence of ACE/ACE2 receptors in organelles of pigment epithelium cells and ganglion cells of the retina (in laboratory, culture of human retinal organoids was obtained from induced pluripotent stem cells) which, under *in vitro* conditions, were susceptible to infection with the COVID-19 pseudovirus [43]. There is an interesting fact that the expression of ACE/ACE2 increases from the cornea to the retina, and, at the moment, it is beginning to be considered as another way of spreading the virus into the deep structures of the retina, optic nerve, and optic pathway [44]. Recent data show that both ACE-2 and Transmembrane protease, serine 2 (TMPRSS2) are highly expressed in the human retina. A recent case series of 3 patients detected the S and N proteins of COVID-19 by immunofluorescence micros-

copy in retinal vascular endothelial cells, presumably containing viral particles [45]. Perhaps this tropism of the virus to retinal cells explains the presence of retinal changes in patients with COVID-19.

The analysis of existing data indicates the existence of contradictions in the views on the correlation between the COVID-19 induced metabolic changes and the presence and/or expressiveness of retinal changes. Thus, Sen S, et al. and Ung L et al. note that intraretinal and petechial hemorrhages and cotton wool spots occur with elevated levels of fibrinogen, C-reactive protein, ferritin, and D-dimer [15]. There are also data on the detection of flame-shaped intraretinal and dot and blot microhemorrhages (in combination with an elevated level of D-dimer), nerve fiber layer infarcts and microhemorrhages in the papillomacular bundle in patients with COVID-19 [46].

It was also established that cotton wool spots occur at a D-dimer level higher than 385 mg/dL–1 in 22 % of the examined patients, and these results were put forward as a hypothesis that COVID-19 is a systemic vascular disease [13,47].

A case of bilateral thrombosis of the central retinal vein with elevated levels of D-dimer and C-reactive protein secondary to COVID-19 was also described [48]. Venkatesh R, Reddy NG, Agrawal S, Pereira A. describe a case of COVID-19-associated central retinal vein thrombosis with elevated D-dimer and ESR [49]. Also, there is an interesting case of suspected bilateral central retinal vein thrombosis in a patient with COVID-19; the patient had dilated retinal veins, epiretinal hemorrhages (in particular, one in the macular area) and elevated levels of D-dimer and C-reactive protein [50], which once again proves the importance of ophthalmological examinations of patients with COVID-19, in order to timely suspect and prevent the occurrence of vascular complications. Certain authors [13,19,21,22], during the laboratory examination of patients with thrombosis of the central vein of the retina during COVID-19, revealed pronounced rheological changes due to significantly increased levels of fibrinogen, D-dimer, prothrombin time.

It should be noted that both veins and arteries can experience thromboembolic complications in COVID-19 [33], which is illustrated by the following case of central retinal artery embolism in a patient with COVID-19 with elevated levels of D-dimer, C-reactive protein, and fibrinogen [51]. A group of authors describe cases of central retinal artery embolism in the above-mentioned infectious disease, while laboratory tests showed elevated levels of ferritin, D-dimer, procalcitonin, interleukin-6, C-reactive protein, and fibrinogen [13,18].

Also noteworthy is the case of paracentral acute maculopathy associated with COVID-19 and elevated D-dimer levels [52].

In our study, we focused our attention on the correlation of retinal changes with metabolic changes in COVID-19. We described for the first time the dependence of retinal changes, both in general, and divided into clinically significant and clinically insignificant, on various parameters

of metabolic changes in the aforementioned infectious disease. During our study, we obtained the following data: retinal changes were noted in patients with statistically significantly lower levels of lymphocytes and blood glucose levels, as well as a higher percentage of lung parenchymal lesions than in those in whom these changes were not found. Regarding clinically significant and clinically insignificant retinal changes: clinically significant retinal changes occurred in patients with statistically significantly higher D-dimer levels and a greater percentage of lung parenchymal involvement than in the group of patients with clinically insignificant retinal changes.

In our studies, univariate analysis revealed an increase in the risk of clinically significant retinal changes in patients with COVID-19 with the age of the patients, an increase in the level of D-dimer and the degree of damage to the lung parenchyma. These indicators are statistically significant: $p < 0.05$. As you know, vascular changes are the first to occur among the microcirculatory vessels, which are the vessels of the retina. So, taking this into account, it is possible to predict the presence of not only retinal vascular changes in certain metabolic shifts, but also their systemic nature in COVID-19.

In contrast, there are also reports of COVID-19-associated neuroretinopathy [24] and COVID-19-associated maculopathy [24,25], which were not accompanied by any changes in laboratory tests. Certain authors did not find any laboratory abnormalities during the laboratory examination of patients with thrombosis of the central retinal vein during COVID-19 [20,23].

With regard to the correlation of the presence and variety of retinal changes with the area of lung parenchyma damage, we did not find any data on such a relationship when we reviewed the literature. In turn, in our study,

we found a statistically significant relationship between the area of lung damage and retinal changes. As can be seen from Table 1: this correlation is significant and statistically reliable ($p = 0.039$). In our opinion, this can be explained by the fact that when the area of damage to the lung parenchyma increases, the concentration of pro-inflammatory agents in the blood increases, the rheological picture shifts towards hypercoagulation, and the microcirculatory vessels suffer first of all, because they have no collateral blood supply.

Summarizing our review of the literature and our previous studies, we can say that the correlation between the degree of severity of COVID-19, the metabolic status of patients and the presence and clinical significance of retinal changes is statistically significant and should be taken into account when treating the disease and predicting its course [53].

CONCLUSIONS

The structure of retinal changes in patients with COVID-19 correlates with the severity of the clinical course of the disease and changes in the metabolic status of patients. An increase in the lung parenchyma damage area and the level of D-dimer increase the risk of occurrence of significant retinal and ophthalmological changes, accompanied by a decrease in visual acuity (vitreal hemorrhage, prethrombosis or thrombosis of the central retinal vein or branches of the central retinal vein).

Acknowledgements to Vitaly Guryanov, Associate Professor, Health Management Department, O.O. Bogomolets National Medical University.

REFERENCES

1. Invernizzi A, Schiuma M, Parrulli S et al. Retinal vessels modifications in acute and post-COVID-19. *Sci Rep*. 2021 Sep 29;11(1):19373. doi: 10.1038/s41598-021-98873-1
2. Szczęśniak M, Brydak-Godowska J. SARS-CoV-2 and the Eyes: A Review of the Literature on Transmission, Detection, and Ocular Manifestations. *Med Sci Monit*. 2021 Sep 11;27:e931863. doi: 10.12659/MSM.931863
3. Feng Y, Armenti ST, Mian SI. COVID-19 and the Eye: A Comprehensive Review of the Literature. *Int Ophthalmol Clin*. 2021 Jan 1;61(1):1-14. doi: 10.1097/IIO.0000000000000339
4. Farvardin M, Johari M, Tahamtan M et al. Ophthalmic manifestations of COVID-19; a less-appreciated yet significant challenge. *Int Ophthalmol*. 2021 Mar;41(3):1141-1147. doi: 10.1007/s10792-020-01664-2
5. Marinho PM, Marcos AAA, Romano AC, Nascimento H, Belfort R Jr. Retinal findings in patients with COVID-19. *Lancet*. 2020 May 23;395(10237):1610. doi: 10.1016/S0140-6736(20)31014-X. Epub 2020 May 12
6. Mack HG, Fraser-Bell S. "COVID new normal" in ophthalmology: Implications for ophthalmologists, eye care, ophthalmic education and research. *Clin Exp Ophthalmol*. 2021 Jan;49(1):9-11. doi: 10.1111/ceo.13898
7. Lima LCF, Moraes Junior HV, Moraes HMV. COVID-19 Ocular Manifestations in the Early Phase of Disease. *Ocul Immunol Inflamm*. 2021 May 19;29(4):666-668. doi: 10.1080/09273948.2021.1887278
8. Ung L, Chodosh J. COVID-19 and the eye: alternative facts The 2022 Bowman Club, David L. Easty lecture. *BMJ Open Ophthalmol*. 2022 May;7(1):e001042. doi: 10.1136/bmjophth-2022-001042
9. Zhang Y, Stewart JM. Retinal and choroidal manifestations of COVID-19. *Curr Opin Ophthalmol*. 2021 Nov 1;32(6):536-540. doi: 10.1097/ICU.0000000000000801
10. Sen M, Honavar SG, Sharma N, Sachdev MS. COVID-19 and Eye: A Review of Ophthalmic Manifestations of COVID-19. *Indian J Ophthalmol*. 2021 Mar;69(3):488-509. doi: 10.4103/ijo.IJO_297_21
11. Özgür Y, Gamze UG, Funda C, Bahattin H, Selim D. Different Cases, Different Manifestations of Post-COVID-19 Retinal Artery Occlusion: A Case Series. *Turk J Ophthalmol*. 2023;53(2):124-129. doi: 10.4274/tjo.galenos.2022.36930
12. İbrahim EA, Demet A. Prospective Study: Frequency of Ophthalmic Findings, Relationship with Inflammation Markers, and Effect on Prognosis in Patients Treated in the COVID-19 Intensive Care Unit. *Turk J Ophthalmol*. 2022;52:6-13.
13. Sen S, Kannan NB, Kumar J et al. Retinal manifestations in patients with SARS-CoV-2 infection and pathogenetic implications: a systematic review. *Int Ophthalmol*. 2022 Jan;42(1):323-336. doi: 10.1007/s10792-021-01996-7
14. Ung L, Chodosh J. COVID-19 and the eye: alternative facts The 2022 Bowman Club, David L. Easty lecture. *BMJ Open Ophthalmol*. 2022 May;7(1):e001042. doi: 10.1136/bmjophth-2022-001042
15. Lani-Louzada R, Ramos CDVF, Cordeiro RM, Sadun AA. Retinal changes in COVID-19 hospitalized cases. *PLoS One*. 2020 Dec 3;15(12):e0243346. doi: 10.1371/journal.pone.0243346
16. D'Aloisio R, Nasillo V, Gironi M, Mastropasqua R. Bilateral macular hemorrhage in a patient with COVID-19. *Am J Ophthalmol Case*

- Rep. 2020 Dec;20:100958. doi: 10.1016/j.ajoc.2020.100958. Epub 2020 Oct 9
17. Gascon P, Briantais A, Bertrand E et al. Covid-19-Associated Retinopathy: A Case Report, Ocular Immunology and Inflammation, 2020;28(8):1293-1297. doi: 10.1080/09273948.2020.1825751
 18. Acharya S, Diamond M, Anwar S, Glaser A, Tyagi P. Unique case of central retinal artery occlusion secondary to COVID-19 disease. IDCases. 2020;21:e00867. Epub 2020 Jun 18. doi: 10.1016/j.idcr.2020.e00867
 19. Gaba WH, Ahmed D, Al Nuaimi RK, Dhanhani AA, Eatamadi H. Bilateral Central Retinal Vein Occlusion in a 40-Year-Old Man with Severe Coronavirus Disease 2019 (COVID-19) Pneumonia. Am J Case Rep. 2020 Oct 29;21:e927691. doi: 10.12659/AJCR.927691
 20. Walinjar JA, Makhija SC, Sharma HR, Morekar SR, Natarajan S. Central retinal vein occlusion with COVID-19 infection as the presumptive etiology. Indian J Ophthalmol. 2020 Nov;68(11):2572-2574. doi: 10.4103/ijo.IJO_2575_20
 21. Invernizzi A, Pellegrini M, Messenio D et al. Impending Central Retinal Vein Occlusion in a Patient with Coronavirus Disease 2019 (COVID-19). Ocular Immunology and Inflammation, 2020;28(8):1290-1292. doi: 10.1080/09273948.2020.1807023
 22. Insausti-García A, Reche-Sainz JA, Ruiz-Arranz C, López Vázquez A, Ferro-Osuna M. Papillophlebitis in a COVID-19 patient: Inflammation and hypercoagulable state. Eur J Ophthalmol. 2022 Jan;32(1):NP168-NP172. Epub 2020 Jul 30. doi: 10.1177/1120672120947591
 23. Sheth JU, Narayanan R, Goyal J, Goyal V. Retinal vein occlusion in COVID-19: A novel entity. Indian J Ophthalmol. 2020 Oct;68(10):2291-2293. doi: 10.4103/ijo.IJO_2380_20
 24. Virgo J, Mohamed M. Paracentral acute middle maculopathy and acute macular neuroretinopathy following SARS-CoV-2 infection. Eye (Lond). 2020 Dec;34(12):2352-2353. Epub 2020 Jul 3. doi: 10.1038/s41433-020-1069-8
 25. Filho LAZ, Lima LH, Melo GB, Zett C, Farah ME. Vitritis and Outer Retinal Abnormalities in a Patient with COVID-19. Ocular Immunology and Inflammation, 2020;28(8):1298-1300. doi: 10.1080/09273948.2020.1821898
 26. Valapala VNG, Dasari N, Kolli VK, Mandapaka M. Clinical and biochemical profile of COVID-19 patients admitted in a tertiary care hospital in Visakhapatnam, India during post unlock 2.0 - a retrospective study. J Med Life. 2022 Feb;15(2):264-268. doi: 10.25122/jml-2021-0341
 27. Ali HN, Ali KM, Rostam HM et al. Clinical laboratory parameters and comorbidities associated with severity of coronavirus disease 2019 (COVID-19) in Kurdistan Region of Iraq. Pract Lab Med. 2022 Aug;31:e00294. doi: 10.1016/j.plabm.2022.e00294
 28. Desideri LF, Tovani-Palone MR. COVID-19 and the increased risk of myopia and digital eye strain. Einstein (Sao Paulo). 2021 May 24;19:eCE6491. doi: 10.31744/einstein_journal/2021CE6491
 29. Sethi K, Levine ES, Roh S, Marx JL, Ramsey DJ. Modeling the impact of COVID-19 on Retina Clinic Performance. BMC Ophthalmol. 2021 May 10;21(1):206. doi: 10.1186/s12886-021-01955-x
 30. Order of the Ministry of Health of Ukraine of March 28, 2020 No. 722, Available from: <https://www.dec.gov.ua/mtd/koronavirus-na-hvoroba-2019-covid-19/>
 31. Clinical management of patients with COVID-19 "live" clinical guideline from 2021, Available from: <https://www.dec.gov.ua/mtd/koronavirusna-hvoroba-2019-covid-19/>
 32. Al-Samkari H, Karp Leaf RS, Dzik WH et al. COVID-19 and coagulation: bleeding and thrombotic manifestations of SARS-CoV-2 infection. Blood. 2020 Jul 23;136(4):489-500. doi: 10.1182/blood.202006520
 33. Rostami M, Mansouritorghabeh H. D-dimer level in COVID-19 infection: a systematic review. Expert Rev Hematol. 2020 Nov;13(11):1265-1275. doi: 10.1080/17474086.2020.1831383
 34. Zhan H, Chen H, Liu C et al. Diagnostic Value of D-Dimer in COVID-19: A Meta-Analysis and Meta-Regression. Clin Appl Thromb Hemost. 2021 Jan-Dec;27:10760296211010976. doi: 10.1177/10760296211010976
 35. Shi C, Wang C, Wang H, et al. The potential of low molecular weight heparin to mitigate cytokine storm in severe COVID-19 patients: a retrospective clinical study. medRxiv. 2020.2003.2028.20046144
 36. Zhang Y, Xiao M, Zhang S, et al. Coagulopathy and antiphospholipid antibodies in patients with Covid-19. N Engl J Med. 2020;382(17):e38.
 37. Connors JM, Levy JH. COVID-19 and its implications for thrombosis and anticoagulation. Blood. 2020 Jun 4;135(23):2033-2040. doi: 10.1182/blood.2020060000
 38. Zhao H, Zhang LD, Liu LF et al. Blood Levels of Glycated Hemoglobin, D-Dimer, and Fibrinogen in Diabetic Retinopathy. Diabetes Metab Syndr Obes. 2021 Jun 2;14:2483-2488. doi: 10.2147/DMSO.S309068
 39. Dan-Brezis I, Zahavi A, Axer-Siegel R et al. Inflammation, angiogenesis and coagulation interplay in a variety of retinal diseases. Acta Ophthalmol. 2020 Aug;98(5): e559-e562. doi: 10.1111/aos.14331
 40. Yang L, Chen Y, Zhang Y, Shen T, Shen X. Changes in retinal circulation and choroidal thickness in patients with acute myeloid leukemia detected by optical coherence tomography angiography. Front Med (Lausanne). 2023 Mar 13;10:1117204. doi: 10.3389/fmed.2023.1117204
 41. Zhou P, Yang XL, Wang XG et al. A pneumonia outbreak associated with a new coronavirus of probable bat origin. Nature. 2020 Mar;579(7798):270-273. doi: 10.1038/s41586-020-2012-7. Epub 2020 Feb 3. Erratum in: Nature. 2020 Dec;588(7836):E6
 42. Li YP, Ma Y, Wang N, Jin ZB. Eyes on coronavirus. Stem Cell Res. 2021 Mar;51:102200. Epub 2021 Jan 27. doi: 10.1016/j.scr.2021.102200
 43. Ahmad Mulyadi Lai H, Chou SJ, Chien Y et al. Expression of Endogenous Angiotensin-Converting Enzyme 2 in Human Induced Pluripotent Stem Cell-Derived Retinal Organoids. Int J MolSci. 2021 Jan 28;22(3):1320. doi: 10.3390/ijms22031320
 44. Hill JM, Clement C, Arceneaux L, Lukiw WJ. Angiotensin Converting Enzyme 2 (ACE2) Expression in the Aged Brain and Visual System. J AgingSci. 2021;Vol 9(Suppl 7):001. Epub 2021 Sep 30.
 45. Hu K, Patel J, Swiston C, Patel BC. Ophthalmic Manifestations of Coronavirus (COVID-19). 2022 May 24. In: StatPearls [Internet]. Treasure Island (FL): StatPearls Publishing; 2024 Jan. PMID: 32310553.
 46. Lani-Louzada R, Ramos CDVF, Cordeiro RM, Sadun AA. Retinal changes in COVID-19 hospitalized cases. PLoS One. 2020 Dec 3;15(12): e0243346. doi: 10.1371/journal.pone.0243346
 47. Landecho MF, Yuste JR, Gándara E et al. COVID-19 retinal microangiopathy as an in vivo biomarker of systemic vascular disease? (Rapid Communication). J Intern Med. 2021;289:116-120. doi: 10.1111/joim.13156
 48. Lin CH, Sun IT. Bilateral Simultaneous Central Retinal Vein Occlusion Secondary to COVID-19: A Case Report. Case Rep Ophthalmol. 2023 Feb 17;14(1):56-61. doi: 10.1159/000529298
 49. Venkatesh R, Reddy NG, Agrawal S, Pereira A. COVID-19-associated central retinal vein occlusion treated with oral aspirin. BMJ Case Rep. 2021 May 19;14(5): e242987. doi: 10.1136/bcr-2021-242987
 50. Saha R, Singh SK, Samanta S. Fundus Examination to Guide Anticoagulation Therapy in Suspected COVID-19 in a Critical Care Unit. Indian J Crit Care Med 2021;25(6):737-738.
 51. de Oliveira MR, Lucena ARV, Higino TM, Ventura CV. Central retinal artery occlusion with cilioretinal artery sparing secondary to COVID-19: Additional ocular complication. Indian J Ophthalmol. 2023 Feb;71(2):663-666. doi: 10.4103/ijo.IJO_1246_22
 52. Padhy SK, Dcruz RP, Kelgaonkar A. Paracentral acute middle maculopathy following SARS-CoV-2 infection: the D-dimer hypothesis. BMJ Case Rep. 2021 Mar 4;14(3):e242043. doi: 10.1136/bcr-2021-242043
 53. Korol AR, Bezditko PA, Bezkorovayna IM et al. Management of patients with chronic retinal diseases in the current conditions of the COVID-19 pandemic in the world and in Ukraine. Oftalmol Zh. 2021;90(2):82-85. doi: 10.31288/oftalmolzh202128284