

# Idiopathic Corneal Thinning and Spontaneous Perforation at Early Adulthood. A Case Report

Lukács Miklós Ágoston, Módis László

Department of Ophthalmology, Faculty of Medicine,  
University of Debrecen, Debrecen, Hungary



Miklós Ágoston Lukács, MD

Submitted to the editorial board: October 25, 2024

Accepted for publication: March 17, 2025

Available on-line: April 23, 2025

*The authors of the study declare that no conflict of interest exists in the compilation, theme and subsequent publication of this professional communication, and that it is not supported by any pharmaceutical company. The study has not been submitted to another journal and is not printed elsewhere.*

*This case study was performed in accordance with the tenets of the Helsinki Declaration. We certify that all applicable institutional and governmental regulations concerning the ethical use of human volunteers were followed during this research.*

Correspondence address:

Nagyterdei krt. 98

Debrecen

4032 Hungary

E-mail: lukacs.miklos@med.unideb.hu

## SUMMARY

**Aim:** To report a case of progressive corneal thinning and spontaneous corneal perforation in the setting of recurrent keratoconjunctivitis of undetermined etiology in a 20-year-old female patient.

**Material and methods:** Longitudinal follow-up of the reported case was performed with regular slit-lamp examination, anterior segment optical coherence tomography, and laboratory evaluation. Relevant scientific literature was reviewed to discover potential etiologies and causes of the reported case.

**Case report:** Recurrent bilateral keratoconjunctivitis was detected and followed up in a 20-year-old female patient. Long-standing blepharitis and several ocular inflammatory episodes were observed involving the conjunctiva and cornea causing corneal thinning and irregular astigmatism on both eyes. Patient's history, physical and laboratory examination did not reveal any systemic inflammatory or dermatological disorder. After 4 years from the onset of symptoms, spontaneous corneal perforation was observed on the right eye and treated with amniotic membrane transplantation. At that time, eyelid margin culture was positive for *Streptococcus mitis*. The graft healed completely with paracentral stromal scarring. Best spectacle corrected visual acuity was 20/25 OD and 20/40 OS a month after the procedure.

**Conclusion:** Corneal and ocular surface inflammation is a potential multifactorial disease. Bacterial hypersensitivity, atopy and dermatological disorders such as atopic dermatitis and rosacea may play a role in recurrent keratitis, corneal thinning and eventually corneal perforation. Frequent and regular follow-ups are required to detect complications early as well as to discover all possible local and systemic contributing factors of keratoconjunctivitis.

**Key words:** keratitis, conjunctivitis, hypersensitivity, corneal perforation

*Čes. a slov. Oftal., 81, 2025, No. x, p.*

## INTRODUCTION

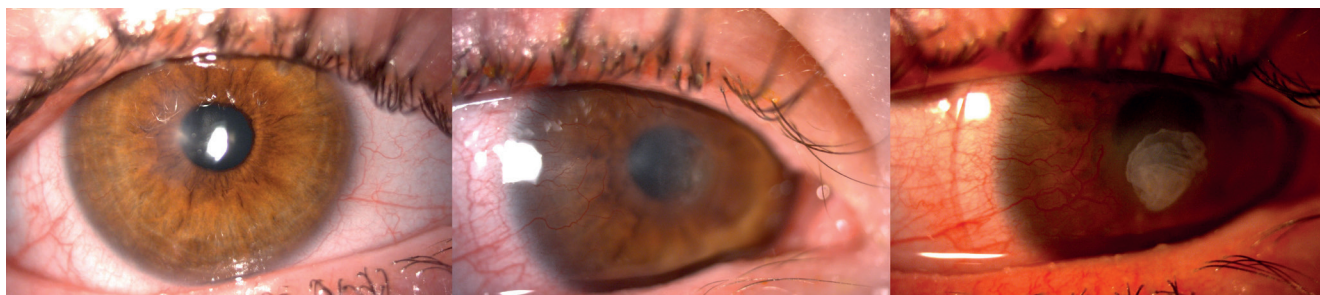Non-infectious corneal inflammation is a relatively rare ocular disease which is usually associated with systemic inflammatory conditions. Rheumatoid arthritis, systemic lupus erythematosus and other connective tissue diseases can be responsible for the ocular complications of systemic inflammation [1]. Infectious agents can precipitate the immune response and tissue damage in herpetic stromal keratitis, in corneal phlyctenule caused by tuberculosis as well as in catarrhal infiltrates and other forms of bacterial hypersensitivity induced corneal inflammation [2]. Another causative group comprises dermatological disorders such as acne rosacea and atopic dermatitis [3–6]. Common ocular manifestations of these

etiologies involve the eyelid, palpebral and bulbar conjunctiva, cornea and sclera [1,2]. Although the molecular pathogenesis of these diseases is diverse, similarities occur in the ocular signs and symptoms. Long-standing recurrent conjunctivitis and keratitis may be present which responds well to topical anti-inflammatory eye drops however, this therapy alone provide mostly a transient solution. Ocular surface and corneal complications are recurrent conjunctival injection, corneal epithelial erosions, stromal infiltrates, superficial stromal vascularization, scarring, and corneal thinning [1–3]. In this report, we discuss a case of progressive corneal thinning and spontaneous perforation caused by recurrent ocular surface inflammation of undetermined etiology in a 20-year-old lady.

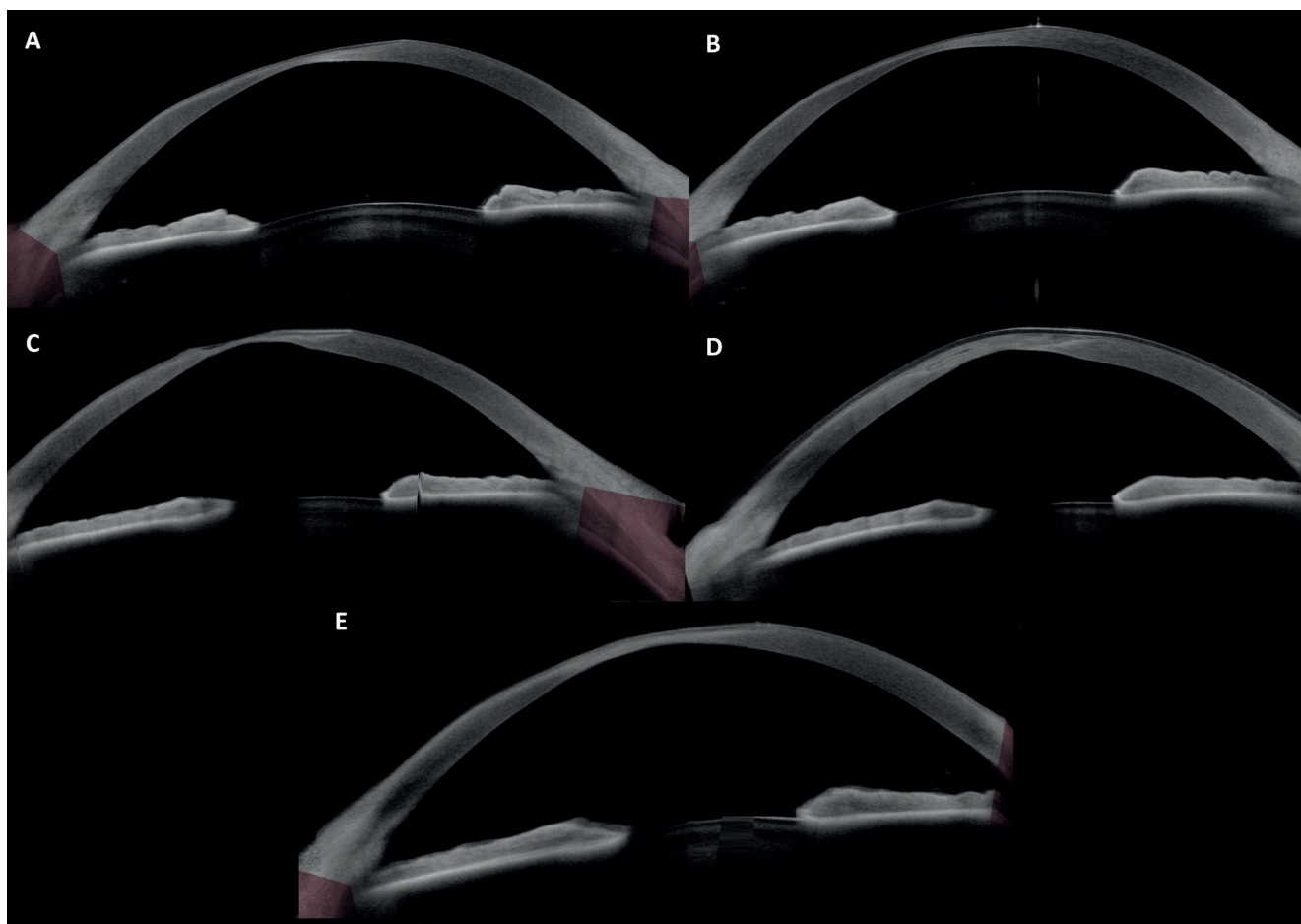
### Case report

A 20-year-old female patient suffered from recurrent bilateral ocular inflammation since she was 17 years old. The patient did not wear contact lenses. Symptoms waxed and waned, did not show seasonal association and consisted of eye redness, pain, blurry vision and sometimes runny nose. The patient reported abdominal discomfort after consuming milk, egg or banana. Slit lamp examination revealed blepharitis, conjunctival injection, corneal infiltrates bilaterally with active super-

ficial stromal vascularization when active phase of the disease was present (Figure 1). The patients' subjective symptoms (fluctuating bilateral eye redness) started in March 2020, however, she sought medical attention only after 9 months from the onset. At the first ophthalmic evaluation, right eye was inflamed showing conjunctival injection, and multiple small non-staining corneal infiltrates. Paracentral stromal scarring of the left cornea was already present. Between November 2020 and August 2024, altogether 50 follow-ups took place at our



**Figure 1.** Slit lamp images of the right eye. Paracentral corneal opacity without inflammation was present in the inactive phase of the disease after several inflammatory episodes (left). Temporal superficial stromal vascularization and central infiltrates with perforation in the active inflammatory phase (middle). One week after surgery, amniotic graft and bandage contact lens was in place (right)



**Figure 2.** Anterior segment optical coherence tomography of the right eye. Progressive corneal thinning could be detected in the inflammatory phase (A–C). Amniotic graft and bandage contact lens were in place 1 week after surgery (D). Amniotic graft healed completely with paracentral stromal scarring (E)

outpatient department. These were either scheduled follow-ups or spontaneous visits due to worsening symptoms. The exact number of inflammatory episodes could not be determined since these episodes varied greatly in duration and severity. Best corrected visual acuity was between 20/50 and 20/32 during inflammatory episodes. When no symptoms nor signs of active inflammation were present, peripheral and paracentral corneal scarring and thinning could be detected, and visual acuity was unaffected (20/20 Snellen bilaterally with myopic correction) in the first 3 years of the disease. Corneal axial curvature and thickness were monitored regularly with anterior segment optical coherence tomography (Figure 2) from October 2023. The ocular inflammation responded usually well to topical corticosteroid treatment. Dexamethasone, fluorometholone or hydrocortisone drops were used over weeks or months during active inflammation depending on the severity of the corneal involvement. Among these agents, fluorometholone was used in the majority of cases: it was applied 3 to 5 times a day to control the active flares of the disease. The dose was then gradually reduced to once a day as a preventive therapy between flares. (Table 1) Topical antibiotics were used based on the slit lamp signs and were reserved for instances when bacterial infection could not be excluded

(large epithelial defect, advancing stromal thinning, discharge; bacterial culture was taken only once, June 2024). Topical and systemic acyclovir was applied as well, however, the patient demonstrated intolerance to topical treatment (worsening eye redness and pain) and systemic acyclovir with topical corticosteroid did not show better clinical response compared to topical corticosteroid monotherapy. Systemic inflammatory disease was ruled out by physical and laboratory examination (normal immunoglobulin and CRP levels, HLA-B27 negativity), Table 2. Cutaneous allergy (Prick) tests were negative and no other local inflammatory process was detected. No dermatological symptoms nor signs of atopic dermatitis and acne rosacea were observed. Therefore, systemic and local therapy were implemented only due to ophthalmic indications. Regular eyelid care was recommended to the patient since the first appearance of blepharitis, which was occasionally further addressed with topical tetracycline or combined tobramycin and dexamethasone ointment (Table 1). However, despite of treatment the process disclosed recurrence. Therefore, systemic doxycycline was recommended for three weeks. Hordeolum removal was performed once on the left lower eyelid. Ocular surface inflammation was treated with artificial tears and corticosteroid drops in the aforementioned manner.

**Table 1.** Local and systemic therapy applied in the course of 4 years. (OD: right eye, OS: left eye, OU: both eyes)

Date	Treatment follow-up	Reason of changes in treatment
11/2020	Fluorometholone 3 to 5 times a day OU depending of the severity of inflammatory signs. In inactive phase dose was reduced to once a day OU.	
06/2021	Dexamethasone and tobramycin ointment 3 times a day for blepharitis OD. Regular eyelid care has been recommended since then.	blepharitis
12/2022	Tetracycline ointment 3 times a day ointment for blepharitis OU.	
01/2023	Topical acyclovir 4 times a day OU, tetracycline ointment 3 times a day on the eyelid margins.	epithelial defect
02/2023	Systemic treatment for 3 weeks: systemic oral acyclovir daily 5x400 mg, doxycycline daily 1x50 mg. Subconjunctival dexamethasone OU, then fluorometholone 3 times a day OU.	active inflammation, epithelial defect
03/2023	Hydrocortisone 3 times a day OU.	
05/2023	Fluorometholone twice a day OU.	
11/2023	Levofloxacin 4 times a day OU for a week, then fluorometholone 3 times a day.	epithelial defects OU
02/2024	Neomycin 5 times a day OS for a week, then moxifloxacin 5 times a day a week OS. Fluorometholone twice a day OU.	signs of bacterial conjunctivitis OS: purulent discharge
03/2024	Fluorometholone twice a day OU.	
06/2024	Moxifloxacin 3 times a day OU, fluorometholone twice a day OU, tetracycline ointment 3 times a day on the eyelid margins.	purulent discharge and blepharitis OU, positive conjunctival swab (Streptococcus mitis)
07/2024	Amniotic membrane transplantation OD. Postoperative care: moxifloxacin 3 times, tobramycin 5 times a day OD, flurometholone 3 times a day OU. Systemic therapy doxycycline 1x100 mg a day for a week, then clarithromycin 1x250 mg a day for 2 weeks. Fluorometholone was gradually tapered to twice a day OD, once a day OS.	spontaneous corneal perforation OD
11/2024	Systemic maintenance therapy doxycycline daily 1x50 mg for 3 months. Only artificial tears was used as local therapy.	

After a 2-month period of long-standing fluctuation in inflammatory signs and symptoms, fluorescein staining showed a Seidel positive test at the thinnest corneal area in the right eye. In this period, bacterial culture of the eyelid margin revealed *Streptococcus mitis* colonization. Spontaneous perforation was detected and amniotic membrane transplantation was performed. The amniotic membrane was fixed with tissue glue and bandage contact lens was fitted on it. After a week, the amniotic transplant was in place. Topical antibiotics was used for 4 weeks after the perforation. In addition, topical flurometholone and systemic doxycycline therapy was implemented at that time as well. Based on antibiotic sensitivity of the culture, doxycycline was then replaced with clarithromycin. (Table 1) After a month, amniotic graft healed completely with paracentral scarring. Best spectacle corrected visual acuity was 20/25 OD and 20/40 OS with myopic correction. Doxycycline was applied again (daily 50 mg), this time as a systemic maintenance therapy for three months to further aid corneal healing. Six months after the perforation, no active inflammation was observed on either eyes with a best corrected visual acuity of 20/20 OD and 20/32 OS. OCT-based corneal optical densitometry values were calculated in greyscale unit (GSU, ranging from 0 to 100) and compared between two follow-up sessions on the right eye. Corneal densitometry value within the pupil border and corneal thickness at the thinnest point were higher 1 month after the amniotic membrane transplantation than 9 months before the perforation when the right eye was not inflamed (31.54 GSU vs. 29.36 GSU and 280  $\mu$ m vs. 234  $\mu$ m).

**Table 2.** Laboratory tests performed. All tests yielded negative results

Full blood count
CRP
Rheumatoid factor
IgG, IgA, IgM
Anti-CCP antibody
ANA HEp-2
Complement 3. and 4.
Anti-Sm antibody
Anti-Sm/RNP antibody
Anti SS-A and SS-B antibody
Anti-Scl-70 antibody
Anti-Jo-1 antibody
Anti-endomysium IgA and IgG
Anti-transglutaminase IgA and IgG
HLA-B27

## DISCUSSION

In this report, we presented a case of a recurrent ocular surface inflammation of undetermined etiology which resulted in progressive corneal thinning and spontaneous perforation. This case was unusual in two ways. First, the exact cause of the disease could not be established. Second, spontaneous corneal perforation at this young age is particularly rare. The most probable causes of recurrent ocular inflammation were atopic keratoconjunctivitis and bacterial hypersensitivity. Herpetic etiology was considered as well during the follow-up, however, the bilateral appearance and the poor response to antiviral treatment did not support this diagnosis. Atopic keratoconjunctivitis is the most serious form of allergic eye disease and caused by the combination of type I and IV hypersensitivity [3]. Two other forms of ocular allergy are allergic conjunctivitis and vernal keratoconjunctivitis. During slit lamp examination, no conjunctival giant papillae were found and corneal erosion were present only when active inflammation occurred and was not caused by the mechanical effect of undetected giant papillae. The female sex also made this diagnosis less probable. Although laboratory and physical examination did not confirm the allergic etiology, multidisciplinary consultation concluded that it could not be ruled out and in fact may have been one of the potential contributing factors to the disease. Besides inflammatory corneal tissue damage, corneal thinning as a part of ectatic disorder may have played an important role as well. The association of corneal ectasia and atopy is a well-known phenomenon. In a case series by Nivenius et al, three patients with seven incidents of corneal perforation caused by atopic keratoconjunctivitis were presented [3]. All of the three patients had other atopic diseases, such as atopic dermatitis, asthma bronchiale or hay fever and two of them wore hard contact lenses due to keratoconus. In comparison with our case, these patients were older (70, 52, 47 years vs. 20 years old) and had atopic diseases affecting other organs (skin, respiratory tract) as well. The same study reviewed the reported cases of corneal perforation associated with ectatic disorder. Atopic disease was detected in 6 of 27 patients with spontaneous corneal perforation and corneal ectasia. The prevalence of corneal ectasia in atopic disease found by previous studies ranged between 4 and 27% [4,7–10].

In the other hand, our case may be explained by ocular rosacea or bacterial hypersensitivity as well. Eye involvement was reported to occur in 3% to 58% of patients with rosacea [6]. Its manifestation ranges from mild dry eye and blepharitis to severe keratitis. The latter may cause corneal thinning and steepening. [6] However, no dermatological signs for rosacea (central facial erythema, telangiectasia) were found. Dermatological diseases (atopic dermatitis, rosacea) damage the function of the Meibomian glands thus make the eyelid margin susceptible to bacterial colonization and inflammation. Our case demonstrated recurrent blepharitis and hordeolum making the bacterial hypersensitivity a highly probable



factor of the ocular inflammation. This was confirmed by a positive eyelid margin culture. *Streptococcus mitis* is a frequent member of the natural human flora, however, it is occasionally pathogenic [11]. Corneal phlyctenule and catarrhal infiltrates are vascularized lesions in the peripheral cornea that can have the appearance of a prominent nodule or an ulcer [2,11]. Some etiologies do not rule each other out, ocular rosacea and bacterial hypersensitivity can occur at the same time [5]. Catarrhal corneal stromal infiltrates usually have a clear space between them and the limbus and may also spread parallel to it. In contrast, corneal phlyctenule can be found directly at the limbus and may invade central regions. [2] Corneal phlyctenules may cause perforation [12]. Furthermore, severe visual impairment in this condition can occur even at a young age [11].

Treatment consists of intermittent local corticosteroid drops, and preservative free artificial tears as in our case. In addition, Culbertson et al found that long-standing (even 6 to 10 months of duration) oral tetracycline or erythromycin treatment produces long-lasting remission of the disease in the affected children [13]. Although

doxycycline is the preferred medication nowadays. In rare cases of corneal perforation, surgical intervention is recommended. Amniotic membrane transplantation is a successful and definitive solution for spontaneous corneal perforation, however, regular re-evaluation of the etiology and systemic involvement of the disease in an interdisciplinary manner is crucial in avoiding future ophthalmic complications.

## CONCLUSION

To summarize, progressive corneal thinning and spontaneous perforation can occur at a young age in patients with recurrent ocular surface inflammation and keratitis. Atopic keratoconjunctivitis, ocular rosacea, bacterial hypersensitivity and atopy associated corneal ectasia have to be taken into consideration in the differential diagnosis. Appropriate long-term systemic and local therapy is crucial in managing and preventing future complications since pathogenesis of the chronic recurrent inflammation may be multifactorial.

## REFERENCES

1. Módos L, Süveges I. A szemfelszín allergiás és immunpatológiai betegségei [Allergic and immunopathological diseases of the ocular surface]. *Orv Hetil.* 2023 Oct 29;164(43):1686-1692. Hungarian. doi: 10.1556/650.2023.32910
2. Mondino BJ. Inflammatory diseases of the peripheral cornea. *Ophthalmology.* 1988 Apr;95(4):463-472. doi: 10.1016/s0161-6420(88)33164-7
3. Nivenius E, Montan P. Spontaneous corneal perforation associated with atopic keratoconjunctivitis: a case series and literature review. *Acta Ophthalmol.* 2015 Jun;93(4):383-387. doi: 10.1111/aos.12617
4. Garrity JA, Liesegang TJ. Ocular complications of atopic dermatitis. *Can J Ophthalmol.* 1984 Feb;19(1):21-24.
5. Neiberg MN, Sowka J. Phlyctenular keratoconjunctivitis in a patient with Staphylococcal blepharitis and ocular rosacea. *Optometry.* 2008 Mar;79(3):133-137. doi: 10.1016/j.optm.2007.09.015
6. Dursun D, Piniella AM, Pflugfelder SC. Pseudokeratoconus caused by rosacea. *Cornea.* 2001 Aug;20(6):668-669. doi: 10.1097/00003226-200108000-00024
7. Totan Y, Hepşen IF, Cekiç O, Gündüz A, Aydin E. Incidence of keratoconus in subjects with vernal keratoconjunctivitis: a videokeratographic study. *Ophthalmology.* 2001 Apr;108(4):824-827. doi: 10.1016/s0161-6420(00)00664-3
8. Tabbara KF. Ocular complications of vernal keratoconjunctivitis. *Can J Ophthalmol.* 1999 Apr;34(2):88-92.
9. Foster CS, Calonge M. Atopic keratoconjunctivitis. *Ophthalmology.* 1990 Aug;97(8):992-1000. doi: 10.1016/s0161-6420(90)32477-6
10. Tuft SJ, Kemeny DM, Dart JK, Buckley RJ. Clinical features of atopic keratoconjunctivitis. *Ophthalmology.* 1991 Feb;98(2):150-158. doi: 10.1016/s0161-6420(91)32322-4
11. Juberias JR, Calonge M, Montero J, Herreras JM, Saornil MA. Phlyctenular keratoconjunctivitis a potentially blinding disorder. *Ocul Immunol Inflamm.* 1996;4(2):119-123. doi: 10.3109/09273949609079642
12. Ostler HB. Corneal perforation in nontuberculous (staphylococcal) phlyctenular keratoconjunctivitis. *Am J Ophthalmol.* 1975 Mar;79(3):446-448. doi: 10.1016/0002-9394(75)90620-0
13. Culbertson WW, Huang AJ, Mandelbaum SH, Pflugfelder SC, Boozalis GT, Miller D. Effective treatment of phlyctenular keratoconjunctivitis with oral tetracycline. *Ophthalmology.* 1993 Sep;100(9):1358-1366. doi: 10.1016/s0161-6420(93)31475-2