

Subhyaloid Hemorrhage after Bungee Jumping Experience. A Case Report

Stráňava J., Ugarova D., Stěpanov A.

Department of Ophthalmology, Regional Hospital Mladá Boleslav, a.s.,
Czech Republic



MUDr. Ján Stráňava

Submitted to the editorial board: May 7, 2025

Accepted for publication: June 2, 2025

Available on-line: August 10, 2025

The authors of the study declare that no conflict of interests exists in the compilation, theme and subsequent publication of this professional communication, and that it is not supported by any pharmaceuticals company. The study has not been submitted to any other journal or printed elsewhere, with the exception of congress abstracts and recommended procedures.

Correspondence address:

Oční oddělení, Oblastní nemocnice Mladá
Boleslav, a.s., Czech Republic
Tř. Václava Klementa 147
290 03 Mladá Boleslav, Czech Republic
E-mail: janstranavaa@gmail.com

SUMMARY

Subhyaloid hemorrhage is defined as bleeding between the internal limiting membrane (ILM) and the posterior hyaloid membrane. The condition typically manifests itself in acute visual impairment. Causes include the Valsalva maneuver, Terson's syndrome, age-related macular degeneration (ARMD), trauma, hypercoagulable and hyperviscosity states, uncontrolled blood pressure, diabetes mellitus and leukemia. Prolonged presence of blood in the macular region can lead to the development of an epiretinal membrane and toxic damage to the retinal pigment epithelium and photoreceptors due to iron ions. In this case report we present a 32-year-old patient who was treated at the ophthalmology outpatient clinic of the Regional Hospital in Mladá Boleslav for subhyaloid hemorrhage in the right eye following a bungee jumping experience. The patient was successfully treated with Nd-YAG hyaloidotomy, which resulted in a good therapeutic outcome and full restoration of visual acuity.

Key words: Subhyaloid hemorrhage, Hyaloidotomy, Nd-YAG laser

Čes. a slov. Oftal., 81, 2025, No. x, p.

INTRODUCTION

Subhyaloid hemorrhage is defined as the presence of blood between the internal limiting membrane (ILM) and the posterior hyaloid membrane. In the case that the hemorrhage is localized in the macular region, this condition may be the cause of a sudden deterioration of central visual acuity (CVA). The main causes of subhyaloid hemorrhage include the Valsalva maneuver, subarachnoid hemorrhage, age-related macular degeneration (AMD), ocular trauma, hypercoagulable and hyperviscosity states, arterial hypertension, diabetes mellitus and leukemia [1–3].

A number of methods are used in the treatment of subhyaloid hemorrhage. One of the options is observation of the patient with gradual spontaneous resorption of the blood, which may take several weeks to months, depending on the extent of the hemorrhage. This procedure entails the risk of macular complications. The long-term presence of blood in the macular region may lead to the development of an epiretinal membrane and toxic damage to the retinal pigment epithelium (RPE) and photoreceptors caused by iron ions from erythrocytes [3,4].

Other options for treatment include Nd-YAG hyaloidotomy, displacement of hemorrhage with the aid of

intravitreal application of gas and the tissue activator plasminogen, or pars plana vitrectomy [1,5]. Nd-YAG hyaloidotomy is a minimally invasive method in which an opening is made in the hyaloid membrane with subsequent evacuation of hemorrhage into the vitreous space. Successful performance should lead to an improvement of CVA within a few days [3,4]. Nd-YAG hyaloidotomy was first used for drainage of subhyaloid hemorrhage into the vitreous cavity in 1988 [6].

CASE REPORT

A man aged 32 years was acutely treated at the ophthalmology outpatient clinic of the Regional Hospital in Mladá Boleslav for sudden deterioration of vision in the right eye. The patient's general condition was healthy, and he was not using any medication. The subjective complaints included a pronounced deterioration of vision and a feeling of blind spots in the center of the visual field in the right eye. It was determined from the patient's personal medical history that one day before the examination he had taken part in bungee jumping, after which the above-mentioned complaints appeared.

Initial CVA in the right eye was on the level of light perception, central scotoma was recorded on the perimeter (Figure 1). Objectively the anterior segment of

both eyes was within the norm. Subhyaloid hemorrhage was evident on the posterior segment of the right eye of a size of 3.5 papillary diameter (PD), blood vessels were within the norm, the retina was without notable changes. Optical coherence tomography (OCT) together with photo documentation (Figure 2) confirmed a diagnosis of subhyaloid hemorrhage in the right eye.

Based on the diagnosis and the new finding, we decided to perform Nd-YAG hyaloidotomy on the right eye in the lower part of the hemorrhage. Photo documentation of the ocular fundus before and after the procedure

is presented in Figure 3 and 4. At a subsequent follow-up examination two days later an improvement of CVA was recorded at "counting fingers from a distance of 1 meter", and gradual resorption of the hemorrhage was evident on the ocular fundus of the right eye (Figure 5). At further follow-up examinations there was a gradual improvement of CVA in the right eye to a final value of 20/20. We also performed control OCT scans and ocular fundus photography (Figure 6).

DISCUSSION

Subhyaloid hemorrhage is the presence of blood between the internal limiting membrane (ILM) and the

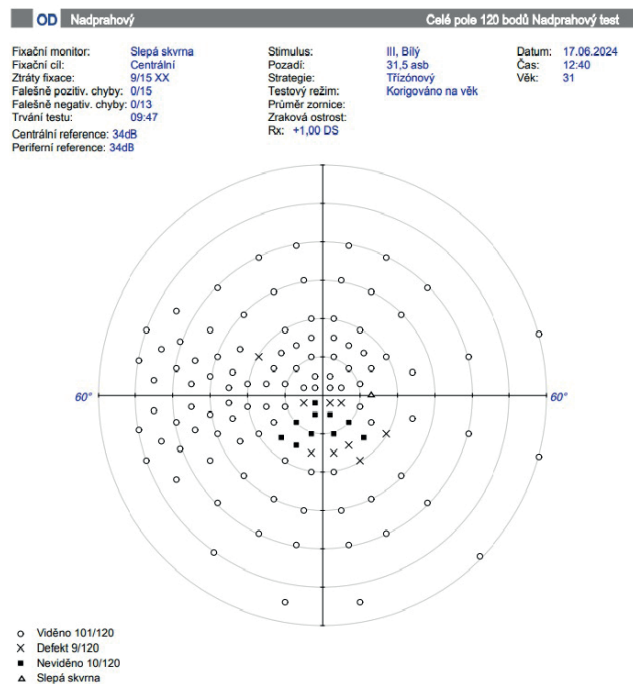


Figure 1. Perimeter of the right eye with central scotoma

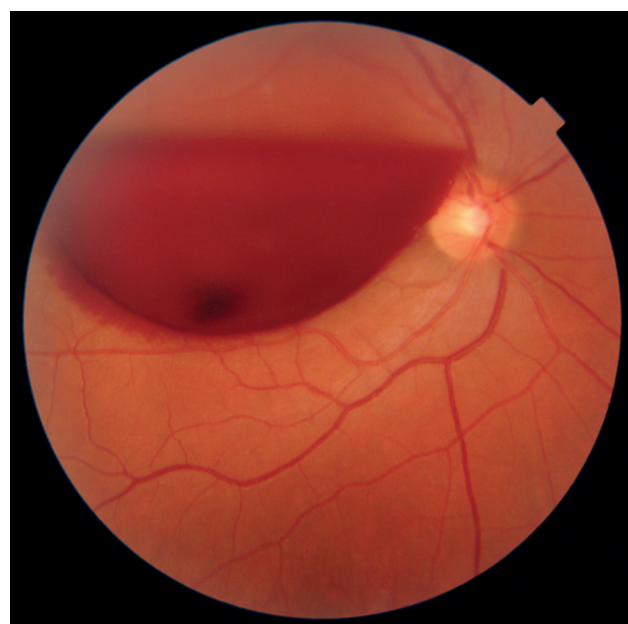

Figure 3. Photo of macular area before Nd-YAG hyaloidotomy

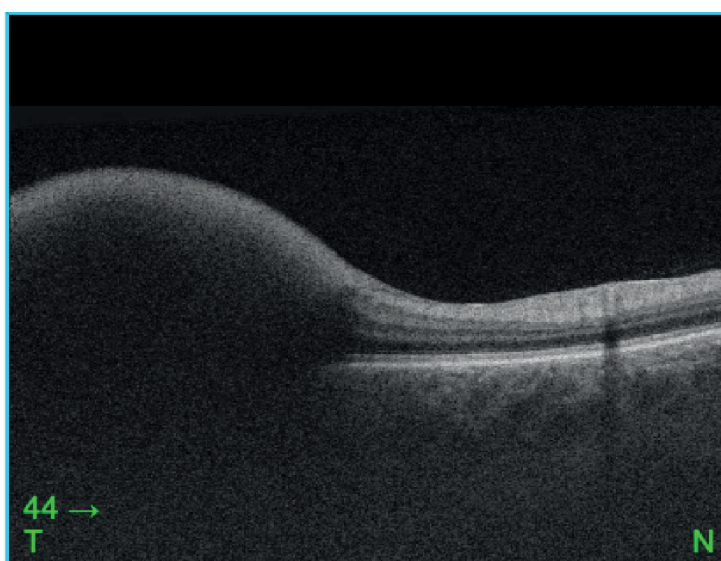
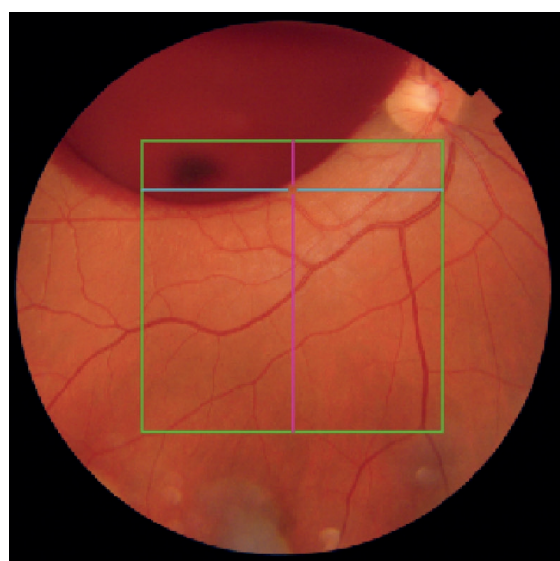


Figure 2. Photo documentation and optical coherence tomography (OCT) of the fundus

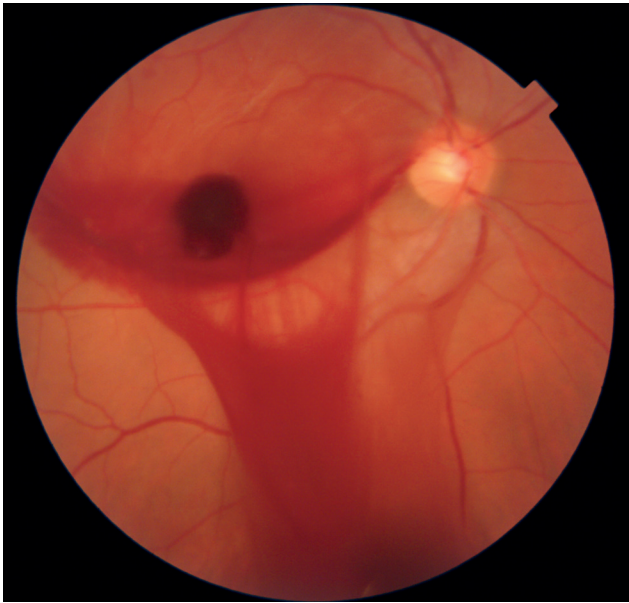


Figure 4. Photo of macular area after Nd-YAG hyaloidotomy

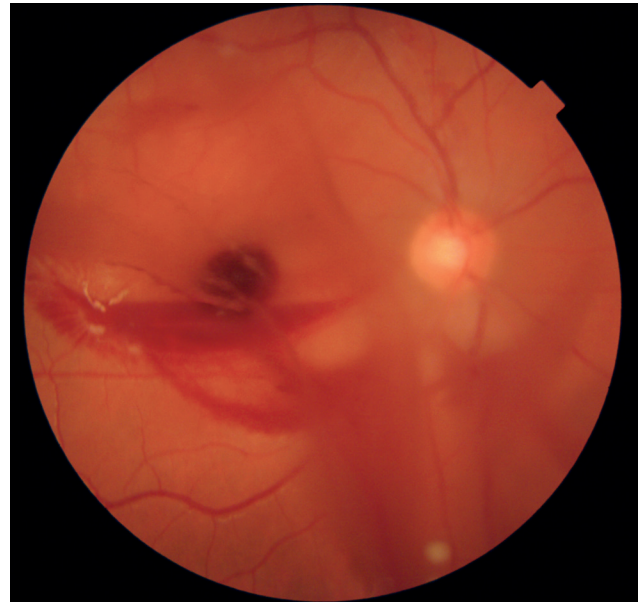

Figure 5. Photo of the fundus after two days, with gradual absorption of bleeding

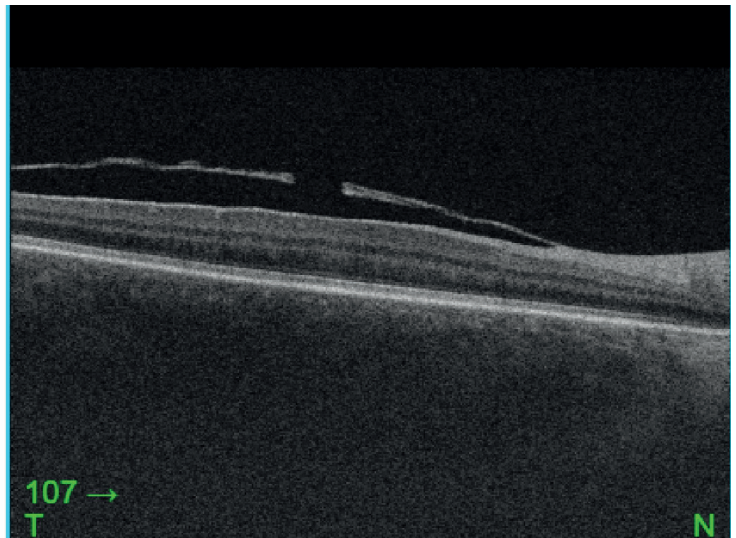
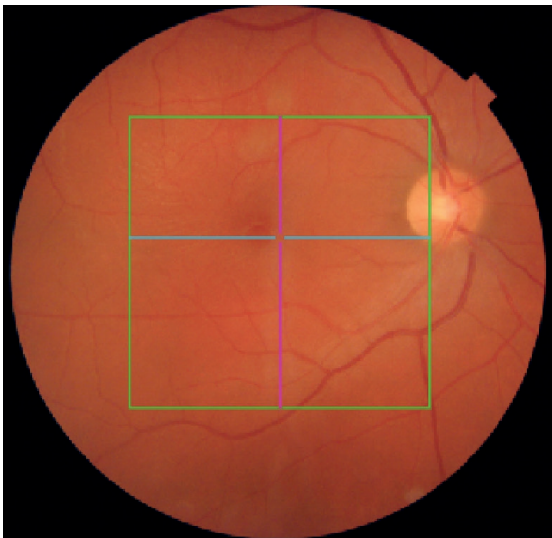

Figure 6. Optical coherence tomography (OCT) and photo of the posterior segment showing the fenestrum after Nd-YAG hyaloidotomy and absorbed hemorrhage

posterior hyaloid membrane. In ophthalmology it represents an acute condition which may result in sudden loss of sight. The options for treatment include observation, pars plana vitrectomy and Nd-YAG hyaloidotomy [1]. In our case, with reference to the fresh finding we decided in favor of Nd-YAG hyaloidotomy because it concerns a minimally invasive and effective method of therapy [5,7].

We performed the procedure the next day, the laser energy was set at 5 mJ. The successful performance of the procedure requires patient cooperation, sufficient mydriasis and an experienced doctor [5,7]. The maximum energy of the laser should be within the range of 5 mJ to 12 mJ. However, cases have been described in the literature in which laser energy of as high as 50 mJ was used without side effects on the retina [1,5,6].

The effectiveness of Nd-YAG laser in the treatment of subhyaloid hemorrhage has been described in the international literature [6]. In most cases an improvement of CVA was achieved within one month of the procedure. Complications within the time frame of six months are minimal, one case of retinal detachment is described in a myopic patient, and the development of macular hole in another case [6]. Failure of treatment may occur if coagulum forms beneath the posterior hyaloid membrane without drainage into the hyaloid space through the created opening. Final visual acuity is also influenced by the underlying triggering pathology, which may include leukemic retinopathy, Eales disease, Valsalva retinopathy, Terson's syndrome, macroaneurysms or retinopathy at high altitudes [6,7].

CONCLUSION

Nd-YAG hyaloidotomy is one of the options for treatment of subhyaloid hemorrhage. It is a noninvasive and effective method which can lead to rapid restoration of visual functions. On our case we recorded

an improvement of visual functions in our patient, in which CVA improved to a value of 20/20. However, when using this method it is necessary to consider the length of duration, size and localization of hemorrhage, and last but not least the experience of the attending physician.

REFERENCES

1. Kováčová M, Kousal B, Meliška M, Fichtl M, Dušková J, Kalvodová B. Treatment Options for Premacular and Sub-Internal Limiting Membrane Haemorrhage. *Cesk Slov Oftalmol.* 2021;77(6):289-294. doi: 10.31348/2021/34
2. Faisal Murtaza, Syed Fawad Rizvi, Syeda Aisha Bokhari, Zeeshan Kamil. Management of Macular Pre-Retinal Subhyaloid hemorrhage by Nd:Yag laser hyaloidotomy. *Pak J Med Sci.* 2014 Mar-Apr;30(2):339-342. doi: 10.12669/pjms.302.4689
3. Heichel J, Kuehn E, Eichhorst A, Hammer T, Winter I. Nd:YAG Laser Hyaloidotomy for the Treatment of Acute Subhyaloid Hemorrhage: A Comparison of Two Cases. *Ophthalmol Ther.* 2016;5:111-120, doi: 10.1007/s40123-015-0043-1
4. Alarfaj MA, Hasen AA, Al-Yami SS, Traumatic subhyaloid macular hemorrhage with complete resolution following Neodymium-Doped Yttrium Aluminium Garnet Laser. *Am J Ophthalmol Case Rep.* 2018; Jan 12;9:85-87. doi: 10.1016/j.ajoc.2018.01.020
5. Khadka D, Bhandari S, Bajimaya S, Thapa R, Paudyal G, Pradhan E. Nd:YAG laser hyaloidotomy in the management of Premacular Subhyaloid Hemorrhage. *BMC Ophthalmol.* 2016 Apr 18;16:41. doi: 10.1186/s12886-016-0218-0
6. Kuruvilla O, Munie M, Shah M, Desai U, Miller JA, Ober MD. Nd:YAG membranotomy for preretinal hemorrhage secondary to valsalva retinopathy. *Saudi J Ophthalmol.* 2014 Feb 28;28(2):145-151. doi: 10.1016/j.sjopt.2014.02.006
7. Karagiannisa D, Kontadakisa GA, Flanagan D. Nd:YAG laser for preretinal hemorrhage in diabetic retinopathy. *Am J Ophthalmol Case Rep.* 2018 Jan 12;10:8-9. doi: 10.1016/j.ajoc.2018.01.027