

# Refractive Lensectomy in Patients with Fuchs' Endothelial Dystrophy

Brožková Markéta<sup>1,2</sup>, Vlasák Ondřej<sup>1</sup>, Havlíčková Lenka<sup>1</sup>, Hlinomazová Zuzana<sup>1</sup>

<sup>1</sup>Lexum Eye Clinics, Czech Republic

<sup>2</sup>Faculty of Medicine in Hradec Králové, Charles University, Czech Republic



MUDr. Markéta Brožková, FEBO

Submitted to the editorial board: November 10, 2025

Accepted for publication: November 15, 2025

Available on-line: January 9, 2026

*The authors declare that the creation and topic of the paper and its publication are not in conflict of interest and are not supported by any pharmaceutical company. The paper has not been submitted to any other journal or published elsewhere.*

Correspondence address:

Antala Staška 1670/80

140 00 Praha 4 – Krč

E-mail: brozkova@lexum.cz

## SUMMARY

**Purpose:** The aim of this retrospective study was to evaluate the outcomes of refractive lens exchange (RLE) with implantation of extended depth of focus (EDOF) and trifocal intraocular lenses (IOLs) in presbyopic hyperopic patients diagnosed with Fuchs endothelial corneal dystrophy (FECD), and to retrospectively assess preoperative criteria suitable for RLE indication.

**Materials and Methods:** The study included 17 patients (34 eyes) with hyperopia and FECD who underwent RLE with implantation of EDOF or trifocal IOLs at Lexum Eye Clinics between 2022 and 2024. The mean follow-up period was 13 months, and the mean patient age was  $56 \pm 5$  years. Evaluated parameters included preoperative and postoperative refraction, visual acuity, endothelial microscopy, central pachymetry, and posterior corneal backscatter.

**Results:** The mean preoperative uncorrected distance visual acuity was 0.68 logMAR, improving postoperatively to 0.01 logMAR. The mean corrected distance visual acuity improved from 0.01 logMAR preoperatively to -0.01 logMAR postoperatively. Postoperative uncorrected intermediate and near visual acuities were 0.07 logMAR and 0.10 logMAR, respectively. According to Krachmer's classification of endothelial microscopy, 14 patients had grade 1, one patient grade 2, and two patients grade 3 FECD. The mean postoperative endothelial cell density was 2595 cells/mm<sup>2</sup>, with a coefficient of variation of 30 % and hexagonality of 50 %. No statistically significant difference was found between preoperative and postoperative pachymetry values ( $p = 0.184$ ). The mean posterior corneal backscatter was 14.7 GSU preoperatively and 16.8 GSU postoperatively.

**Conclusion:** Fuchs endothelial corneal dystrophy has long been considered a contraindication for refractive lens exchange. In our cohort of motivated patients, the outcomes were highly satisfactory. Key parameters – central pachymetry, endothelial microscopy, and posterior corneal backscatter remained stable over time. When properly indicated, carefully performed RLE may be a viable option for presbyopia correction in patients with early-stage FECD.

**Key words:** Fuchs endothelial corneal dystrophy, RLE, trifocal IOL, EDOF IOL, endothelial microscopy

*Čes. a slov. Oftal., 81, 2025, No. x, p.*

## INTRODUCTION

Refractive lens exchange (RLE) is a surgical procedure indicated in presbyopic patients. It allows correction of refractive errors and presbyopia through implantation of premium intraocular lenses. Historically, it has been indicated in patients with physiologically normal eyes without ocular pathology, or serious systemic diseases, and in patients who are motivated to achieve spectacle independence.

At present, with increasing demands for an active lifestyle after the age of 50, the indications for refractive surgery are expanding. The development of advanced diagnostic and imaging methods, along with modern

intraocular lenses employing various optical principles, has significantly broadened both our diagnostic and therapeutic options, enabling a more precise indication for RLE. In recent years, indication criteria have even been extended to include patients with certain conditions that were previously considered contraindications, particularly Fuchs endothelial corneal dystrophy (FECD). This is supported by recent outcomes of extended depth-of-focus (EDOF) and multifocal lens implantation in those patients with cataract [1].

Fuchs endothelial dystrophy is a bilateral, slowly progressive, multifactorial disease in which genetics, environmental factors, and oxidative stress contribute to the development. Risk factors associated with oxidati-

ve stress include metabolic syndrome, diabetes mellitus, smoking, and alcohol consumption [2]. The disease was first described in 1910 by Ernst Fuchs [3]. In most cases, FECD occurs sporadically without clear hereditary transmission. However, in a subset of patients, an autosomal dominant form with variable expressivity and incomplete penetrance has been reported, reflecting the complex and heterogeneous genetic background of the disease [4]. The most common genetic cause is expansion of a trinucleotide repeat (CTG18.1) in the intronic region of the TCF4 gene, representing the most prevalent known disorder associated with trinucleotide repeat expansion [5]. Both the length of the repeat and zygosity may influence the phenotypic expression of the disease. Additional genetic causes include mutation in the alpha subunit of collagen type VIII (COL8A2), located on chromosome 1. This encodes an extracellular matrix protein which disrupts the structure of Descemet's membrane (DM) [6]. This rare form of FECD is characterized by an early onset, with clinical manifestations already in the first decade of life, and full expression in the second and third decades. Late-onset forms of FECD, presenting typically in the 5<sup>th</sup> to 6<sup>th</sup> decades, occur more frequently in individuals of European descent and in women [5,7]. This finding suggests a potential influence of hormonal factors in postmenopausal women, particularly regarding estrogen levels, which play a role in maintaining endothelial cell function. A decline in estrogen may contribute to the onset or progression of the disease.

There are additional rare variants of mutations causing FECD, the pathogenic significance of which has not always been unequivocally established [5]. Examples include mutations in the SLC4A11 [8,9], TCF4 [10,11], LOXHD1 [12,13], AGBL1 [14], and ZEB1 [12] genes. Based on these findings, the disease has also been categorized in the international classification according to the level of understanding of its genetic background.

The International Classification of Corneal Dystrophies (IC3D, 3rd edition) [4] divides FECD into three categories. Category 1: Early-onset FECD (COL8A2). Category 2: FECD in patients with identified genetic loci. Category 3: FECD in patients without known inheritance.

Today, FECD represents the most frequent indication for corneal transplantation [15–18]. Its prevalence in the population ranges from approximately 3.8% to 11%, with variations in genetic background among different races [19–21]. A recent meta-analysis estimated the global prevalence at 7.33% [22].

Clinical evaluation of FECD remains challenging from a quantitative perspective, as validated measurable parameters allowing clear differentiation of disease stages are still lacking [23]. Numerous classifications exist, but none describe FECD with sufficient precision. The basic and original classification is Krachmer's classification from 1978 [24], which divides FECD into five stages according to the number of guttae in the central cornea and the presence of edema. In our clinical practice, a classification based on

clinical signs, pachymetry, and endothelial microscopy is used more frequently. Mild form: mild guttae without corneal edema, normal pachymetry, and cell density (CD) > 1,500 cells/mm<sup>2</sup>. Moderate form: corneal edema with morning blur, increased pachymetry > 600 µm, and reduced CD < 1,000 cells/mm<sup>2</sup>. Advanced form: persistent edema, bullous keratopathy and vision loss, severe corneal thickening, and critically low CD < 500 cells/mm<sup>2</sup>.

These traditional classifications of FECD stages are now gradually being supplemented with additional parameters for quantitative corneal assessment [25]. These include evaluation of tomographic parameters obtained using the Pentacam Scheimpflug camera. Among the parameters relevant to early stages are the magnitude and changes in higher-order aberrations, as well as, for example, the loss of circular (oval) isopachs on pachymetric maps [26,27]. To assess changes responsible for blurred vision, values of posterior corneal backscatter from corneal densitometry and the DM/AD ratio (the average ratio of Descemet's membrane density versus area density) are now being employed [26,28].

In FECD, light is subtly scattered by the guttae, which are initially located in the central corneal region. When the guttae become confluent, the degree of light scatter increases significantly. For this reason, diffractive intraocular lenses have generally not been recommended in FECD patients. In recent years, however, this standpoint has been re-evaluated, as newer lenses with extended depth of focus (EDOF) do not rely on the diffractive imaging principle used by most trifocal lenses. As a result, they provide higher-quality visual performance, even in cases where the optical media are not entirely clear – particularly in our context, at the level of the posterior corneal surface.

Early lens surgery has particular significance in patients with FECD, especially when cataract is also present [29,30]. Early intervention minimizes the mechanical stress on the endothelium during phacoemulsification, thereby reducing the postoperative risk of endothelial decompensation. This consideration led us to offer motivated patients RLE, which can often be performed using low-energy phacoaspiration, thereby minimizing endothelial stress. At the same time, we were aware that, in the event of progressive endothelial decompensation, endothelial transplantation (DMEK, Descemet Membrane Endothelial Keratoplasty) remains an available option, with currently very favorable outcomes. All patients were thoroughly informed about this possibility.

In the context of EDOF and trifocal intraocular lens implantation in patients with FECD, proper indication for RLE requires consideration of multiple corneal parameters. These parameters have only been described in the literature in recent years [25–28]. We selected several of them for retrospective evaluation, to verify whether patient selection had been appropriate. At the same time, we analyzed the refractive outcome, visual acuity, and the accuracy of the procedure.

## MATERIALS AND METHODS

In this retrospective study, we evaluated all patients diagnosed with FECD who underwent RLE with implantation of EDOF or trifocal intraocular lenses between January 2022 and December 2024. The study included 17 patients treated at Lexum Eye Clinics (Prague, Brno, Ostrava, České Budějovice), representing less than 1% (0.90%) of all patients who underwent RLE at these centers during the same period.

The evaluated dataset consisted of 34 eyes of 17 presbyopic patients (8 women and 9 men) who received trifocal or EDOF intraocular lenses and had a diagnosis of FECD confirmed by endothelial microscopy. The refractive error was either hyperopia or hyperopia with astigmatism. Patients had no other comorbidities. The mean age of the patients was  $56 \pm 5$  years (from 47 to 63 years). The mean follow-up period was 13 months (from 6 to 30 months).

Surgery was performed under standard local anesthesia by an experienced surgeon through a 2.2 mm incision, placed either along the steep axis of astigmatism or temporally in an astigmatically neutral position for toric lenses. In all patients, a dispersive ophthalmic viscosurgical device (OVD) Viscoat (Alcon Laboratories, Inc., USA; hereafter Alcon), or Healon EndoCoat (Johnson & Johnson Surgical Vision, Inc., USA; hereafter J&J) was used at the beginning of the procedure and supplemented as needed during surgery. Phacoaspiration was performed in all patients, using the Centurion system (Alcon) with low flow parameters and minimal phacoemulsification time. The use of a handpiece with an integrated pressure sensor (ACTIVE SENTRY, Alcon) is advantageous, allowing further reduction of flow parameters during surgery, which are important risk factors for corneal endothelial damage [29–32]. Intraocular lens implantation was performed under a cohesive OVD Provisc (Alcon) or HealonPro (J&J). At the end of surgery, the viscoelastic material was aspirated, leaving a thin layer of dispersive material on the endothelium. When necessary, very gentle hydration of the incision was also considered essential.

All patients underwent a comprehensive ophthalmological examination prior to surgery, including endothelial microscopy (TOPCON Co., Japan), Pentacam imaging (OCULUS Optikgeräte GmbH, Germany), and macular

and optic nerve OCT (Carl Zeiss Meditec AG, Germany). Visual acuity was measured using an LCD optotype (CC-100 LCD chart system, TOPCON Co., Japan) preoperatively, as well as at 1 day, 1 week, and 2 months postoperatively, and at the final follow-up at least 6 months after surgery. Decimal values were converted to the logarithm of the minimum angle of resolution (logMAR) scale for analysis. Pachymetry measurements obtained by Pentacam, endothelial microscopy, and the NIDEK tonopachymeter (NIDEK CO., LTD, Japan) were comparable. Endothelial microscopy parameters and corneal densitometry values, with a focus on posterior corneal backscatter, were also evaluated.

In our study, patients were initially classified according to the standard classification, based on clinical signs of the disease, endothelial microscopy, and pachymetry (using the scale: mild, moderate, and advanced FECD). For more precise categorization, patients were retrospectively assessed according to Krachmer's classification.

Statistical analyses were performed, using STATISTICA software (version 12.7, Dell Software Inc., USA). Data normality was assessed with the Shapiro-Wilk test. Differences between preoperative and postoperative values of the observed variables were evaluated, using the parametric paired t-test. A p-value < 0.05 was considered statistically significant.

## RESULTS

All patients had mild forms of FECD according to the standard classification, with an absolute endothelial cell count above  $1500/\text{mm}^2$ , without clinically apparent corneal edema or subjective complaints of morning haze. Patient distribution according to Krachmer's classification is presented in Table 1.

The types of intraocular lenses implanted in patients with FECD are summarized in Table 2. In patients with Grade 1 disease, the most frequently implanted lenses were non-diffractive EDOF lenses AcrySof IQ Vivity DFT015 and Vivity Toric DFT215 and DFT315 (Alcon). A smaller proportion of patients received the diffractive EDOF lens Tecnis Symphony ZXR (J&J), trifocal lenses Claron PanOptix CNWTT0 (Alcon) and Tecnis Synergy ZFR00V (J&J). One patient with Grade 2 and two patients with Grade 3, according to Krachmer's classification, received AcrySof IQ Vivity DFT015 lenses.

**Table 1.** Krachmer classification

		number of patients
<b>Grade 0</b>	0 central guttae	0
<b>Grade 1</b>	1 to 12 central, non-confluent guttae in at least 1 eye; usually asymptomatic	14
<b>Grade 2</b>	More than 12 central, non-confluent guttae in at least 1 eye	1
<b>Grade 3</b>	1 to 2 mm zone of central confluent guttae in the horizontal plane	2
<b>Grade 4</b>	2 to 5 mm zone of central confluent guttae in the horizontal plane	0
<b>Grade 5</b>	Zone of central confluent guttae greater than 5 mm, with or without corneal stromal or epithelial oedema	0

**Table 2.** Types of implanted intraocular lenses in our dataset

Types of implanted lenses	number of eyes
AcrySof IQ Vivity DFT015	24
AcrySof IQ Vivity Toric DFT215 and DFT315	2
Tecnis Symphony ZXR00	2
Clareon PanOptix CNWTT0	2
Tecnis Synergy ZFR00V	4
<b>Total</b>	<b>34</b>

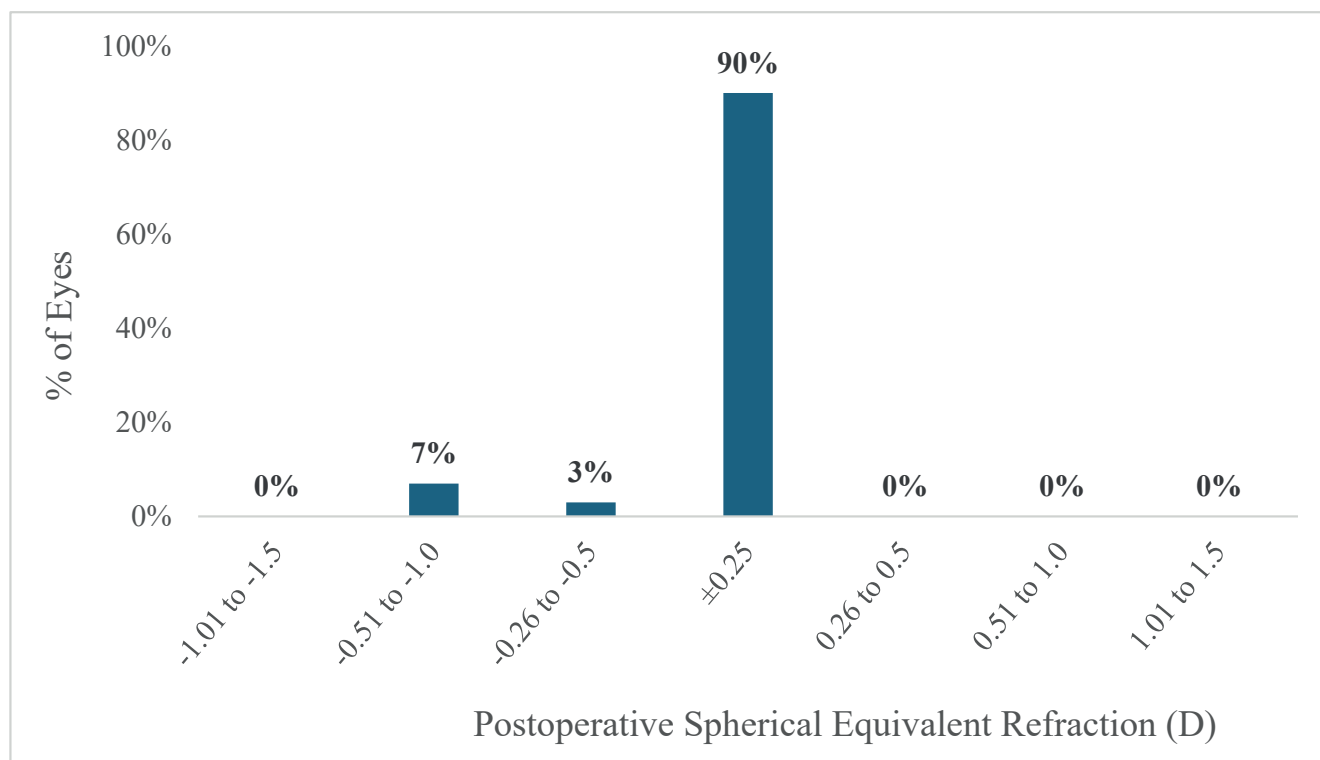
Detailed results of preoperative and postoperative refraction and visual acuity are presented in Table 3. The mean spherical equivalent improved from a preoperative value of  $2.42 \pm 1.33$  D to a postoperative value of  $-0.09 \pm 0.23$  D. In 90% of eyes, it ranged within  $\pm 0.25$  D (Figure 1).

Uncorrected distance visual acuity (UDVA) improved from a preoperative value of  $0.68 \pm 0.45$  logMAR to  $0.01 \pm 0.04$  logMAR at the last follow-up. Both uncorrected and corrected distance visual acuity remained stable

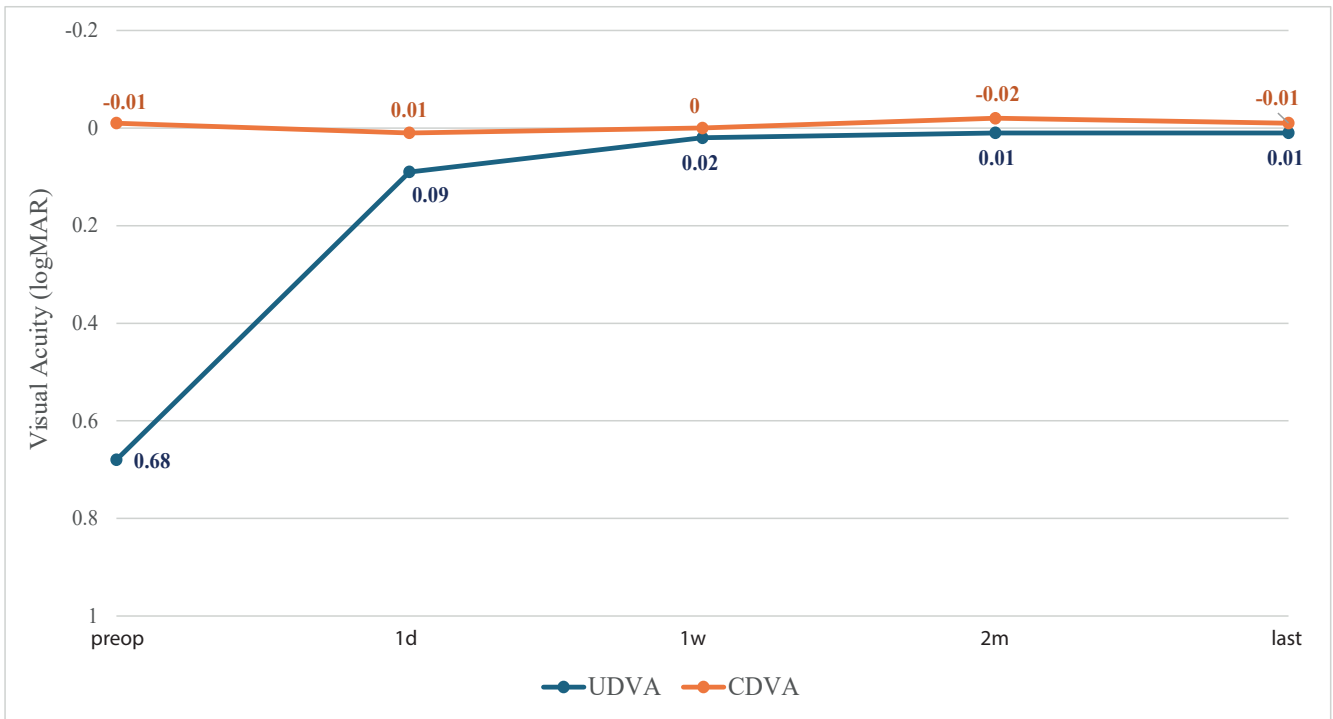
**Table 3.** Preoperative and postoperative outcomes of refraction and visual acuity

	preoperatively mean $\pm$ SD (min to max)	postoperatively mean $\pm$ SD (min to max)
<b>Sphere (D)</b>	$2.62 \pm 1.42$ (0.75 to 7)	$-0.03 \pm 0.19$ (-0.5 to 0.5)
<b>Astigmatism (D)</b>	$-0.4 \pm 0.4$ (-1.75 to 0)	$-0.12 \pm 0.21$ (-0.5 to 0)
<b>SE (D)</b>	$2.42 \pm 1.33$ (0.75 to 6.13)	$-0.09 \pm 0.23$ (-0.75 to 0.25)
<b>MonoUDVA (logMAR)</b>	$0.68 \pm 0.45$ (0.1 to 2)	$0.01 \pm 0.04$ (-0.08 to 0.1)
<b>MonoCDVA (logMAR)</b>	$-0.01 \pm 0.06$ (-0.08 to 0.1)	$-0.01 \pm 0.03$ (-0.08 to 0)
<b>MonoUIVA (logMAR)</b>	-	$0.07 \pm 0.04$ (0.00 to 0.10)
<b>MonoCNVA (logMAR)</b>	$0.01 \pm 0.03$ (0 to 0.1)	$0.01 \pm 0.05$ (0 to 0.1)
<b>MonoUNVA (logMAR)</b>	-	$0.1 \pm 0.13$ (0 to 0.4)
<b>BinoUDVA (logMAR)</b>	-	$-0.03 \pm 0.05$ (-0.08 to 0.05)
<b>BinoUNVA (logMAR)</b>	-	$0.16 \pm 0.08$ (0 to 0.3)

SD – standard deviation, D – diopter, SE – spherical equivalent, MonoUDVA – monocular uncorrected distance visual acuity, logMAR – logarithm of the minimum angle of resolution, MonoCDVA – monocular corrected distance visual acuity, MonoUIVA – monocular uncorrected intermediate visual acuity, MonoCNVA – monocular corrected near visual acuity, MonoUNVA – monocular uncorrected near visual acuity, BinoUDVA – binocular uncorrected distance visual acuity, BinoUNVA – binocular uncorrected near visual acuity

**Graph 1.** Accuracy of spherical equivalent after surgery

D – diopter



**Graph 2.** Monocular uncorrected (UDVA) and corrected (CDVA) distance visual acuity in time  
logMAR – logarithm of the minimum angle of resolution

**Table 4.** Preoperative and postoperative outcomes of pachymetry, chosen parameters of endothelial microscopy and corneal backscatter

	preoperatively mean ±SD (min to max)	postoperatively mean ±SD (min to max)
<b>Pachymetry (µm)</b>	537 ±28 (495 to 584)	542 ±29 (486 to 593)
<b>CD (cells/mm<sup>2</sup>)</b>	2595 ±307 (1950 to 3241)	2468 ±450 (1680 to 2980)
<b>CV (%)</b>	32 ±7 (19 to 45)	30 ±7 (15 to 46)
<b>HEX (%)</b>	50 ±12 (23 to 63)	50 ±17 (20 to 65)
<b>Backscatter (GSU)</b>	14.7 ±1.8 (12.2 to 17.3)	16.2 ±2.0 (14.2 to 18.9)

SD – standard deviation, GSU – grey scale unit

over time (Figure 2). Corrected near visual acuity (CNVA) was 0.01 logMAR both pre- and postoperatively. Postoperative uncorrected intermediate visual acuity (UIVA) was  $0.07 \pm 0.04$  logMAR, and uncorrected near visual acuity (UNVA) was  $0.1 \pm 0.13$  logMAR.

Preoperative and postoperative values of central pachymetry, endothelial microscopy, and posterior corneal backscatter are summarized in Table 4. The mean central pachymetry was  $537 \pm 28$  µm preoperatively, and  $542 \pm 29$  µm postoperatively, with no statistically significant difference between these values ( $p = 0.184$ ).

CD decreased from  $2595 \pm 307$  cells/mm<sup>2</sup> preoperatively to  $2468 \pm 450$  cells/mm<sup>2</sup> postoperatively. The coefficient of variation (CV) was 32% preoperatively and 30% postoperatively. Hexagonality (HEX) remained 50% both before and after surgery. Measurements of posterior corneal backscatter revealed a mean preoperative value of  $14.7 \pm 1.8$  GSU (Gray Scale Units), and a postoperative va-

lue of  $16.2 \pm 2.0$  GSU (Table 4). None of these parameters showed a significant difference between pre- and postoperative measurements.

## DISCUSSION

Refractive lens exchange in patients with FECD is no longer as controversial as it once was, given the current possibilities of endothelial transplantation. In our study of presbyopic patients diagnosed with FECD undergoing RLE with implantation of EDOF or trifocal intraocular lenses, we focused on the refractive outcome, its stability, and possible progression of corneal and endothelial parameters following a carefully performed procedure. All 17 patients had mild FECD. Although in more advanced stages it may be preferable to perform endothelial transplantation first, followed by intraocular lens implantation, all our patients had preoperative corrected

visual acuity ranging from 0.0 to -0.01 logMAR. Therefore, transplantation was not necessary.

Postoperatively, UDVA improved substantially from 0.68 logMAR to 0.01 logMAR, and these values remained stable during follow-up. The mean uncorrected near visual acuity was 0.1 logMAR, reflecting that most patients received an AcrySof IQ Vivity lens. Some of these patients require low-prescription reading glasses postoperatively. However, due to preoperative counseling, they are satisfied with the surgical outcome. Patients with trifocal lenses do not require any spectacle correction. The high surgical accuracy is demonstrated by the spherical equivalent, which approached emmetropia postoperatively, with 90% of eyes within  $\pm 0.25$  D.

One of the parameters for assessing postoperative progression of corneal dystrophy is central pachymetry of the cornea. In our cohort, pachymetry values did not differ significantly between pre- and postoperative measurements, averaging around 540  $\mu\text{m}$ . Endothelial microscopy often yields false-positive results, due to automated endothelial cell counts performed outside the guttae. However, this evaluation is comparable over time, if images are taken from the same central corneal location. Postoperative evaluation of the endothelium outside the guttae in our patients demonstrated practically physiological CD values. CV was approximately 30%, while HEX was slightly reduced.

Commonly used parameters and classifications are not sufficient for determining staging or evaluating corneal stability in FECD, particularly in the early stages of the disease, which are difficult to diagnose using biomicroscopy or endothelial microscopy. In recent years, there has been increasing discussion that certain corneal parameters may serve as indicators of early-stage FECD.

One of these parameters is asymmetric isopachs [27] on the anterior corneal surface, caused by uneven corneal deturgescence. Asymmetric isopachs are also present in patients with tear film abnormalities. We were unable to retrospectively differentiate these changes in detail, and therefore this parameter was not included in our evaluation.

Posterior corneal backscatter from densitometry also appears to be a suitable parameter for early stages of FECD and for assessing disease progression [26,28]. In our cohort, posterior corneal backscatter values did not differ significantly between pre- and postoperative measurements. Longer-term follow-up is therefore required. According to the literature, another potentially useful quantitative indicator is the DM/AD ratio (the average ratio of Descemet's membrane density versus area density), which allows objective detection of early changes in Descemet's membrane [28]. Detailed knowledge of the morphological and optical changes in the cornea during early stages of the disease is crucial, not only for diagnosis but also for selecting the most appropriate type of intraocular lens.

In patients with FECD, the choice of intraocular lens should generally favor non-diffractive optics, even when

patients are strongly motivated to achieve spectacle independence. Diffractive optics, among other effects, induce light scatter. Changes in the cornea, in FECD particularly on the posterior corneal surface, further increase this scatter. Posterior higher-order aberrations of the cornea also contribute to this effect [26]. The result is mildly blurred vision, which can be difficult to correct.

When selecting an intraocular lens, it is necessary to consider not only the optical design, but also the material of the implant. Future endothelial transplantation (DMEK) may become necessary. For this reason, a strictly hydrophobic lens material should be preferred, as published data indicate that hydrophilic lenses may develop opacification following contact with an air bubble in the anterior chamber [33].

To preserve postoperative endothelial stability, attention must also be paid to the risk factors, about which patients should be informed. Potential toxic effects of medications should be considered, particularly antiglaucoma carbonic anhydrase inhibitors and products containing the preservative benzalkonium chloride (BAK), which should be avoided in the postoperative period. In patients with dry eye disease, the use of preservative-free artificial tears is therefore recommended. FED is a slowly progressive disorder that typically develops over several decades. The rate of progression depends on a combination of genetic factors, age, risk factors, and environmental influences. These aspects must be discussed thoroughly with patients during the preoperative evaluation to ensure that they understand the nature of the disease, are aware of the potential risks associated with surgery, and have realistic expectations. Consideration of these factors is also essential for subsequent follow-up care, which includes controlling systemic comorbidities such as diabetes mellitus, hypertension, and metabolic syndrome. Recommendations additionally focus on a diet rich in antioxidants, as well as not smoking and limiting alcohol consumption.

## CONCLUSION

Early-stage Fuchs endothelial dystrophy does not present an absolute contraindication to refractive lensectomy. This is supported by our favorable refractive outcomes, stable corneal parameters, and the fact that none of the patients experienced postoperative endothelial decompensation or disease progression. Our mean follow-up period of one year is relatively short, however. This issue will require further, more detailed research, particularly with the use of emerging corneal parameters that may serve as indicators of early FECD stages and assist in surgical decision-making.

With appropriate selection of motivated patients, gentle surgical technique, and regular postoperative monitoring, this method of addressing presbyopia in individuals with early-stage FECD may be considered both safe and effective.

## REFERENCES

- Blau-Most M, Reitblat O, Levy A, Assia EI, Kleinmann G. Clinical outcomes of presbyopia-correcting intraocular lenses in patients with Fuchs endothelial corneal dystrophy. *Sci Rep*. 2023 Jan 16;13(1):786.
- Hamill CE, Schmedt T, Jurkunas U. Fuchs endothelial cornea dystrophy: a review of the genetics behind disease development. *Semin Ophthalmol*. 2013;28(0):281-286.
- Son HS, Villarreal G, Meng H, Eberhart CG, Jun AS. On the origin of 'guttatae'. *Br J Ophthalmol*. 2014 Sep;98(9):1308-1310.
- Weiss JS, Rapuano CJ, Seitz B, et al. IC3D Classification of Corneal Dystrophies-Edition 3. *Cornea*. 2024 Apr;43(4):466.
- Liu S, Sadan AN, Bhattacharyya N, et al. Genetic and demographic determinants of Fuchs endothelial corneal dystrophy risk and severity. *JAMA Ophthalmol*. 2025 Apr 1;143(4):338-347.
- Gottsch JD, Sundin OH, Liu SH, et al. Inheritance of a novel COL8A2 mutation defines a distinct early-onset subtype of Fuchs corneal dystrophy. *Invest Ophthalmol Vis Sci*. 2005 Jun;46(6):1934-1939.
- Zhang J, McGhee CNJ, Patel DV. The molecular basis of Fuchs' endothelial corneal dystrophy. *Mol Diagn Ther*. 2019 Feb;23(1):97-112.
- Malhotra D, Loganathan SK, Chiu AM, Lukowski CM, Casey JR. Human corneal expression of SLC4A11, a gene mutated in endothelial corneal dystrophies. *Sci Rep*. 2019 Jul 4;9(1):9681.
- Khuc E, Bainer R, Wolf M, et al. Comprehensive characterization of DNA methylation changes in Fuchs endothelial corneal dystrophy. *PLoS One*. 2017;12(4):e0175112.
- Nakagawa T, Honda T, Yuasa T, et al. The TCF4 gene regulates apoptosis of corneal endothelial cells in Fuchs endothelial corneal dystrophy. *Invest Ophthalmol Vis Sci*. 2025 Mar 6;66(3):16.
- Baratz KH, Tosakulwong N, Ryu E, et al. E2-2 protein and Fuchs's corneal dystrophy. *N Engl J Med*. 2010 Sep 9;363(11):1016-1024.
- Rao BS, Ansar S, Arokiasamy T, et al. Analysis of candidate genes ZEB1 and LOXHD1 in late-onset Fuchs' endothelial corneal dystrophy in an Indian cohort. *Ophthalmic Genet*. 2018 Aug;39(4):443-449.
- Wesdorp M, Schreur V, Beynon AJ, et al. Further audiovestibular characterization of DFNb77, caused by deleterious variants in LOXHD1, and investigation into the involvement of Fuchs corneal dystrophy. *Clin Genet*. 2018;94(2):221-231.
- Riazuddin SA, Vasanth S, Katsanis N, Gottsch JD. Mutations in AGBL1 cause dominant late-onset Fuchs corneal dystrophy and alter protein-protein interaction with TCF4. *Am J Hum Genet*. 2013 Oct 3;93(4):758-764.
- Soh YQ, Kocaba V, Pinto M, Mehta JS. Fuchs endothelial corneal dystrophy and corneal endothelial diseases: East meets West. *Eye*. 2020 Mar;34(3):427-441.
- Feizi S. Corneal endothelial cell dysfunction: etiologies and management. *Ther Adv Ophthalmol*. 2018;10:2515841418815802.
- Darlington JK, Adrean SD, Schwab IR. Trends of penetrating keratoplasty in the United States from 1980 to 2004. *Ophthalmology*. 2006 Dec;113(12):2171-2175.
- Mathews P, Benbow A, Corcoran K, DeMatteo J, Philippy B, Van Meter W. 2022 Eye Banking Statistical Report-Executive Summary. *Eye Bank Corneal Transplant Commun*. 2023 Sep;2(3):e0008.
- Zoega GM, Fujisawa A, Sasaki H, et al. Prevalence and risk factors for cornea guttata in the Reykjavik Eye Study. *Ophthalmology*. 2006 Apr;113(4):565-569.
- Higa A, Sakai H, Sawaguchi S, et al. Prevalence of and risk factors for cornea guttata in a population-based study in a southwestern island of Japan: the Kumejima study. *Arch Ophthalmol (Chicago, Ill. 1960)*. 2011 Mar;129(3):332-336.
- Kitagawa K, Kojima M, Sasaki H, et al. Prevalence of primary cornea guttata and morphology of corneal endothelium in aging Japanese and Singaporean subjects. *Ophthalmic Res*. 2002;34(3):135-138.
- Aiello F, Gallo Afflitto G, Ceccarelli F, Cesareo M, Nucci C. Global prevalence of Fuchs endothelial corneal dystrophy (FECD) in adult population: a systematic review and meta-analysis. *J Ophthalmol*. 2022;2022(1):3091695.
- Liu S, Kandakji L, Stupnicki A, et al. Current applications of artificial intelligence for Fuchs endothelial corneal dystrophy: a systematic review. *Transl Vis Sci Technol*. 2025 Jun 6;14(6):12.
- Krachmer JH, Purcell JJ, Young CW, Bucher KD. Corneal endothelial dystrophy: a study of 64 families. *Arch Ophthalmol (Chicago, Ill. 1960)*. 1978 Nov;96(11):2036-2039.
- Nanda GG, Alone DP. Review: current understanding of the pathogenesis of Fuchs' endothelial corneal dystrophy. *Mol Vis*. 2019;25:295-310.
- Wacker K, McLaren JW, Amin SR, Baratz KH, Patel SV. Corneal high-order aberrations and backscatter in Fuchs' endothelial corneal dystrophy. *Ophthalmology*. 2015 Aug 1;122(8):1645-1652.
- Sun SY, Wacker K, Baratz KH, Patel SV. Determining subclinical edema in Fuchs endothelial corneal dystrophy: revised classification using Scheimpflug tomography for preoperative assessment. *Ophthalmology*. 2019 Feb 1;126(2):195-204.
- Chu HY, Hsiao CH, Chen PYF, Ma DHK, Chang CJ, Tan HY. Corneal backscatters as an objective index for assessing Fuchs' endothelial corneal dystrophy: a pilot study. *J Ophthalmol*. 2017;2017(1):8747013.
- Kaup S, Pandey SK. Cataract surgery in patients with Fuchs' endothelial corneal dystrophy. *Community Eye Health*. 2019;31(104):86-87.
- Ali M, Cho K, Srikumaran D. Fuchs dystrophy and cataract: diagnosis, evaluation and treatment. *Ophthalmol Ther*. 2023 Apr 1;12(2):691-704.
- Lee NSY, Ong K. Risk factors for corneal endothelial cell loss after phacoemulsification. *Taiwan J Ophthalmol*. 2024 Jan 30;14(1):83-87.
- Okoye GS, Bonabe D, Obasi CU, et al. Visual outcomes and complications after phacoemulsification and small incision manual cataract surgery in two eye hospitals. *J Fr Ophtalmol*. 2025 Jan;48(1):104353.
- Fernández J, Sánchez-García A, Rodríguez-Vallejo M, Piñero DP. Systematic review of potential causes of intraocular lens opacification. *Clin Experiment Ophthalmol*. 2020 Jan;48(1):89-97.