

The Role of Prophylactic Topical Administration of Antibiotics in Uncomplicated Cataract Surgery in the Era of Intracameral Antibiotics. Opinion Article

Rambousek Jan^{1,2*}, Straňák Zbyněk^{1,2*}, Němec Pavel^{3,4},
Bartoš Hynek^{2,5}, Studený Pavel^{1,2,3}

¹Department of Ophthalmology, Kralovské Vinohrady University Hospital, Prague, Czech Republic

²³rd Faculty of Medicine, Charles University, Prague, Czech Republic

³Lexum – network of eye clinics, Czech Republic

⁴¹st Faculty of Medicine, Charles University, Prague, Czech Republic

⁵Department of Infectious Diseases, Bulovka University Hospital, Prague, Czech Republic

*These authors contributed equally to the article

Submitted to the editorial board: September 4, 2025

Accepted for publication: November 4, 2025

Available on-line: February 9, 2026

The authors of the study declare that no conflict of interests exists in the compilation, subject and subsequent publication of this professional communication, and that it is not supported by any pharmaceuticals company.



First author:

Jan Rambousek, MD

Corresponding author:

Zbyněk Straňák, MD, PhD, MHA
Oftalmologická klinika Fakultní nemocnice
Královské Vinohrady a 3. lékařské fakulty
Univerzity Karlovy v Praze
Šrobárova 1150/50
100 34 Praha 10
Czech Republic
E-mail: zbynek.stranak@fnkv.cz

SUMMARY

Introduction: Cataract surgery is one of the most commonly performed procedures in human medicine. Although the risk of postoperative inflammatory complications is low, their consequences can be devastating. The current global standard for preventing such complications is intracameral administration of antibiotics, while the role of prophylactic topical antibiotics in uncomplicated cases remains controversial.

Aim: The aim of this paper is to evaluate the available evidence regarding the effectiveness of topical antibiotic prophylaxis in uncomplicated cataract surgery in the era of routine intracameral antibiotic use.

Methods: The authors conducted a review of the recent literature and major clinical studies (ESCRS, Kaiser Permanente, Cochrane), comparing the incidence of endophthalmitis with the use of intracameral antibiotics alone versus in combination with postoperative topical antibiotics.

Results: Intracameral antibiotic administration significantly reduces the risk of endophthalmitis (up to 4.9-fold reduction according to the ESCRS study). There is no evidence that subsequent use of topical antibiotic drops further reduces the risk of infection in uncomplicated cases. Moreover, repeated topical antibiotic use increases the risk of patients developing antibiotic resistance and poses a significant financial and logistical burden.

Conclusion: In uncomplicated cataract surgery, postoperative topical antibiotics are not indicated when intracameral prophylaxis is applied. Their use should be reserved for high-risk cases only (e.g. following complicated surgery, in immunocompromised patients, or in the presence of chronic blepharitis).

Key words: antibiotic prophylaxis, endophthalmitis, intracameral administration

Čes. a slov. Oftal., 81, 2025, No. x, p.

INTRODUCTION

Cataract surgery is one of the most commonly performed procedures in human medicine. Approximately 4.5 million of these operations are performed every year within the European Union alone [1], while in the United States the number of operations is estimated at 4 million per year [2]. Approximately 160 000 cataract operations were performed in the Czech Republic in 2024, 89% of them in non-state healthcare facilities [3].

In recent decades the surgical approach to treating cataract has undergone fundamental transformations.

From the original routinely performed intracapsular and later extracapsular extraction of the cataract, which were associated with a higher incidence of perioperative and postoperative complications and the need for hospitalization, development has shifted towards modern and minimally invasive methods. Thanks to advances in microsurgery, in particular the introduction of phacoemulsification, construction of a multi-stage corneal tunnel in “clear corneal incision” (CCI) and the use of a soft intraocular lens implanted through a small incision (1.8–2.75 mm), there has been a marked reduction of the surgical burden and the risk of complications. This deve-

lopment has led to faster visual rehabilitation and a shortening of the period of convalescence. Current trends are directed towards simplifying surgical procedures, increasing safety, optimizing patient recovery and reducing the overall time of the procedure, which reflects a broader shift towards less invasive approaches across the entire spectrum of surgical disciplines – in which cataract surgery is no exception.

Infectious endophthalmitis (Figure 1) remains a serious complication to be taken into account, since despite its rare incidence it may result in permanent loss of sight. The frequency of acute infectious endophthalmitis is stated within the range of 0.062% to 0.327% [4], and since the introduction of intracameral cefuroxime this incidence has been reduced by up to a further two decimal points, to within the range of 0.007% to 0.0004% [5,6].

METHOD

A targeted review of the professional literature was conducted in the PubMed and Cochrane Library databases. The key words used included: “cataract surgery”, “endophthalmitis prophylaxis”, “intracameral antibiotics”, “topical antibiotics”. The search was limited to the period of 2000–2025, without any language limitations.

Only the most prestigious and highly quoted studies were included in the review, dealing with the incidence of endophthalmitis after cataract surgery in association with intracameral antibiotics and a combination of both methods. This review is not a systematic review according to the Preferred Reporting Items for Systematic Reviews and Meta-Analyses, but a targeted selection of the most prestigious and highly quoted studies. The selection of literature may therefore be hampered by a selection bias, and does not incorporate all the published studies on the theme in question.

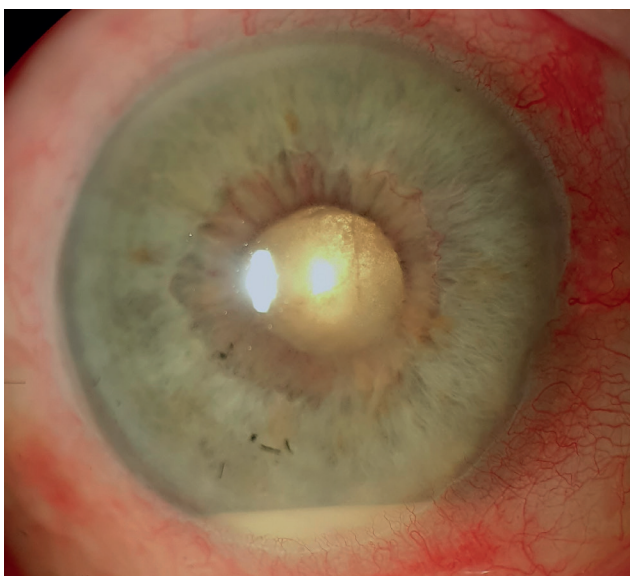


Figure 1. Clinical findings in exogenous endophthalmitis after cataract surgery

Risk factors of infectious complications

We divide risk factors for the occurrence of infectious endophthalmitis into ocular, perioperative and overall risk factors. Ocular risk factors primarily include disorders of the lacrimal apparatus such as blepharitis, disorders of drainage of the lacrimal pathways, wearing contact lenses or the presence of a prosthesis in the other eye. Perioperative risk factors are associated with a complicated course of surgery, such as impairment of the stability of the irrigation solution, long duration of the surgical procedure, rupture of the posterior capsule, loss of the vitreous, leaking wound after surgery, vitreous incarceration in the wound etc. Last but not least, systemic risks include e.g. diabetes mellitus or deteriorated immune condition of the patient. In all of these cases we encounter endophthalmitis substantially more frequently [7,8].

Preventive and prophylactic measures to prevent the occurrence of infectious complications

It has been demonstrated that bacterial cultures isolated from the vitreous of patients with postoperative endophthalmitis are of the same type as bacteria found on the eyelids or in the conjunctival sac. One of the main aims of prophylaxis against postoperative endophthalmitis is therefore the reduction of the quantity of bacteria on the eyelids and conjunctiva. It is precisely for this reason that emphasis is placed on two modalities reducing the amount of bacteria in the conjunctival sac, namely antibiotics and povidone iodine, which is considered an integral component of postoperative treatment [9,10].

Application of antibiotic drops in the postoperative period has its own specifics and limits. The effectiveness of topical antibiotics is limited primarily to the superficial structures of the eye, because permeability into the intraocular tissues is generally low [11].

Therapeutic levels of antibiotics (ATB) in the chamber fluid depend not only on the physical-chemical properties of the pharmaceutical, but also on a range of practical factors – in particular correct application technique, frequency and length of application, and last but not least also patient cooperation. There remains a risk of incorrect use, contamination of the dropper and loss of sterility during handling. Furthermore, local antibiotic preparations contain preservative agents, the presence of which is essential for ensuring the sterility of the pharmaceutical, but which entail a risk of development of allergic reactions and toxic effect on the ocular surface. Numerous applications of pharmaceuticals in drops may be demanding for some patients and may reduce compliance with the therapeutic recommendations. Last but not least, it is necessary to mention that the prescription and application of antibiotic drops represents a considerable financial cost for both the healthcare system and the patient.

With regard to the number of performed cataract operations, one of the most serious adverse effects of blanket prophylactic application of antibiotics is the increased risk of patients developing antibiotic resistance [12].

With regard to antibiotic resistance, in general it applies that repeated or long-term use of antibiotics increases resistance more pronouncedly than one-time application. In the case of repeated or long-term application of antibiotics, the selection pressure on individual bacterial agents is increased. This is a process in which the effect of antibiotics (or other antimicrobial agents) eliminates sensitive bacteria, whereas resistant strains survive and proliferate. The result is an increased proportion of resistant bacteria in the population. At the same time it is known that the more often bacteria are exposed to antibiotics, the more opportunities they have for mutations or adoption of resistant genes (e.g. via plasmids from other bacteria) [13].

In ophthalmology this hypothesis has been confirmed e.g. thanks to randomized, controlled longitudinal trials conducted on patients after intravitreal injections, in which moxifloxacin or azithromycin were applied. After one year of treatment, statistically significantly increase resistance to the antibiotic applied to the patients was demonstrated [14].

Another negative consequence of repeated use of antibiotics is the disruption of the natural microflora of the ocular structures, which may contribute to an overproliferation of pathogenic strains that would otherwise be suppressed in their growth by natural selective pressure, and there is also a more frequent appearance of biofilms (e.g. in blepharitis), which are bacteria naturally more resistant to antibiotics [15].

Antibiotic resistance is generally considered by international institutions and specialists to be one of the most significant threats to human health worldwide. It is realistic to expect that the population will once again be endangered by formerly 'banal' infections. The authors highlight the need for international cooperation aimed at reducing the incidence of resistance by means of carefully considered and justified prescribing of antibiotics (antibiotic stewardship) [16].

The same study published in *The Lancet* states that in 2019 over 1.27 cases of death directly caused by antibiotic-resistant bacteria were recorded. These numbers, in combination with almost 5 million further deaths in which resistance played a key role, indicate that this constitutes a genuine threat and not merely a theoretical problem of the future. The authors of the study unequivocally warn that without a radical reduction of the consumption of antibiotics (especially in areas where their benefit is not sufficiently demonstrated), antimicrobial resistance will become the chief cause of death by the middle of the present century [16].

In ophthalmology, the publication of the extensive ESCRS (European Society of Cataract and Refractive Surgeons) study in 2007, which demonstrated that intracameral application of cefuroxime significantly reduces the risk of occurrence of endophthalmitis is considered to represent a significant watershed relating to the administration of antibiotics after cataract surgery. Intracameral application of antibiotics as a prophylaxis for the

occurrence of infectious complications and in particular infectious endophthalmitis is more beneficial from several perspectives than the application of antibiotics in the form of drops [17].

A total of 16 603 patients were included in the study. This was a randomized, multicentric trial, which concluded that an absence of intracameral application of antibiotics (cefuroxime) at the end of cataract surgery was associated with a 4.92x higher risk of infectious endophthalmitis (95% reliability interval, 1.87–12.9). The use of a clear corneal incision (by contrast with a scleral tunnel) was linked with a 5.88x higher risk (95% CI, 1.34–25.9) and complicated cataract surgery was linked with a 4.95x higher risk (95% CI, 1.47–6.67).

Further studies followed, which examined whether there was a statistically significant difference between the application of intracameral antibiotics at the end of cataract surgery alone in comparison with a group in which antibiotics were also applied in drops after the operation, but no difference was demonstrated between the groups. Only the publications we previously mentioned here have extremely strong predicative value, with a sample that in total far exceeds one million operations [6,18–21]. Some of the studies are presented in Table 1.

An article published in *Acta Ophthalmologica* in 2015 assessed the quality of studies with the aid of the "Cochrane risk of bias tool", as well as with the aid of the GRADE system for evaluating quality of evidence and strength of recommendations. The authors state that evidence of a high to medium quality exists concerning a pronounced reduction of the risk of endophthalmitis upon the use of intracameral application of the antibiotics cefazolin, cefuroxime and moxifloxacin, whereas no effect was determined in the case of the use of topical antibiotics or intracameral vancomycin. In the group with intracameral application of antibiotics, endophthalmitis appeared in one out of 2 855 cataract operations, whereas in the group in which no intracameral antibiotics were applied endophthalmitis occurred in one out of 485 cases. No evidence was found to indicate that topical antibiotic prophylaxis leads to the prevention of endophthalmitis [20].

Another example of a study supporting the above-mentioned conclusions is the aforementioned study by the authors from the Kaiser Permanente center in California published in 2016. This study evaluated 315 246 cataract operations conducted on 204 515 patients in the period of 2005–2012. Endophthalmitis appeared in 215 eyes (0.07% or 0.7/1000). Rupture of the posterior capsule was associated with a 3.68 times higher incidence of endophthalmitis (CI, 1.89–7.20). Intracameral application of antibiotics was more effective in preventing endophthalmitis than postoperative local application of antibiotics alone. A combination of intracameral application and postoperative local application was not more effective than intracameral application alone [19].

A prospective non-randomized intervention trial from 2020 conducted in 15 operating centers in India compared the use of intracameral antibiotics (cefuroxime and moxi-

Table 1. Overview of studies comparing the use of antibiotics in cataract surgery

Study Name	Type of Study	Sample size	Aim	Used ATB	Primary outcome
ESCRS Endophthalmitis Study (2007)	Multicenter RCT	~16,000 eyes	Evaluate the prophylactic effect of intracameral antibiotics on endophthalmitis	Cefuroxime (intracameral)	Intracameral cefuroxime significantly reduced the risk of endophthalmitis
Rathi et al. (2020)	Prospective non-randomized intervention	42,466 eyes	Assess whether adding postoperative topical antibiotics reduces the risk of endophthalmitis	Cefuroxime or moxifloxacin (IC) ± topical antibiotics	No significant difference found (0.028% vs. 0.00% in controls)
Passaro et al. (2025)	Systematic review and meta-analysis	1,235,051 eyes	Evaluate the effectiveness of adding postoperative topical antibiotics to intracameral antibiotics	Various intracameral antibiotics (mainly cefuroxime) ± topical antibiotics	No benefit from additional topical antibiotics (P = 0.24)
Herrinton et al. (2016)	Retrospective cohort study	315,246 operations	Compare intracameral antibiotics vs. topical vs. combined antibiotics in preventing endophthalmitis	Intracameral cefuroxime (most common) ± topical antibiotics	Intracameral antibiotics significantly reduced risk; combined approach more effective
Kessel et al. (2015)	Systematic review and meta-analysis	1 RCT + 17 observational studies	Evaluate methods of antibiotic prophylaxis in cataract surgery	Various intracameral antibiotics (mainly cefuroxime), topical antibiotics	Intracameral antibiotics effective; topical antibiotics alone ineffective
Cochrane Review (2017)	Systematic review	More kinds of studies (RCT +	Evaluate antibiotics used in perioperative care (combination of IC and topical)	Various IC ATB + topical ATB	High evidence: IC lowers the risk; medium evidence: IC + topical *might* further lower the risk

ESCRS – European Society of Cataract and Refractive Surgeons, RCT – randomised controlled clinical trial, IC – intracameral, ATB – antibiotics, OR – odds ratio, CI – confidence interval

floxacin) with intracameral antibiotics in combination with postoperative antibiotics in drops (phacoemulsification or cataract surgery by small incision). Operations on a total of 42 466 eyes of 40 006 patients were evaluated. Acute endophthalmitis appeared in 0.035% eyes in the group with topical antibiotics and in 0.028% of eyes without topical antibiotics. The difference in the incidence of endophthalmitis between the two groups was not statistically significant. This trial, in accordance with other studies, therefore does not demonstrate that the supplementing of intracameral application of antibiotics with postoperative application in drops reduces the risk of endophthalmitis [18].

In 2024 we operated on over 160 000 eyes for cataract in the Czech Republic. If we currently prescribe ATB in droplet form routinely for cataract surgery, this means that in total over 160 000 packages of antibiotic drops were manufactured and applied. Taking into account the data from evidence based medicine, it is appropriate to ask whether these topical antibiotics (upon the use of intracameral ATB) genuinely reduced the incidence of inflammatory complications or merely increased antibiotic resistance within the population, represented a financial burden on the healthcare system, reduced patient cooperation and irritated the eyes as a consequence of the content of preservative

agents in the antibiotic preparations. This naturally applies to the average patient, and not in the case of clearly defined risk conditions as described above (eyes with blepharitis, in perioperative complications, in immune suppressed patients etc.).

With regard to the volume of publications on this subject, results indicating the opposite also naturally appear. One of the few studies to present evidence of the better effect of a combination of intracameral application of antibiotics in combination with local application is a study included in Cochrane's summary article from 2017. This study is not in direct contradiction with the assertion that antibiotics applied intracamerally are sufficient in uncomplicated cataract surgery, and that postoperative application of antibiotics in drops does not bring a lower risk of endophthalmitis in these cases. This undoubtedly depends also on the particular cohort of patients, and whether more risk cases were included in the cohort (chronic blepharitis, immune compromised patient, rupture of posterior capsule and others), in which the risk of endophthalmitis is generally higher, in which case local postoperative application of antibiotics may be appropriate. This nevertheless concerns an isolated study in terms of its conclusion, and the quality of the study is evaluated as medium by Cochrane [21].

CONCLUSION

In accordance with the current international recommendations and practices of a range of foreign centers that have discontinued routine topical antibiotic prophylaxis, at the Department of Ophthalmology of the Královské Vinohrady University Hospital we have reevaluated our procedures for patients without risk factors. Based on an analysis of the available data and long-term experience, we have decided to omit this prophylaxis entirely. Intracameral application of cefuroxime (LP Aproxam) continues to be performed routinely and with maximum thoroughness. This approach is ultimately also in accordance with today's common practice in intravitreal applications of anti-VEGF preparations, in which topical antibiotics have also not been applied now for several years. We expect that this approach will lead to a reduction of the risk of development of antibiotic resistance, and may provide an impulse for the introduction of an analogous approach also at other

centers. At the same time we expect that in combination with non-steroidal anti-inflammatory drugs with a low frequency of application (1–2x per day) or with anti-inflammatory application or corticosteroids (3x per day), this approach will contribute to improved comfort for patients and a safer postoperative course of treatment.

Thanks

We would like to express our heartfelt thanks to Professor Studený, head physician Dr. Němec, and head of department Dr. Bartoš for their professional guidance and cooperation on this article. We are confident that the participation of the President of the Czech Society of Refractive and Cataract Surgery, the President of the Czech Vitreoretinal Society and the Head of the Department of Infectious Diseases at the 3rd Faculty of Medicine of Charles University and University Hospital Bulovka will leave operating surgeons in no doubt, and that they will consider proceeding without the use of topical ATB. By doing so we have the opportunity to save as many as 160 000 packages of ATB per year.

REFERENCES

1. Eurostat. Cataract surgeries down 4% in 2021. Eurostat News. 2023 Sep 12. Available from: <https://ec.europa.eu/eurostat/web/products-eurostat-news/w/ddn-20230912-1>
2. Vogel K, Rojas CN, Greenberg PB, Margo CE, French DD. Impact of the COVID-19 Pandemic on Cataract Surgeries in the United States. *Clin Ophthalmol*. 2022 May 25;16:1601-1603. doi: 10.2147/OPTH.S367608
3. data SAPOCH–personal communication
4. Taban M, Behrens A, Newcomb RL, et al. Acute endophthalmitis following cataract surgery: a systematic review of the literature. *Arch Ophthalmol*. 2005 May;123(5):613-620. doi: 10.1001/archophth.123.5.613
5. Hage A. Changes in rates of endophthalmitis after cataract surgery over the last 23 years. *J Fr Ophthalmol*. 2025 Feb;48(2):104385.
6. Passaro ML, Posarelli M, Avolio FC, et al. Evaluating the efficacy of postoperative topical antibiotics in cataract surgery: A systematic review and meta-analysis. *Acta Ophthalmol*. 2025 Feb 28; Epub ahead of print. doi: 10.1111/aos.17469
7. Hatch WV, Cernat G, Wong D, Devenyi R, Bell CM. Risk factors for acute endophthalmitis after cataract surgery: a population-based study. *Ophthalmology*. 2009;116(3):425-430. doi: 10.1016/j.ophtha.2008.09.039
8. Doft BH, Wisniewski SR, Kelsey SF, Fitzgerald SG; Endophthalmitis Vitrectomy Study Group. Diabetes and postoperative endophthalmitis in the endophthalmitis vitrectomy study. *Arch Ophthalmol*. 2001;119(5):650-656. doi:10.1001/archophth.119.5.650
9. Colleaux KM, Hamilton WK. Effect of prophylactic antibiotics and incision type on the incidence of endophthalmitis after cataract surgery. *Can J Ophthalmol*. 2000 Dec;35(7):373-378. doi: 10.1016/s0008-4182(00)80124-6
10. Musumeci R, Troiano P, Martinelli M, et al. Effectiveness of 0.66% Povidone-Iodine Eye Drops on Ocular Surface Flora before Cataract Surgery: A Nationwide Microbiological Study. *J Clin Med*. 2021 May 19;10(10):2198. doi: 10.3390/jcm10102198
11. Hariprasad SM, Blinder KJ, Shah GK, et al. Penetration pharmacokinetics of topically administered 0.5% moxifloxacin ophthalmic solution in human aqueous and vitreous. *Arch Ophthalmol*. 2005;123(1):39-44. doi:10.1001/archophth.123.1.39
12. Kowalski RP, Karenchak LM, Romanowski EG. Infectious disease: changing antibiotic susceptibility. *Ophthalmol Clin North Am*. 2003 Mar;16(1):1-9. doi: 10.1016/s0896-1549(02)00061-5
13. Baquero F, Martínez JL, F Lanza V, et al. Evolutionary Pathways and Trajectories in Antibiotic Resistance. *Clin Microbiol Rev*. 2021 Dec 15;34(4):e0005019. doi: 10.1128/CMR.00050-19
14. Kim SJ, Toma HS. Ophthalmic antibiotics and antimicrobial resistance a randomized, controlled study of patients undergoing intravitreal injections. *Ophthalmology*. 2011 Jul;118(7):1358-1363. doi: 10.1016/j.ophtha.2010.12.014
15. Chiang MC, Chern E. Ocular surface microbiota: Ophthalmic infectious disease and probiotics. *Front Microbiol*. 2022 Aug 19;13:952473. doi: 10.3389/fmicb.2022.952473
16. Antimicrobial Resistance Collaborators. Global burden of bacterial antimicrobial resistance in 2019: a systematic analysis. *Lancet*. 2022 Feb 12;399(10325):629-655. doi: 10.1016/S0140-6736(21)02724-0 Epub 2022 Jan 19. Erratum in: *Lancet*. 2022 Oct 1;400(10358):1102. doi: 10.1016/S0140-6736(21)02653-2
17. Endophthalmitis Study Group, European Society of Cataract & Refractive Surgeons. Prophylaxis of postoperative endophthalmitis following cataract surgery: results of the ESCRS multicenter study and identification of risk factors. *J Cataract Refract Surg*. 2007;33(6):978-988. doi: 10.1016/j.jcrs.2007.02.032
18. Rathi VM, Sharma S, Das T, Khanna RC. Endophthalmitis Prophylaxis Study, Report 2: Intracameral antibiotic prophylaxis with or without postoperative topical antibiotic in cataract surgery. *Indian J Ophthalmol*. 2020 Nov;68(11):2451-2455. doi: 10.4103/ijjo.IJO_1738_19
19. Herrinton LJ, Shorstein NH, Paschal JF, et al. Comparative Effectiveness of Antibiotic Prophylaxis in Cataract Surgery. *Ophthalmology*. 2016 Feb;123(2):287-294. doi: 10.1016/j.ophtha.2015.08.039
20. Kessel L, Flesner P, Andresen J, Erngaard D, Tendal B, Hjortdal J. Antibiotic prevention of postcataract endophthalmitis: a systematic review and meta-analysis. *Acta Ophthalmol*. 2015 Jun;93(4):303-317. doi: 10.1111/aos.12684
21. Gower EW, Lindsley K, Tulenko SE, Nanji AA, Leyngold I, McDonnell PJ. Perioperative antibiotics for prevention of acute endophthalmitis after cataract surgery. *Cochrane Database Syst Rev*. 2017;2:CD006364. doi: 10.1002/14651858.CD006364.pub3