

# Progressive Keratoconus as a Complication of Atopic Keratoconjunctivitis: A Case Report

Cyžová Zuzana<sup>1,2</sup>, Malušková Miroslava<sup>1,2</sup>, Mlčák Petr<sup>1,2</sup>,  
Hübnerová Petra<sup>1,2</sup>, Karhanová Marta<sup>1,2</sup>

<sup>1</sup>University Hospital Olomouc, Department of Ophthalmology, Czech Republic

<sup>2</sup>Palacky University Olomouc, Department of Ophthalmology, Czech Republic



MUDr. Zuzana Cyžová

Submitted to the editorial board: November 16, 2025

Accepted for publication: January 10, 2026

Available on-line: February 18, 2026

*The authors of the study declare that no conflict of interests exists in the compilation, subject and subsequent publication of this professional communication, and that it is not supported by any pharmaceuticals company. This study has not been submitted to any other journal or printed elsewhere, with the exception of congress abstracts.*

Correspondence address:

Oční klinika LF UP a FN Olomouc

Zdravotníků 248/7

77900 Olomouc

Czech Republic

E-mail: zuzana.cyzova@fnol.cz

## SUMMARY

**Purpose:** Presentation of a case report demonstrating the complexity of care for a patient with atopic keratoconjunctivitis (AKC), including the management of complications such as corneal ulceration, development of keratoconus, corticosteroid-induced intraocular pressure elevation, and cataract formation.

**Material and Methods:** We describe a case of a 52-year-old male with a marginal corneal ulcer within the context of atopic blepharokeratoconjunctivitis, focusing on complications and the need for intensive local and systemic therapy to stabilize the disease.

**Results:** Intensive therapy led to a gradual improvement of the disease. Corneal cross-linking stabilized keratoconus, intraocular pressure elevation was successfully managed with anti-glaucoma medication, and cataract surgery resulted in a significant improvement of visual function.

**Conclusion:** This case report highlights the importance of early diagnosis and the need for long-term, multidisciplinary care in patients with AKC. Regular follow-up examinations, patient education, and a combination of local, systemic, and surgical therapy are essential in order to prevent complications and stabilize the disease.

**Key words:** atopic keratoconjunctivitis, atopic dermatitis, keratoconus, corneal ulcer, corneal cross-linking

*Čes. a slov. Oftal., 82, 2026, No. x, p.*

## INTRODUCTION

Atopic keratoconjunctivitis (AKC) is a chronic allergic disease affecting the eyelids, cornea and conjunctiva, and is considered to be an ocular manifestation of atopic dermatitis (AD). AD is simultaneously present in approximately 95% of patients with AKC, although almost 50% of these patients show negative results in tests for regular allergens. Unless AKC is treated in a timely manner it may lead to severe loss of sight or to blindness.

AKC is usually diagnosed in the second to third decade of life, but may also be diagnosed in early childhood or by contrast as late as the fifth decade of life. As a rule the pathology is manifested year-round, but seasonal exacerbations may occur. The clinical picture is generally bilateral, although unilateral forms have also been described. Symptoms of AKC include itching, lacrimation, and burning sensation in the eyes. Patients typically experience chronic rather than seasonal manifestations, which include pain, reddening of the eyes, and blurred vision [1,2].

A typical finding is severe atopic dermatitis affecting the

eyelids and the periorbital region, anterior and posterior blepharitis, conjunctival hyperemia, papillary hypertrophy and subconjunctival fibrosis [1], shallowing of the inferior fornix, limbal Horner-Trantas dots, superficial punctate epitheliopathy, ulceration, formation of mucoid plaques and filaments, scarring, and corneal neovascularization [2]. Complications of AKC include in particular anterior subcapsular cataract, although posterior subcapsular cataract may also develop as a consequence of the use of corticoids either generally or locally. Patients with AKC and AD have heightened susceptibility to microbial colonization and infection of the skin and ocular surface, most often upon a background of *Staphylococcus aureus*. Patients are also susceptible to recurrent infections with the herpes simplex virus, which may also be bilateral. Other complications include disorder of the lacrimal film and corticoid-induced secondary glaucoma [2].

Keratoconus (KC), a disease characterized by progressive thinning of the cornea, may also occur in patients with AKC. Chronic eye rubbing as a reaction to irritation plays a significant role in the onset and progression of KC [2,4]. In patients with AKC the frequency and length of rubbing eyes is de-

monstrably higher in comparison with the rest of the population. Intensive and long-term eye rubbing may lead to thinning of the cornea and loss of its rigidity as a consequence of mechanical friction. In addition to mechanical damage, eye rubbing can also initiate inflammatory processes, which contribute to the pathogenesis of KC [8]. For these reasons it is essential to educate patients with AKC thoroughly concerning the risks associated with eye rubbing, since this habit contributes significantly to the development and progression of KC. Regular check-ups are of key importance for timely detection of KC and for optimizing the long-term results.

The aim of the presented case report is to illustrate the need for a comprehensive approach to this disease and to highlight the challenges in the long-term care of these patients, including addressing complications such as corneal ulceration, the development of keratoconus, the development of corticoid-induced elevation of intraocular pressure, and the onset of posterior subcapsular cataract.

## DESCRIPTION OF CASE

We present the case of a 52-year-old man who was referred to our center due to a marginal corneal ulcer with an intensifying defect of the left eye. The patient was treated with 0.1% fluorometholone drops 3x per day, 0.3% ofloxacin cream 4x per day, and ointment containing vitamin A applied 4x per day to both eyes for a period of 14 days. The patient had a medical history of atopic dermatitis, and at the time of our examination was not using general corticoids or receiving any biological treatment.

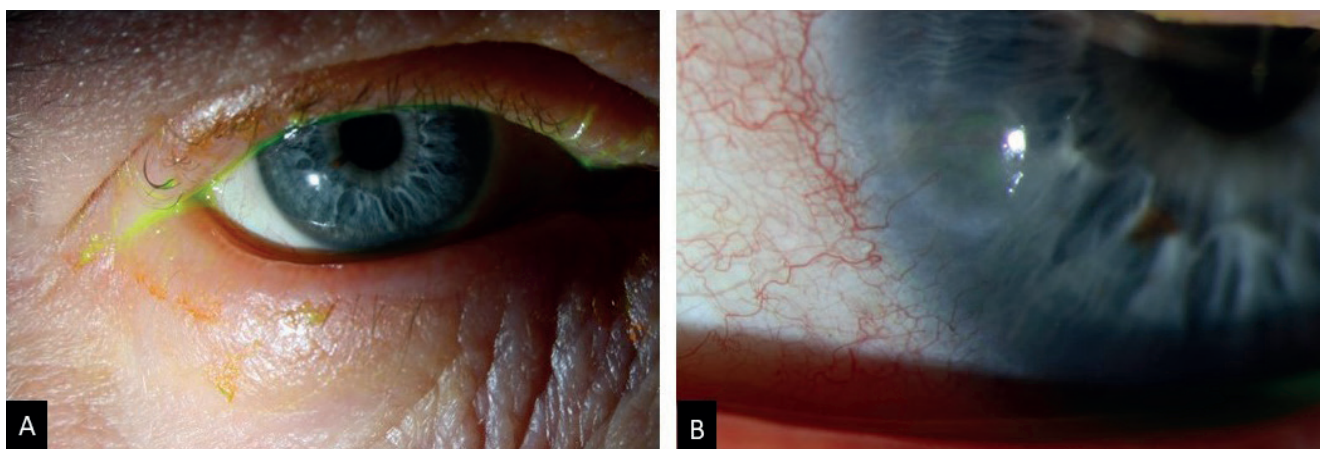
At the baseline examination we diagnosed atopic blepharokeratoconjunctivitis in both eyes, with flaking of the skin and thickening of the edges of the eyelids, madarosis, semi-obturation of the meibomian glands, mucous secretion, papillary reaction of the tarsal conjunctiva, and mixed injection of the bulbar conjunctiva in both eyes. An already re-epithelialized corneal marginal minus defect was present in the inferior nasal quadrant, together with superficial neovascularization encroaching into the area of the original corneal ulcer (Figure 1). Visual acuity was 0.40

in the right eye and 0.63 in the left eye, intraocular pressure was 15.6 mmHg and 17.7 mmHg respectively.

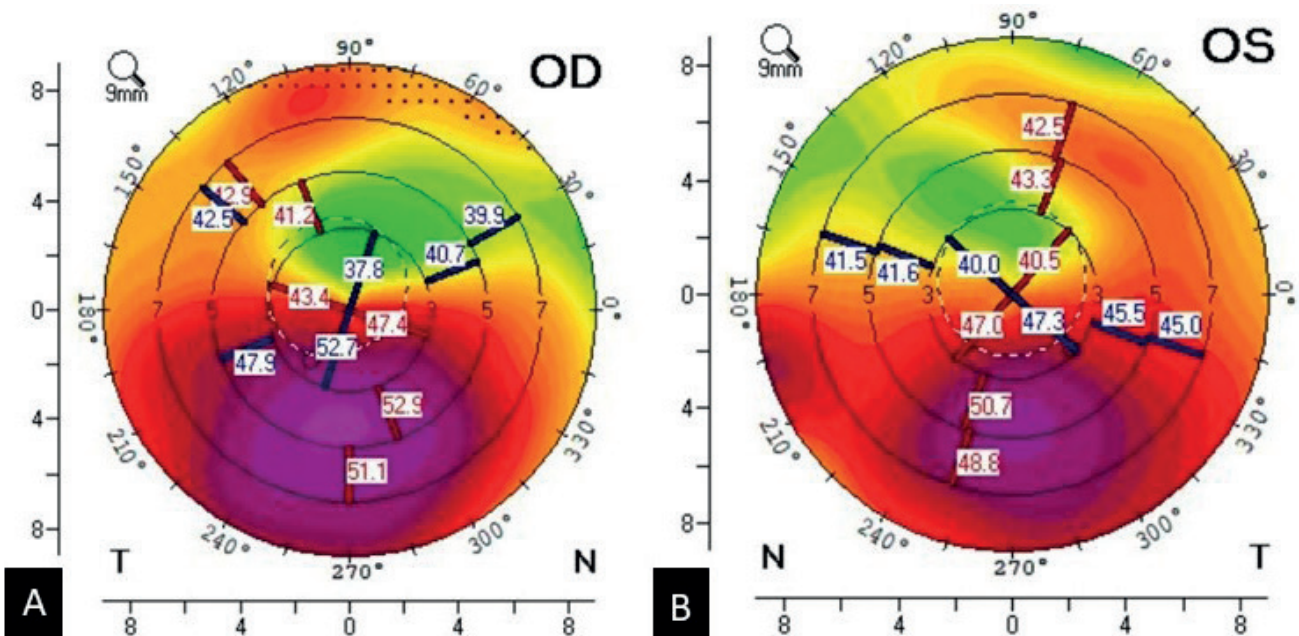
We commenced intensive local therapy in the form of 0.5% hydrocortisone ointment 3x per day to the eyelids in combination with daily hygiene of the eyelids, 0.1% olopatadine drops applied 2x per day, 0.1% dexamethasone drops 3x per day, artificial tears with 2.0% ectoine every 2 hours, and 0.5% hydrocortisone cream 1x per day applied into both eyes at night before sleeping. In addition we prescribed 0.3% ofloxacin drops to be applied locally to the left eye 3x per day for a period of one week. The antihistamine fexofenadine was prescribed to be administered generally in a dose of 120 mg 1x per day. The patient was educated with regard to the need to refrain from mechanical eye rubbing and was referred for a dermatological examination.

The patient attended regular follow-up examinations at monthly intervals, and with the progressive improvement of the clinical finding we reduced the prescribed local therapy. At the same time, according to the recommendations of the dermatologist, the patient began to apply 0.1% tacrolimus ointment to both eyelids 1x per day. Following stabilization of the finding we performed a tomographic examination (Pentacam®, OCULUS Optikgeräte GmbH, Wetzlar, Germany), which demonstrated keratoconus in both eyes, in the right eye 2nd–3rd degree and in the left eye 2nd degree according to the Belin/Ambrosio score (Figure 2). Objective refraction was -4.00 D -6.00 D × 18° in the right eye and +1.00 D -1.75 D × 90° in the left eye.

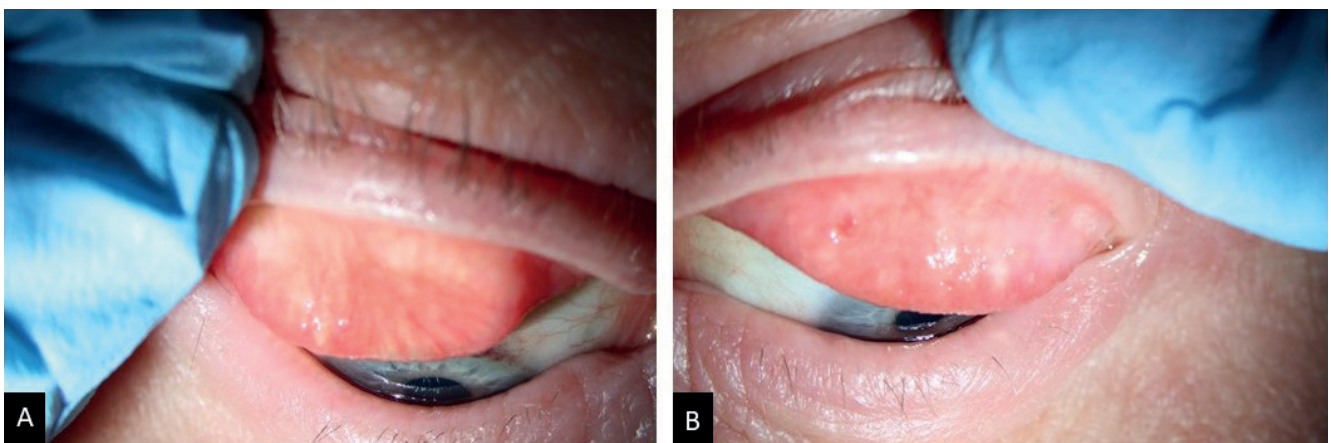
At subsequent follow-up examinations we recorded an elevation of intraocular pressure in both eyes, intraocular pressure in the right eye was 22.7 mmHg by noncontact and 24.0 mmHg by applanation, and intraocular pressure in the left eye was 25.3 mmHg by noncontact and 25.0 mmHg by applanation. To the set local therapy we added 0.5% timolol drops 2x per day, while standard automated perimetry (G Standard White/White/Dynamic; Octopus 900, Haag-Streit AG, Switzerland; EyeSuite™ Static, V3.1.1) did not demonstrate any significant scotomas in the visual field. Examination with the aid of optical coherence tomography (Spectralis® OCT, Heidelberg Engineering GmbH, Germany) showed



**Figure 1.** Bilateral blepharokeratoconjunctivitis. (A) Thickening of the eyelids, madarosis, and conjunctival injection in the right eye. (B) A detailed view of a marginal stromal minus defect with vascularization in the left eye



**Figure 2.** Corneal topography, frontal sagittal curvature. (A) Keratoconus grade 2-3 in the right eye, maximum keratometry (Kmax) 54,3 D. (B) Keratoconus grade 2 in the left eye, Kmax 51,9 D



**Figure 3.** (A) Upper tarsal conjunctiva of the right eye. (B) Subepithelial fibrosis in the upper tarsal conjunctiva of the left eye

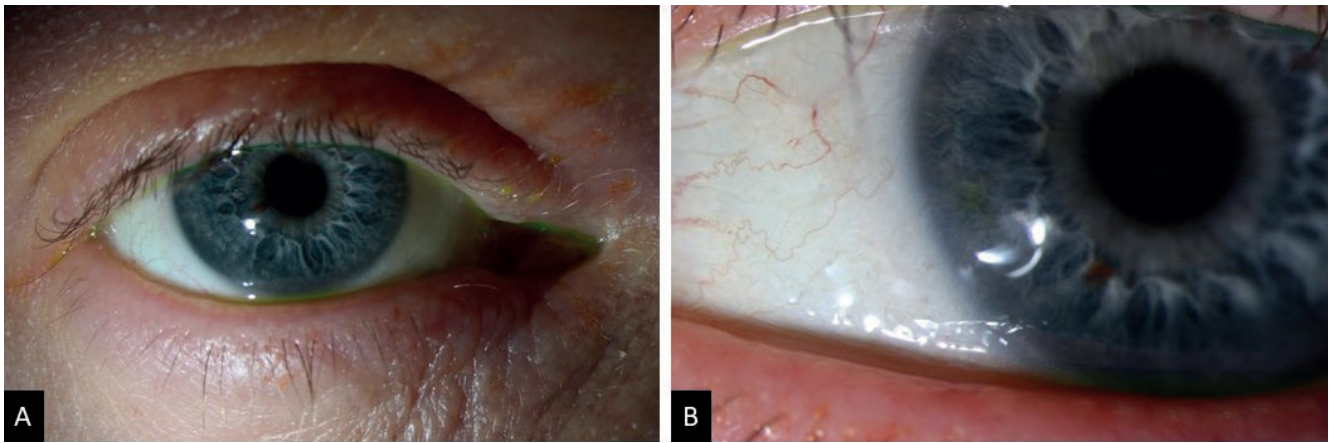
normal thickness of the retinal nerve fiber layer and did not demonstrate any signs of glaucomatous damage. For this reason corticoid-induced elevation of intraocular pressure was considered, which was normalized following the application of local anti-glaucoma medication. Glaucoma was not demonstrated at any of the subsequent follow-up examinations.

With regard to identifying keratoconus, control optical coherence tomography was performed at an interval of 4 months, in which no progression of the disease was demonstrated, nevertheless after a further interval of 5 months progression of keratoconus was detected in both eyes. Pachymetry at the thinnest point was 437  $\mu\text{m}$  in the right eye and 458  $\mu\text{m}$  in the left eye. The patient was indicated for transepithelial corneal cross-linking, we planned the procedure in both eyes with an interval of one week in between. After the procedure stabilization of keratoconus was achieved bilaterally.

During the course of subsequent follow-up examinations, the patient stated subjective worsening of the complaints,

with increased irritation in the left eye and an OSDI score of 25. On the superior tarsus of the left eye we detected subepithelial fibrosis, in addition there was manifest progression of papillary hypertrophy of the tarsal conjunctiva together with punctate epitheliopathies of the cornea in both eyes (Figure 3). A Schirmer test without the use of anesthetic was 7mm/5 min in both eyes. We increased the dosage of topical corticoids, which were subsequently progressively reduced, and added local immunomodulation therapy in the form of 0.1% cyclosporine drops 1x per day in the evening as a corticosteroid-sparing treatment.

After an interval of 1.5 years from our baseline examination, the patient noticed deteriorated vision in both eyes, which was not improved by correction of vision. Visual acuity was 0.25 in the right eye and 0.4 weakly native in the left eye, and upon examination dense subcapsular posterior cataract was present bilaterally. We planned cataract surgery targeted at emmetropia, after which there was a pronoun-

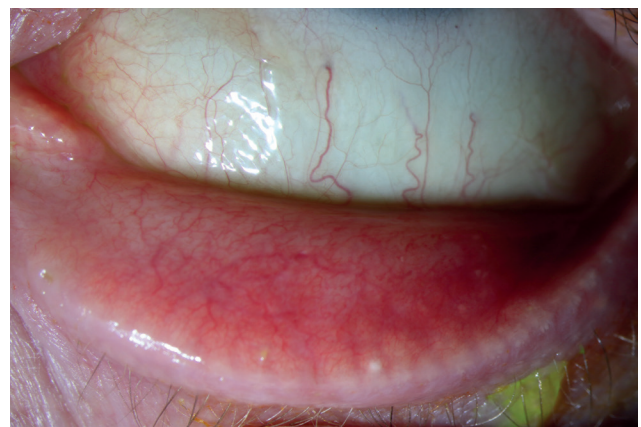


**Figure 4.** (A) Significantly reduced eyelid inflammation, reduced madarosis, and only mild conjunctival hyperaemia. (B) A small subepithelial scar in the inferonasal quadrant of the cornea of the left eye at the site of the original marginal corneal ulcer

ced subjective improvement of visual acuity, vision was 0.5 in the right eye and 0.8 in the left eye. The clinical condition was also now stabilized, with a regression of flaky skin in the region around the eye, madarosis was no longer present, mucous secretion receded, only a mild papillary reaction of the tarsal conjunctiva was present, and a small deposit of subepithelial fibrosis had developed in the location of the original marginal ulcer in the inferior nasal quadrant of the left eye. Irritation of the eyes had subsided and keratoconus was stable, although semi-obturation of the meibomian glands and thickening of the edges of the eyelids persisted (Figures 4 and 5). We continued with local application of 0.1% tacrolimus ointment to both eyelids every other day together with an ointment containing vitamin A daily, the patient applied 0.5% timolol drops to both eyes 2x per day, 0.1% olopatadine drops 2x per day, 0.1% dexamethasone drops 1x per week, 0.1% cyclosporine A drops 1x per day in the evening, artificial tears with 2.0% ectoine every two hours, and ointment with vitamin A at night before sleeping. Regular hygiene of both eyelids together with expression of the content of the meibomian glands was also a matter of course. The patient was referred for a dermatological examination for consideration of commencing biological treatment.

## DISCUSSION

The case report highlights the essential need for a comprehensive approach in care for patients with atopic blepharoconjunctivitis. The initial finding of a marginal ulcer in the left eye points to the severity of affliction of the ocular surface, which in patients with AKC is closely linked with immune-mediated inflammation. A key role in its pathogenesis is played by eosinophiles, which are the main inflammatory cells in the late phase of the reaction mediated by immunoglobulin E. They release eosinophile cationic protein and eosinophile peroxidase, which are associated with the development of corneal ulceration. Furthermore, the density of eosinophiles on the ocular surface correlates with the colonization of *Staphylococcus aureus* in allergic pathologies of the ocular surface. In addition to eosinophi-



**Figure 5.** Only mild papillary hypertrophy was present

les, neutrophils also contribute to inflammation, which together with eosinophiles produce powerful oxidative substances, e.g. superoxides and hydrogen peroxide (H<sub>2</sub>O<sub>2</sub>), in an attempt to destroy *Staphylococcus aureus*, which may penetrate through the damaged skin or mucosa with a weakened barrier function. This activation of eosinophiles may contribute to sustaining the allergic inflammation on the cornea [10].

Intensive and long-term eye rubbing in patients with AKC may lead not only to the onset of KC, but may also contribute to damaging the ocular surface and thereby increasing the risk of onset of corneal ulceration. Although local corticoids and immunomodulating drops are effective in the treatment of AKC, at the same time they increase the risk of onset of infectious keratitis [9].

In our presented case, KC developed in both the patient's eyes. The first clinical manifestation of the disease is deterioration of distance vision as a consequence of increasing short-sightedness and irregular astigmatism. In the early stages glasses may be sufficient for correction, though the majority of patients require correction with contact lenses to achieve an improvement of visual acuity. In the early phase of keratoconus soft contact lenses designated specially for keratoconus may suffice, whereas in

more advanced stages of keratoconus hard corneal or scleral contact lenses are used. Other types of contact lenses used for correction of keratoconus are “piggyback” lenses and hybrid contact lenses, which combine the advantages of hard lenses with the comfort of soft lenses. If the patient respects the recommended regimen, wearing contact lenses may provide satisfactory visual functions for several years. A modern method of treatment which should prevent the progression of the disease is Corneal Collagen Crosslinking (CXL) [11]. CXL is a type of photodynamic therapy in which new chemical bonds are formed between collagen fibers of the anterior corneal stroma, which enable strengthening of the cornea and restoration of its biochemical and biomechanical stability. To date the standard method (Dresden Protocol) is generally recognized with regard to the number of published studies demonstrating its efficacy and safety even in long-term observation. An alternative to the standard method is accelerated CXL. This technique has a low incidence of complications and adverse side effects, and improves the time comfort of the patient during the course of the procedure. Today the ultimate surgical solution in the case of intractable astigmatism is above all deep anterior lamellar keratoplasty [11].

Corticoid-induced elevation of intraocular pressure is a common complication upon the long-term application of corticoids or their use [7]. In our case this was successfully managed with the aid of eye drops containing 0.5% timolol, which averted glaucomatous structural damage. However, long-term corticoid therapy may have contributed to the development of posterior subcapsular cataract, which required a surgical solution, in which an improvement of the patient’s visual functions was achieved postoperatively.

The aim of treatment of AKC is to alleviate symptoms, reduce the frequency of exacerbations and sustain remission. General measures include avoiding allergens, and treatment of associated dermatological findings such as atopic dermatitis and periorbital eczema. Treatment of eczema of the eyelids should be applied in a timely manner, sufficiently effective and safe over the long term. Eczema of the eyelids is often insufficiently treated due to concerns regarding the adverse effects of corticoids. The optimal solution is a sequential strategy with initial short-term application of non-halogenated corticoids and subsequent maintenance treatment with local immunomodulators, especially tacrolimus or pimecrolimus. It is also of crucial importance to ensure thorough care of the skin barrier with the aid of non-irritating emollients and patient education [12]. Application of cooling packs and regular eyelid hygiene may be beneficial especially in the case of blepharitis caused by staphylococci. Artificial tears not containing preservative agents may stabilize the lacrimal film and at the same time dilute the concentration of allergens in tears. If drops are applied cooled, they are more effective in alleviating itching of the eyes [5].

A general sequential algorithm of treatment exists which incorporates the use of local and systemic therapy – mast cell stabilizers, antihistamines, and corticoids. Recently corticosteroid-sparing drugs have been increasingly applied, such as calcineurin inhibitors and immu-

nomodulators [5]. It has been demonstrated that immunomodulators effectively suppress clinical symptoms, including blepharitis, conjunctival hyperemia, edema, papillary reactions, and damage to the cornea in severe forms of ocular allergy [6]. In this case we included all the above-mentioned therapeutic options in comprehensive treatment, thanks to which we succeeded in achieving stabilization and improvement of the condition.

Studies also show that systemic immunosuppressive therapy with the aid of medications modifying the disease, such as methotrexate, mycophenolate mofetil and azathioprine, are effective in controlling ocular inflammation.

Also relevant in clinical practice is targeted biological treatment of atopic dermatitis, which may also indirectly influence the course of the ocular affliction [13]. In the Czech Republic biological treatment of medium-severe to severe AD is covered by health insurance upon meeting the defined indication restrictions. Since 2019 the pharmaceutical dupilumab (Dupixent®) has been approved, and since 2024 also lebrikizumab (Ebglyss®). Health insurance coverage has not yet been stipulated for tralokinumab (Adtralza®).

Dupilumab represents the first approved biological therapy for patients with medium-severe to severe AD. It is a fully human monoclonal antibody inhibiting signalization of IL-4 and IL-13. However, in clinical trials a higher incidence of conjunctivitis has been described in the group of patients with AD treated with dupilumab in comparison with a placebo. In addition to conjunctivitis, also blepharitis, keratitis and dry eye syndrome have been documented during treatment with dupilumab [14]. This heterogeneous spectrum of adverse effects has been referred to in the literature as dupilumab-related ocular surface disorders (DROSD) [13]. The precise mechanism of thus associated conjunctivitis has not yet been fully clarified. Risk factors are a medical history of ocular inflammations, raised level of IgE, eosinophilia and elevation of chemokine TARC/CCL17 [14]. Most cases can be managed by local therapy and dupilumab can usually be continued. The multidisciplinary consensus from 2024 emphasizes that in most cases commencing treatment with dupilumab should not be deferred due to ocular complaints, despite the fact that in some cases a preliminary consultation with an ophthalmologist is appropriate, and that it makes sense to consider terminating treatment with dupilumab above all in the case of threat to sight or a significant impact on quality of life [13].

Lebrikizumab is a humanized monoclonal antibody which inhibits signalization of IL-13 and according to the available clinical experiences may be effective both on treatment-naïve patients and on a proportion of patients pre-treated with other biological agents [15].

The current therapeutic options for allergic diseases of the ocular surface have their limitations. Conventional medications such as mast cell stabilizers and antihistamines are less effective in refractive states, whereas corticoids bring the risk of adverse effects such as increase of intraocular pressure, onset of posterior subcapsular cataract, reduced resistance

to pathogens, delayed healing of corneal and scleral wounds, mydriasis, ptosis, retinal embolization, or atrophy of the optic nerve [7]. Current immunomodulators are also associated with the risk of toxic effects. Consequently, in recent years new active agents have been investigated for the treatment of inflammatory diseases of the ocular surface. One of the most clinically documented substances is reproxalap (Aldeyra Therapeutics). This is an immunomodulating inhibitor of reactive aldehydes, which are generally raised upon inflammation of the ocular surface. In phase 3 studies in allergic conjunctivitis reproxalap demonstrated a significant reduction of itching and reddening of the eyes in comparison with a placebo [16]. Other studied substances include modulation of the signal pathways (spleen tyrosine-protein kinase – SYK), influencing inflammatory transcription mechanisms (NF- $\kappa$ B), targeting at adhesive molecules of eosinophiles (integrin  $\alpha$ 4 $\beta$ 1), or receptors (transient receptor potential – TRP). Further studied substances include urocanic acid (UCA) and  $\beta$ -1.3-glucan. However, as yet most of these approaches are still in the

phase of clinical development and are not routinely available for the treatment of AKC [5].

## CONCLUSION

Our patient underwent comprehensive treatment incorporating intensive local and general therapy together with surgical intervention. No progression of keratoconus was detected after the performance of transepithelial corneal CXL, and after cataract surgery there was a significant improvement of visual acuity. Stabilization of the clinical findings and subjective complaints confirms the effectiveness of the chosen therapy, though it is necessary to place the patient under regular observation with reference to the risk of exacerbation of symptoms, since AKC is a chronic disease. This case report emphasizes the importance of timely diagnosis, the necessity of long-term and demanding treatment in which patient cooperation is of crucial significance, as well as the irreplaceable role of interdisciplinary cooperation. The aim of treatment is to stabilize the disease, provide relief from symptoms and prevent complications.

## REFERENCES

1. Azari AA, Arabi A. Conjunctivitis: A Systematic Review. *J Ophthalmic Vis Res.* 2020 Aug 6;15(3):372-395. doi: 10.18502/jovr.v15i3.7456
2. Chen JJ, Applebaum DS, Sun GS, Pflugfelder SC. Atopic keratoconjunctivitis: A review. *J Am Acad Dermatol.* 2014 Mar;70(3):569-575. Epub 2013 Dec 15. doi: 10.1016/j.jaad.2013.10.036
3. Bielory B, Bielory L. Atopic dermatitis and keratoconjunctivitis. *Immunol Allergy Clin North Am.* 2010 Aug;30(3):323-336. doi: 10.1016/j.iac.2010.06.004
4. Gordon-Shaag A, Millodot M, Shneur E. The Epidemiology and Etiology of Keratoconus. *Int J Keratoco Ectatic Corneal Dis.* 2012;1(1):7-15.
5. Hossain IT, Sanghi P, Manzouri B. Pharmacotherapeutic management of atopic keratoconjunctivitis. *Expert Opin Pharmacother.* 2020 Oct;21(14):1761-1769. Epub 2020 Jun 30 doi: 10.1080/14656566.2020
6. Erdinest N, Noyman DBE, London N, et al. Applications of topical immunomodulators enhance clinical signs of vernal keratoconjunctivitis (VKC) and atopic keratoconjunctivitis (AKC): a meta-analysis. *Int Ophthalmol.* 2024 Mar 24;44(1):157. doi: 10.1007/s10792-024-03097-7
7. Gaballa SA, Kompella UB, Elgarhy O, et al. Corticosteroids in ophthalmology: drug delivery innovations, pharmacology, clinical applications, and future perspectives. *Drug Deliv Transl Res.* 2021 Jun;11(3):866-893. doi: 10.1007/s13346-020-00843-z
8. Weng SF, Jan RL, Wang JJ, Tseng SH, Chang YS. Association between atopic keratoconjunctivitis and the risk of keratoconus. *Acta Ophthalmol.* 2021 Feb;99(1):e54-e61. Epub 2020 Jun 22. doi: 10.1111/aos.14509
9. Jan RL, Weng SF, Wang JJ, Tseng SH, Chang YS. Association between atopic keratoconjunctivitis and the risk of corneal ulcer. *Br J Ophthalmol.* 2021 Dec;105(12):1632-1637. Epub 2020 Oct 3. doi: 10.1136/bjophthalmol-2020-316206
10. Fujishima H, Okada N, Dogru M, et al. The role of Staphylococcal enterotoxin in atopic keratoconjunctivitis and corneal ulceration. *Allergy.* 2012 Jun;67(6):799-803. Epub 2012 Apr 10doi: 10.1111/j.1398-9995.2012.02818.x
11. Velická V, Rozsívál P, Jirásková N, Raiskup F. Treatment of keratoconus by accelerated cross-linking. *Cesk Slov Oftalmol.* 2017;73(4):134-139.
12. Benáková N. Ekzémy očních víček a screening očního postižení u atopické dermatitidy. *Česko-slovenská dermatol.* 2023;98(6):288-294.
13. Achten R, Thijs J, van der Wal M, et al. Ocular surface disease in moderate-to-severe atopic dermatitis patients and the effect of biological therapy. *Clin Exp Allergy.* 2024 Apr;54(4):241-252. Epub 2024 Feb 8. doi: 10.1111/cea.14461
14. Gkalpakiotis S, Tánzosová M, Skalická P. Oční komorbidity u atopické dermatitidy a kazuistika pacienta se závažnými očními komplikacemi léčeného dupilumabem. *Remedia.* 2020; 30:361-364.
15. Stingeni L, Ferrucci S, Amerio P, Foti C, Patruno C, Girolomoni G. Lebrikizumab: a new anti-IL-13 agent for treating moderate-to-severe atopic dermatitis. *Expert Opin Biol Ther.* 2025 Jan;25(1):15-20. Epub 2024 Dec 6. doi: 10.1080/14712598.2024.2435427
16. Starr CE, Nichols KK, Lang JR, Brady TC. The Phase 3 INVIGORATE Trial of Reproxalap in Patients with Seasonal Allergic Conjunctivitis. *Clin Ophthalmol.* 2023 Dec 13;17:3867-3875. doi: 10.2147/OPHT.5441009