

Central Retinal Artery Occlusion – Our Future Path to the Introduction of Intravenous Thrombolysis

Sazanovych Daria¹, Schreiberová Zuzana¹, Sapieta Martina¹, Marešová Klára¹, Šaňák Daniel², Polidar Petr², Karhanová Marta¹



Sazanovych Daria

¹Faculty of Medicine and Dentistry, Palacky University Olomouc and University Hospital Olomouc, Department of Ophthalmology, Czech Republic

²Faculty of Medicine and Dentistry, Palacky University Olomouc and University Hospital Olomouc, Department of Neurology, Czech Republic

Submitted to the editorial board: October 29, 2025

Accepted for publication: January 10, 2026

Available on-line: February 25, 2026

The authors of the study declare that no conflict of interests exists in the compilation, subject and subsequent publication of this professional communication, and that it is not supported by any pharmaceuticals company. This study has not been submitted to any other journal or printed elsewhere, with the exception of congress abstracts and recommended procedures.

Correspondence address:

Oční klinika LF UP a FN Olomouc
Zdravotníků 248/7

779 00 Olomouc

Czech Republic

E-mail: daria.sazanovych@fnol.cz

SUMMARY

Introduction: Retinal artery occlusion (RAO) is a vascular occlusive disorder and an acute condition in ophthalmological practice.

Purpose: To evaluate the effectiveness of treatment approaches used at our department in patients with RAO, particularly their impact on the resulting central visual acuity of the affected eye. Furthermore, to determine how many patients would meet the time window for intravenous thrombolysis (IVT) administration in the case of central retinal artery occlusion (CRAO).

Material and Methods: This retrospective study included all the patients diagnosed with CRAO and BRAO (branch retinal artery occlusion) who received systemic treatment with intravenously administered vasodilators (Procaine[®]) at our department between 01/2020 and 08/2025. We monitored the time delay to examination, the type of healthcare facility upon first contact, the type of therapy, the duration of symptoms before the initiation of treatment, and risk factors. We evaluated the change in central visual acuity (CVA) before treatment and immediately after completion of therapy upon discharge from hospital.

Results: The study sample consisted of 73 eyes (51 with CRAO and 22 with BRAO). No significant improvement in CVA was observed after the administration of 0.2% procaine hydrochloride (Procaine[®]): the mean change in CVA before and after treatment was 0.045 in the BRAO group and 0.078 in the CRAO group. No significant association was found between CVA change and the number of administered Procaine doses. The average time from the onset of symptoms to examination at our ophthalmology clinic was 33.5 hours in the BRAO group and 28.4 hours in the CRAO group. The time window for potential IVT administration was met by 2 patients with BRAO (9%) and 14 patients with CRAO (27%).

Conclusion: We did not demonstrate any potential therapeutic effect of intravenously administered 0.2% procaine hydrochloride. Our results confirmed the need to establish a protocol for IVT administration.

Key words: retinal artery occlusion, intravenous thrombolysis, conventional treatment methods, vasodilators, procaine

Čes. a slov. Oftal., 82, 2026, No. x, p.

INTRODUCTION

Retinal artery occlusion (RAO) is a vascular occlusive disorder which leads to severe and irreversible loss of sight as a consequence of insufficient transport of oxygen to the retinal cells. This ranks among acute conditions in ophthalmological practice [1]. According to the degree of affliction, RAO can be divided into central retinal artery occlusion (CRAO) and branch retinal artery occlusion (BRAO) [2]. In essence it is a form of ischemic stroke (IS), which leads to severe loss of sight and is a possible precursor of further cerebrovascular and cardiovascular events that constitute a potential threat to the patient's life and independence [3]. As a result, it is highly important not only to ensure timely diagnosis of this disorder, but also to evaluate the patient's general condition of health in close cooperation with a neu-

rologist and internal medicine specialist or general practitioner. Regular checks by an ophthalmologist are necessary in order to optimize residual vision, ensure timely detection of any potential neovascular complications and to monitor the patient's other eye. The task of the neurologist is to determine the causes of the stroke and to configure a regimen of secondary prevention, while the internal medicine specialist corrects modifiable risk factors (RF) [4].

Despite 150 years of research, no unified medical approach exists to this day [3]. The spectrum of therapeutic options is broad, incorporating both mechanical methods for reducing intraocular pressure (eyeball massage, anterior chamber paracentesis, pars plana vitrectomy) and pharmacological methods with various mechanisms of effect (acetazolamide, methylprednisolone, intravenous thrombolysis) [5]. However, the

results of the above therapeutic procedures remain highly controversial.

As yet no uniform protocol for the management of patients with RAO exists in the Czech Republic. Some medical centers have introduced a procedural diagram into practice regarding the performance of intravenous thrombolysis (IVT), which they administer within a time window of up to 4.5 hours from the occurrence of the event. In this case, care for patients with RAO is ensured by a multidisciplinary team (ophthalmologist and neurologist) [6]. To date some centers use only classic therapeutic procedures in all cases.

The purpose of this study is to evaluate the effectiveness of intravenous administration of procaine, especially its influence on resulting central visual acuity (CVA) of the affected eye in patients with RAO. We also set ourselves the target of determining the time frame within which patients with RAO reported to the general outpatient clinic of the Department of Ophthalmology of the Faculty of Medicine at Palacký University (LF UP) and University Hospital Olomouc (FNOL), i.e. the number of patients who were within the time window for administration of IVT in the case of CRAO, as well as the task of configuring a preliminary procedural diagram for improving the quality of care for patients with RAO at FNOL.

MATERIAL AND METHOD

Characteristics of cohort

We evaluated the data of 73 patients (73 eyes). The number of patients with CRAO was 51, with BRAO 22, the details are presented in Table 1. The age range of the treated patients was 25 to 91 years in the group with BRAO (mean 64.0; median 67.5) and 25 to 92 in the group with CRAO (mean 70.7; median 72.0) (Table 2). The BRAO and CRAO groups did not differ significantly in terms of age or sex.

Design of study

The retrospective study included all patients who had

been hospitalized at the Department of Ophthalmology at LF UP and FNOL within the period from 01/2020 to 08/2025 with a diagnosis of CRAO or BRAO, and who had been provided with general treatment with intravenously administered vasodilator drugs, antithrombotic drugs, and conventional local therapy (eyeball massage, antiglaucoma drugs, anterior chamber paracentesis). A list of patients was obtained from the clinic's database. The patients were hospitalized throughout the entire period of treatment. We monitored age, sex, laterality of affliction, the time delay between the onset of complaints and examination, type of healthcare facility upon first contact, type of therapy, length of complaints before commencement of treatment, and we recorded systemic RF (arterial hypertension, diabetes mellitus, and hyperlipidemia) and data about smoking. After discharge from hospital we recommended that patients undergo an examination by a general practitioner for the purpose of determining the source of embolization (echocardiography, carotid Doppler examination) if these examinations had not already been performed during hospitalization. We evaluated the change of CVA before treatment and after the end of treatment upon discharging patients from hospital. CVA was examined on Snellen charts and recorded in a decimal value. In the case of poor CVA within the range of counting fingers in front of the eye or only movement in front of the eye we used a conversion table (Table 3) [7]. We considered objective or subjective improvement of vision to constitute a beneficial effect.

Administered general and local therapy

At our clinic our standard procedure for treating patients with RAO is to administer an infusion of 0.2% procaine hydrochloride (Procaine®) 500 ml per day for a period of 5 days, unless the patient's internal condition excludes the possibility of such treatment. In the case of a beneficial effect this treatment is prolonged to 9 days. We also administer anticoagulation treatment in a therapeutic dose (low-molecular-weight low-fractionated heparins, e.g. Enoxaparin

Table 1. Characteristics of the group with central (CRAO) and branch (BRAO) arterial occlusion

		BRAO		CRAO		p-value
		count	percent	count	percent	
gender	male	16	72.7%	29	56.9%	0.201
	female	6	27.3%	22	43.1%	
eye	right	14	63.6%	27	52.9%	0.398
	left	8	36.4%	24	47.1%	

Table 2. Age characteristics of the cohort in groups with central retinal (CRAO) and branch (BRAO) arterial occlusion

		group		Mann-Whitney U test p-value
		BRAO	CRAO	
Age	Mean	64.0	70.7	0.122
	Standard deviation	16.6	12.7	
	Median	67.5	72.0	
	Minimum	25	25	
	Maximum	91	92	

Table 3. Conversion of weak central visual acuity to a decimal value

Counting fingers from a distance	Decimal value
4 meters	0.06
3 meters	0.05
2 meters	0.03
1.5 meters	0.02
1 meter	0.016
20 cm counting fingers, 10 cm counting fingers, hand motion	0.001

(Inhixa) s.c. inj.), if the patient is not already using these drugs. Local therapy consisted in the performance of conventional methods: eyeball massage, antiglaucoma drugs locally, and anterior chamber paracentesis.

Data analysis and statistical evaluation

The statistical software IBM SPSS Statistics version 23 (Armonk, NY: IBM Corp.) was used for the data analysis. The groups were compared in the quantitative parameters with the aid of a Mann-Whitney U test. A chi-squared test or Fisher's exact test was used for comparison of the qualitative parameters. The correlation between CVA and the number of doses of procaine was assessed with the aid of a Spearman's rank-order correlation analysis. Normality of data was assessed with the aid of a Shapiro-Wilk test. All the tests were performed on a level of significance of 0.05.

RESULTS

Significantly higher values of CVA before the administration of treatment ($p < 0.0001$) and significantly higher

values of CVA after treatment ($p < 0.0001$) were demonstrated in the BRAO group. The groups did not differ significantly in terms of the change of CVA (Table 4). In our cohort 22 patients (100%) in the BRAO group and only 13 patients (25.5%) in the CRAO group had resulting CVA above 0.1 (Graph 1). No significant correlation between CVA and the number of administered doses of procaine was demonstrated (Table 5).

The average time from the onset of complaints to examination at our outpatient clinic was 33.5 hours in the case of BRAO (median 13.5; minimum 2 hours; maximum 168 hours) and 28.4 hours in the case of CRAO (median 8.0; minimum 1 hour; maximum 240 hours). The time window for administration of IVT was met by 2 patients in the BRAO group (Graph 2) and 14 patients in the CRAO group (Graph 3). No significant difference was demonstrated between the groups in terms of the time delay before examination (Table 6).

For patients with BRAO, in 50% of cases the first point of contact was the general outpatient clinic of the Department of Ophthalmology at LF UP and FNOL, and in 50% of cases the local eye clinic. In the group of patients with CRAO the distribution was also virtually equal. The groups did not differ significantly in terms of the first point of contact (Table 7).

We recorded a significantly higher incidence of arterial hypertension (HN) in the CRAO group (88.2% vs. 63.6%, $p = 0.023$). In terms of the incidence of diabetes mellitus (DM), hyperlipidemia (HLP), and smoking, the groups did not show any statistically significant difference (Table 8). We determined systemic disorders from the patients' personal medical history at the baseline examination. In two patients from the CRAO group in whom we performed

Table 4. Central visual acuity (CVA) before treatment/after treatment in groups with central (CRAO) and branch (BRAO) arterial occlusion

		group		Mann-Whitney U test p-value
		BRAO	CRAO	
CVA before treatment	Mean	0.641	0.016	< 0.0001
	Standard deviation	0.378	0.071	
	Median	0.750	0.001	
	Minimum	0.001	0.000	
	Maximum	1.000	0.500	
CVA after treatment	Mean	0.687	0.094	< 0.0001
	Standard deviation	0.299	0.200	
	Median	0.600	0.001	
	Minimum	0.100	0.000	
	Maximum	1.000	1.000	
Change in CVA (before-after)	Mean	0.045	0.078	0.279
	Standard deviation	0.274	0.187	
	Median	0.000	0.000	
	Minimum	-0.370	-0.029	
		0.799	0.950	

CVA – central visual acuity

a Doppler examination during hospitalization we diagnosed ipsilateral stenosis of the internal carotid artery. Of other RF not listed in table 8, one patient in the CRAO group had demonstrated myelodysplastic syndrome and one patient had undergone mechanical replacement of the aortic valve in combination with replacement of the ascending aorta by vascular prosthesis. In the BRAO group one patient was using hormonal contraception.

DISCUSSION

Retinal artery occlusion is included within the group of acute retinal arterial ischemic disorders. CRAO (Figure 1) results in sudden loss of vision and ranks among important issues in ophthalmology. Similarly, BRAO (Figure 2) leads to sudden segmented disorder of vision. RAO may be both transitional and permanent [8].

The presumed incidence of CRAO is 1–2 cases per 100 000 of the population [2]. Occlusion of the ophthalmic artery and BRAO are rare, and constitute approximately one third of RAO [2]. As regards RF, the EAGLE (European Assessment Group for Lysis in the Eye) study demonstrated a high prevalence of cardiovascular RFs in patients with CRAO: obesity (82%), HN (73%), smoking (49%), HLP (49%),

Table 5. Improvement in central visual acuity (CVA) depending on the number of procaine infusions in groups with central (CRAO) and branch (BRAO) arterial occlusion

	Change of CVA (before-after)	
BRAO	Correlation Coefficient	-0.256
	p-value	0.250
CRAO	Correlation Coefficient	0.076
	p-value	0.595

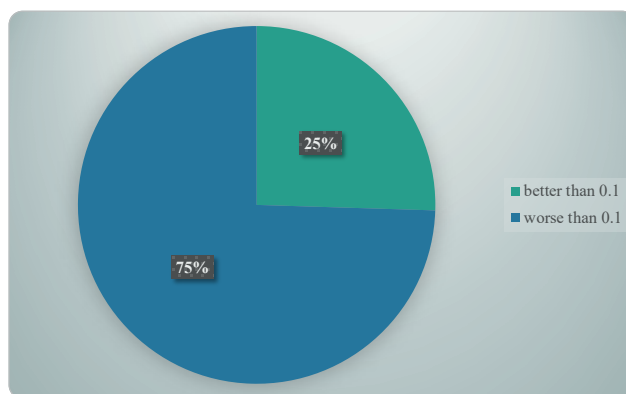
Table 6. Time delay (in hours) to examination in groups with central (CRAO) and branch (BRAO) arterial occlusion groups

	group		Mann-Whitney U test p-value
	BRAO	CRAO	
Mean	33.5	28.4	0.051
Standard deviation	41.3	53.4	
Median	13.5	8.0	
Minimum	2	1	
Maximum	168	240	

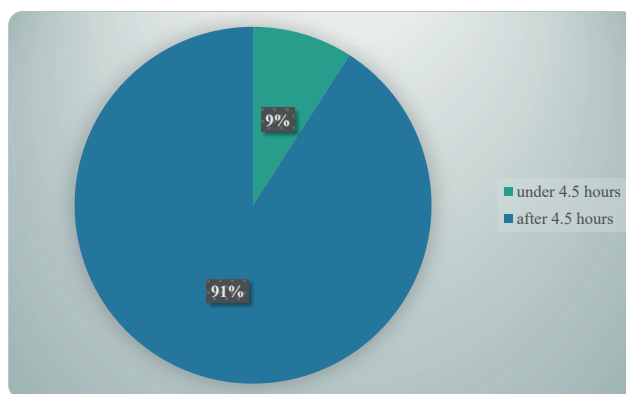
Table 7. The place of the patient's first contact with the doctor

	BRAO		CRAO		p-value
	Quantity	Percent	Quantity	Percent	
Eye clinic FNOL	11	50.0%	28	54.9%	0.859
Neurology clinic FNOL	0	0.0%	1	2.0%	
Ophthalmologist	11	50.0%	22	43.1%	

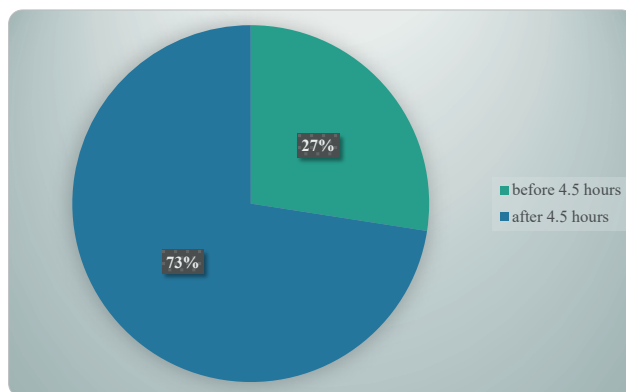
AH – arterial hypertension, DM – diabetes mellitus, HLP – hyperlipidemia



Graph 1. Final central visual acuity (CVA) in patients with central retinal artery occlusion (CRAO)



Graph 2. Time window for possible intravenous thrombolysis (IVT) in the branch retinal artery occlusion (BRAO) group



Graph 3. Time window for possible intravenous thrombolysis (IVT) in the central retinal artery occlusion (CRAO) group

Table 8. Comparison of the occurrence of risk factors in groups with central (CRAO) and branch (BRAO) arterial occlusion

		BRAO		CRAO		p-value
		count	percent	count	percent	
HN	yes	14	63.6%	45	88.2%	0.023
	no	8	36.4%	6	11.8%	
DM	yes	5	22.7%	15	29.4%	0.557
	no	17	77.3%	36	70.6%	
HLP	yes	15	68.2%	40	78.4%	0.351
	no	7	31.8%	11	21.6%	
Smoking	yes	7	31.8%	13	29.5%	0.564
	Ex-smoker	2	9.1%	9	20.5%	
	no	13	59.1%	22	50.0%	

AH – arterial hypertension, DM – diabetes mellitus, HLP – hyperlipidemia

and DM (14%) in 77 patients. In total 67% of the patients had at least one RF. There was also a high prevalence of cardiological disorders in this cohort of patients (coronary diseases 22%, atrial fibrillation 20%, heart valve disease 17%) [9]. In our cohort every patient had at least one RF.

In the case of transient symptoms in the sense of amaurosis fugax, in which CRAO or BRAO is expected in first place, the prevalence of RF is different. Another study conducted by Martinez-Viguera et al. evaluated the distribution of presumed causes differently – 15.4% critical stenosis of the internal carotid artery (ACI), 4.4% atrial fibrillation, 11% other determined causes, e.g. arterial dissection, and 69.2% undetermined etiology [10].

Of other causes we may also encounter further triggering factors of RAO, e.g. iatrogenic CRAO. In the perioperative period RAO most frequently occurs as a consequence of incorrect positioning of the patient and external pressure on the eye. Pressure in the orbit may be increased also following retrobulbar hemorrhage, which is associated with vascular injuries during surgery of the nasal cavities or nose. Another potential cause is retinal microembolizations, which frequently occur during open heart surgery [11].

In 2003 M. Gupta et al. described a case of anterior ischemic optic neuropathy (AION) in a patient following acute cesarian section due to obstructed labor, performed under epidural anesthesia. A possible chance injury of the dura mater was recorded during the performance of epidural anesthesia, though the patient continued to be treated in epidural rather than spinal anesthesia. After administration of 6 mg ephedrine the patient suffered acute hypotension with a duration of 3–4 minutes, during which her blood pressure dropped to 62/50 mmHg; subsequently it was readjusted to 120/64 mmHg. Further supplementing of anesthesia was performed using bupivacaine 0.5%. It is difficult to determine unequivocally whether the development of AION in this patient was in connection with complication of neuraxial blockade, or rather with the hypotension suffered by the patient [12].

Gill and Heavner described retinal hemorrhages following epidural applications of fluids/epiduroscopy,

which evidently occur as a consequence of an increase of pressure of cerebrospinal fluid. A sudden increase of epidural pressure is transmitted to the subarachnoid space towards the optic nerve sheath, where compression of the optic nerve and its vascular supply occurs. Compression of blood vessels leads to a rupture of the retinal vessels. The cohort incorporated 12 patients (mean age 50 years, 83.3% women, 16.7% men). Bolus administration of fluid with or without epiduroscopy was considered to be the triggering factor. The most common finding was retinal hemorrhage, which occurred bilaterally in 58.3% of cases. Correction of the condition was recorded in 79.2% of cases [13]. CRAO may also occur as a complication of cosmetic injections if the synthetic material is applied to the facial arteries, which have collaterals with the ophthalmic artery. A meta-analysis conducted by Kapoor et al. indicated that occlusion of the ophthalmic artery and CRAO were the most common variants, followed by BRAO. In the case of iatrogenic occlusion the prognosis is infaust because the material does not have a fibrin base, and as a result thrombolysis cannot be considered as a treatment [14]. Carey presented a case report of a 60-year-old woman who was referred to their center with CRAO, and upon a further examination an aneurysm of the intraorbital region of the ophthalmic artery was determined, which was considered an etiological factor of the onset of CRAO in this patient [15]. Other mentioned causes of RAO are persistent foramen ovale, intravenous administration of immunoglobins and endocarditis [16–18].

One of the patients in the BRAO group was using hormonal contraception. A large population study covering 24 million people did not determine an increased risk of retinal artery occlusion in women using hormonal contraception in comparison with women without contraception [19].

As a rule CRAO is manifested in a sudden painless deterioration of vision in one eye. The variability of the deterioration of vision is broad: in more than 80% of patients initial CVA is on the level of counting fingers, but in the presence of the cilioretinal artery CVA may remain almost normal.

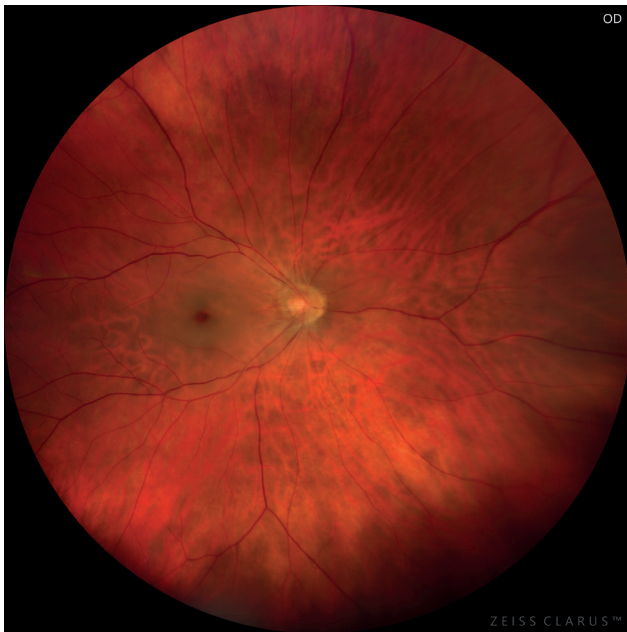

Figure 1. Photograph of the fundus of a patient with central retinal artery occlusion

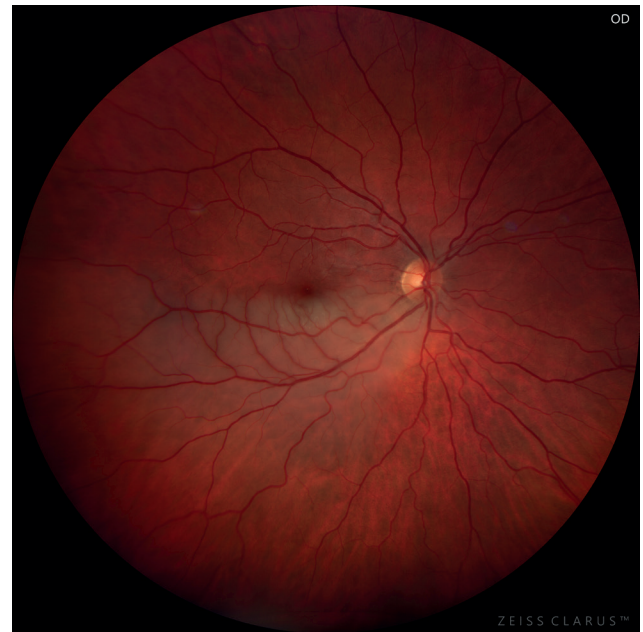

Figure 2. Photograph of the fundus of a patient with branch retinal artery occlusion

BRAO is also manifested in acute painless loss of vision, but both initial and resulting CVA are far better in comparison with CRAO [20]. In his study Yuzurihara compared resulting CVA in patients who had suffered BRAO and CRAO: CVA upon admission and upon discharge was far worse in patients with CRAO than in patients with BRAO. Resulting CVA worse than 0.1 was observed in 14 out of 23 (61%) of patients with CRAO and in only one out of 30 (3%) of patients with BRAO. Only 5 out of 23 (22%) patients with CRAO and 24 out of 30 (80%) of patients with BRAO recorded resulting CVA of 0.5 or better. In our cohort 22 patients in the BRAO group (100%) and only 13 patients in the CRAO group (25.5%) had resulting CVA above 0.1.

Diagnosis of RAO is not complicated. The patient reports for an examination with sudden painless loss of vision. The ophthalmological evaluation of the patient with sudden loss of vision includes examination of the anterior segment and subsequently also the ocular fundus in artificial mydriasis [4]. Most patients have an ipsilateral relative afferent pupillary defect. The typical finding on the fundus includes ischemic retinal edema and a “cherry-red spot” in the macula (manifestation of preserved choroidal perfusion beneath the fovea surrounded by a pale retina), retarded segmental blood flow in constricted retinal arteries, while the optic nerve papilla usually has a normal appearance [21]. In patients with CRAO, retinal emboli are visible in fewer than 10% of cases, because the majority of these emboli are located retrobulbarly. Combination with papilledema indicates a rare combination of anterior ischemic neuropathy of the optic nerve and inner retinal ischemia, probably reflecting vasculitis of the posterior ciliary arteries. Arteritic CRAO is suspected in patients aged over 50 years with systemic manifestations such as jaw claudication, polymyalgia rheuma-

tica, diffuse pain in the back of the neck, new attacks of headache, and increased inflammatory markers [8].

In the case of RAO, imaging examinations in ophthalmology are used in particular for documentation and monitoring of the anatomical finding. Color fundus photography, fluorescence angiography, and optical coherence tomography (OCT) are the gold standard for visualization of microstructural changes. However, there has also been a recent expansion in the use of OCT angiography, orbital ultrasound, and retinal functional imaging. It is expected that noninvasive imaging methods may contribute to evaluating the vitality of tissue and determining the personalized therapeutic window, similarly as in patients with stroke [22].

The most important prognostic factor that has an influence on resulting CVA is initial CVA. As soon as RAO ensues, the capacity of the retina to recover depends on whether dislocation of embolus or thrombus occurs, and above all on the time of tolerance of retinal ischemia. Acute RAO usually leads to permanent retinal ischemia and cell death within a few hours [9]. The conclusions of electrophysiological, histopathological and morphometric studies have shown that in elderly atherosclerotic hypertensive macaque rhesus monkeys, no detectable retinal damage occurred in CRAO with a length of duration of 97 minutes. Although retinal damage occurred between 105 and 240 minutes, following reperfusion a certain degree of restoration of functions was observed in visually evoked potentials [21]. After 240 minutes, total or almost total atrophy of the optic nerve and damage to nerve fibers was determined, which led to massive and irreversible retinal damage. This indicates that the time window for intervention is final and indirectly proportionate to the degree of recovery. The exact time of retinal tolerance, when irreversible damage takes place, is not

yet known, but appears to be no longer than 4 hours [21].

In 2023 Kožner et al. presented as an example a retrospective study in which they evaluated the results following the administration of IVT in patients with CRAO. A statistically significant difference was demonstrated between CVA in patients in the group with early IVT in comparison with groups of patients with delayed IVT and without administration of IVT [6]. In our cohort, within the subgroup of CRAO, 14 patients, i.e. 27.5% attended an eye examination within the time window of 4.5 hours. If these patients had no contraindications they could be referred for IVT.

Despite medical advances, no uniform recommended procedure exists for the management of this disorder. In 2024 Roskal-Walek et al. presented an extensive study in which they evaluated the results of various methods of treating RAO – conservative therapy, IVT, NdYAG laser embolysis and vitrectomy [5]. Conservative therapy incorporates various mechanisms of effect: increasing the deformability of erythrocytes (pentoxifylline), vasodilation (breathing into paper bag, inhalation of carbogen, application of nitroglycerine), increase of partial oxygen pressure in blood (hyperbaric oxygenation), reduction of intraocular pressure (application of antiglaucoma drugs generally and locally, eyeball massage, anterior chamber paracentesis), and reduction of retinal edema (intravenous application of steroids) [5, 23]. The common aim of these therapeutic procedures is to improve or restore blood circulation before retinal necrosis occurs.

The choice of therapy by intravenous administration of procaine in our case was based on the historical use of this treatment in clinical practice at the Department of Ophthalmology of LF UP and FNOL. According to the best of our knowledge, at present no study exists supporting its effectiveness in the treatment of RAO. It has been stated that procaine not only has the properties of an anesthetic, but also acts as an antioxidant, and unlike other anesthetics triggers vasodilation of blood vessels and capillaries, and therefore could be applied also to patients with RAO. Because of these effects, procaine is used not only in anesthesiology, but also in rheumatology, oncology, and psychiatry [24]. Unfortunately, in our study we did not demonstrate its potential positive effect in the treatment of RAO, therefore its place in the treatment of RAO remains controversial.

In 2020 Mac Grory et al. published a retrospective study in which they evaluated the effect of protocol-based intravenous administration of alteplase in patients with CRAO within the typical time window of acute IS from 0 to 4.5 hours in comparison with a control group. It was determined that this therapy is viable, safe and associated with a more favorable ratio of visual recovery than can be expected within a natural course of the disease [25].

By contrast, the THEIA study did not demonstrate any significant benefit of intravenous alteplase in comparison with aspirin for improvement of CVA in patients with CRAO, even in the case of administration within 4.5 hours from the onset of symptoms. Although the results indicate a certain potential effectiveness of thrombolysis,

a larger cohort of patients and other well planned randomized trials (e.g. the TenCRAOS study) are essential in order to provide definitive conclusions [26].

Interesting results were demonstrated in the multicentric study conducted by Jubran et al. Out of a total of 66 included patients, 55 (83%) were treated with IVT, while the control group (non-IVT) consisted of 11 patients. Concurrent acute cerebral ischemia was determined in a total of 15 (23%) patients (12 in the IVT group, 3 in the non-IVT group). One patient in each group suffered an intracranial hemorrhage, and only one patient, who was in the non-IVT group, was defined as a symptomatic intracranial hemorrhage. No other safety problems were recorded. In the patients treated with IVT an insignificant trend towards a greater improvement of CVA was observed [27].

The risk of recurrence of the stroke in the short and long term differs depending on its cause. In the case of clinical symptoms and evidence of carotid artery stenosis (CAS) above 50%, i.e. hemodynamically significant stenosis, it makes sense to divide groups into 50–69% and above 70%. In the first group the 5-year risk reaches the level of 14.6% (95% IS 3.525.7), whereas in the second group it reaches up to 18.3% (95% IS 7.7-39.9) [28]. In the case of untreated atrial fibrillation, the 5-year risk of the stroke ensues from the general cardiovascular risk according to the Framingham Risk Score, and fluctuates within the range of 15% to 75% depending on the presence of other RF [29].

The risk of recurrence of the stroke within 90 days of the first episode of the stroke is \approx 5%, but may differ considerably from $> 10\%$ to $< 1\%$, partially depending on the mechanism of the stroke. According to the recommendations of the American Cardiological Association a patient with IS or transitory ischemic attack should undergo a further examination for the etiology of the stroke and in order to configure secondary prevention within 48 hours of the beginning of the symptoms [30].

With regard to the relatively low incidence of the disorder, the body of data on reperfusion treatment is limited, and at present there is no comprehensive set of recommendations dedicated to this subtype of vascular event. However, a number of studies have been conducted in relation to this issue. A meta-analysis of 7 studies examined the effect of intravenous thrombolysis in comparison with conservative therapeutic procedures, and in the group of up to 4.5 hours of duration of symptoms it is possible to acknowledge a certain benefit [31]. In the group of over 4.5 hours, no benefit was demonstrated. As regards intra-arterial thrombolysis, this was evaluated in the EAGLE study [32], in which no benefit was demonstrated in comparison with conservative therapy. Nevertheless, the study included patients with a period of duration up to 20 hours, and the data were not further stratified according to the time of duration of symptoms.

As mentioned previously, today CRAO is considered a form of the IS [33]. In the methodical instructions of the Ministry of Health of the Czech Republic entitled “Care for patients with acute stroke 2021”, acute visual disorder (blind spots in part of the visual field in both eyes, sudden

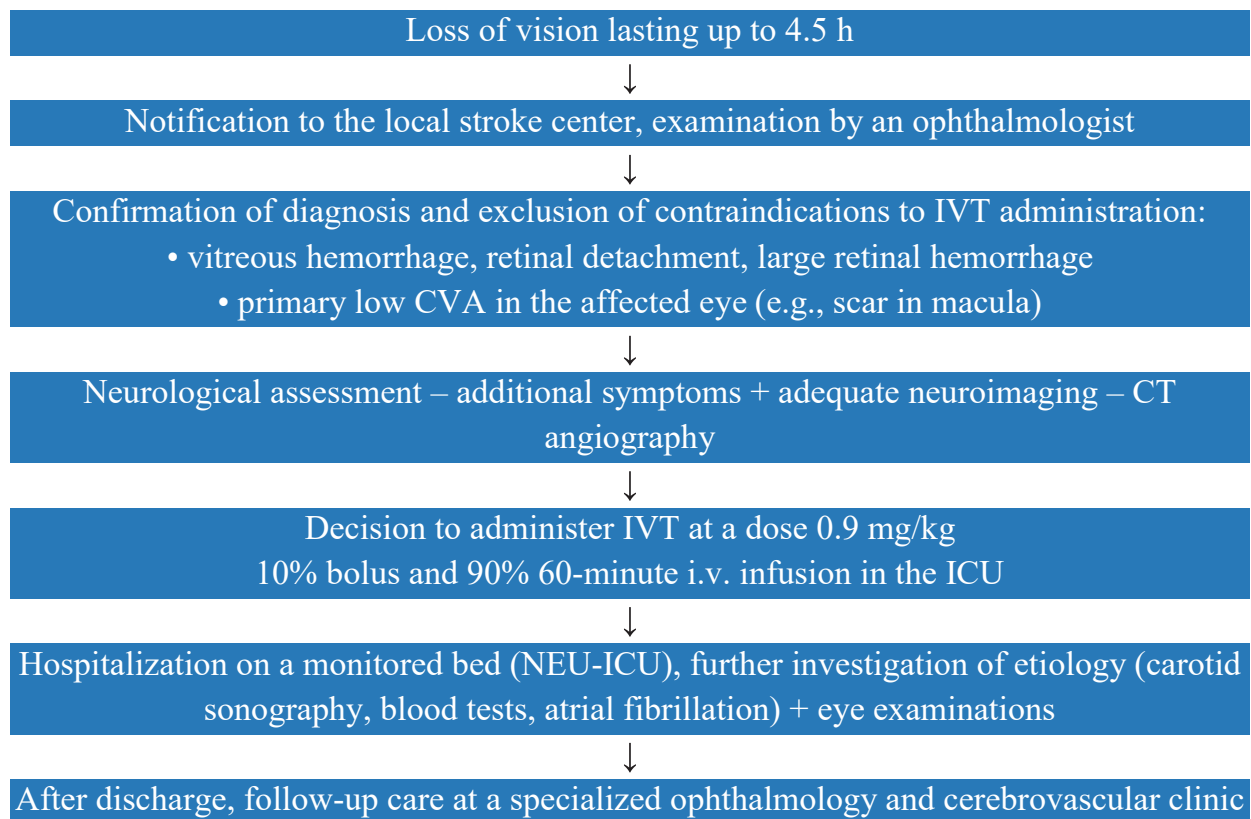


Figure 3. Proposed treatment algorithm for CRAO

IVT – intravenous thrombolysis, CVA – central visual acuity, CT angiography – computed tomography angiography, i.v. – intravenous, ICU – intensive care unit, NEU-ICU – neurological intensive care unit, CRAO – central retinal artery occlusion

loss of sight in 1 eye, diplopia) is ranked among the secondary clinical symptoms of the acute stroke. A triage-positive patient is one who has suffered a sudden onset of at least one clinical symptom of acute stroke within the last 48 hours. It is necessary to consider a patient whose life is directly endangered to be triage-positive, and such a patient must be transported to the relevant highly specialized care center with sufficient priority [34]. In our cohort only one patient with CRAO was referred from the neurological outpatient clinic of FNOL, which demonstrates insufficient vigilance on the part of both the healthcare staff and the public.

We consider it necessary to mention that in the methodical instructions of the Ministry of Health of the Czech Republic entitled “Care for patients with acute stroke 2021”, CRAO is not classified as a subtype of the IS [34]. According to the current set of data on the preparation (SPC), the administration of alteplase (Actilyse®) has only three indications, i.e. myocardial infarction, IS, and massive pulmonary embolism accompanied by hemodynamic instability [35]. This means that in the case of administration of IVT this would concern off-label therapy unless there is a change to the recommendations for the stroke or an extension of the indications in the SPC.

The recommendations continue to apply on the level of expert opinion, nevertheless on the basis of the above-mentioned studies it is possible to propose a time window for IVT of up to 4.5 from the onset

of symptoms, while excluding systemic contraindications and ophthalmological diagnoses included within these contraindications as listed in the AHA/ASA (American Heart Association/American Stroke Association) and ESO (European Stroke Organisation) recommendations [33, 36].

After careful consideration of all the positive and negative arguments, as well as intensive interdisciplinary discussion, we have decided to enable the introduction of this treatment also at our center. We have chosen 4.5 hours from the onset of clinical symptoms of the IS as the time window appropriate for the administration of IVT. The task of the ophthalmologist is in particular to exclude ocular contraindications for the administration of IVT – hemophthalmos, retinal detachment, large retinal hemorrhage or primarily low CVA in the affected eye, e.g. as a consequence of age-related macular degeneration or anterior ischemic neuropathy of the optic nerve [25]. The ophthalmologist shall then refer the patient to the Emergency Department for evaluation by a neurologist with subsequent administration of IVT. After discharge from the Department of Neurology at FNOL the patient shall make an appointment for an occlusion consultancy at the Department of Ophthalmology at LF UP and FNOL for further observation. At present we are working in close cooperation with the Department of Neurology on the introduction of a precise procedural diagram, a proposal for which is presented below (Figure 3).

CONCLUSION

In our study we did not demonstrate a positive effect of intravenous administration of procaine in the treatment of RAO, and its place within conservative therapy of RAO therefore remains controversial. A significant proportion of patients with CRAO (27%) underwent an examination within 4.5 hours from the

onset of complaints, and therefore in the absence of contraindications could have benefited from the administration of IVT. The introduction of a unified nationwide protocol in the management of patients with CRAO therefore appears to be beneficial, since it will help improve primary care for patients and also create a path for referring patients to experienced neurologists in order to configure secondary prevention.

REFERENCES

1. Cho SC, Jung C, Lee JY, Kim SJ, Park KH, Woo SJ. Retinal artery occlusion after intravascular procedures: Case Series and Literature Review. *Retina*. 2019 Apr;39(4):766-778
2. Scott IU, Campochiaro PA, Newman NJ, Biousse V. Retinal Vascular Occlusions. *The Lancet*. 2020 Dec;396(10266):1927-1940
3. Černík D, Neumann J, Neradová J. Okluze centrální retinální tepny jako podceňovaná forma ischemického iktu. *Neurol. Praxi*. 2023;24(6):474-476. Czech.
4. Mac Grory B, Schrag M, Biousse V, et al. Management of Central Retinal Artery Occlusion: A Scientific Statement From the American Heart Association. *Stroke* [Internet]. 2021. June [cited 2025 Oct 17];52(6). Available from: <https://www.ahajournals.org/doi/10.1161/STR0000000000000366>
5. Roskal-Walek J, Ruzik A, et al. Therapeutic Strategies for Retinal Artery Occlusion—A Literature Review. *J Clin Med*. 2024 Nov 13;12(22):6813.
6. Kozner P, Eichenmann L, Ceska Burdova M, Pavlikova M, Hlozaneck M, Dotrelova D. Long-term outcomes of intravenous fibrinolysis in central retinal artery occlusion. *Sci Rep*. 2023. Nov 22;13(1):20505.
7. Kalábová S, Marešová K, Karhanová M. Non-Arteritic Anterior Ischaemic Optic Neuropathy: Treatment and Risk Factors. *Cesk Slov Oftalmol*. 2020 Oct 1;76(2):78-87.
8. Hayreh SS. Acute retinal arterial occlusive disorders. *Prog Retin Eye Res*. 2011 Sept;30(5):359-994.
9. Callizo J, Feltgen N, Pantenburg S, et al. Cardiovascular Risk Factors in Central Retinal Artery Occlusion. *Ophthalmology*. 2015 Sept;122(9):1881-1888.
10. Martínez-Viguera A, Xucla-Ferraronis T, Collet R, et al. Clinical characteristics and outcome of amaurosis fugax due to transient retinal ischemia: Results from a contemporary cohort. *J Stroke Cerebrovasc Dis*. 2023 Nov;32(11):107335
11. Roth S. Perioperative visual loss: what do we know, what can we do? *Br J Anaesth*. 2009 Dec;103 Suppl 1(Suppl 1):i31-40.
12. Gupta M, Puri P, Rennie IG. Anterior ischemic optic neuropathy after emergency caesarean section under epidural anesthesia. *Acta Anaesthesiol Scand*. 2002 July;46(6):751-752.
13. Gill JB, Heavner JE. Visual Impairment Following Epidural Fluid Injections and Epiduroscopy: A Review. *Pain Med*. 2005 Sept;6(5):367-374.
14. Kapoor KM, Kapoor P, Heydenrych I, Bertossi D. Vision Loss Associated with Hyaluronic Acid Fillers: A Systematic Review of Literature. *Aesthetic Plast Surg*. 2020. June;44(3):929-944.
15. Carey AR. Central Retinal Arterz Occlusion Due to Intraorbital Ophthalmic Artery Aneurysm. *J Neuroophthalmol*. 2019 Mar;39(1):125-126.a
16. Wieder MS, Blace N, Szlechter MM, Shulman E, Thankenchen J, Mbekeani JN. Central retinal artery occlusion associated with patent foramen ovale: a case report and literature review. *Arq Bras Oftalmol* [Internet]. 2021 [cited 2025 Oct 17];84(5). Available from: <https://www.scielo.br/j/abo/a/KYVjmbj3ftQKltbKsv3fGP-k/?lang=en>
17. Arias-Peso B, Méndez-Martínez S, Puzo M, Castro Roger L, Pardiñas Barón N, Ruiz-Moreno O. Central retinal arterz occlusion secondary to intravenous immunoglobulin infusion. *J Fr Ophthalmol*. 2023 Feb;26(2):e61-63.
18. Chebolu AP, Wallsh JO, Falk N, Bhatnagar P. Central retinal artery occlusion as presentation of bartonella endocarditis. *Retin Cases Brief Rep*. 2023 Nov 1;17(6):649-651. doi: 10.1097/ICB.0000000000001268. PMID: 37903305.
19. Niazi S, Gnesin F, Jawad BN, et al. Hormonal Contraception and Retinal Vascular Occlusion Risk. *Am J Ophthalmol*. 2025 Sept;277:286-294.
20. Yuzurihara D, Iijima H. Visual Outcome in Centr Retinal and Branch Retinal Artery Occlusion. *Jpn J Ophthalmol*. 2004 Sept;48(5):490-492.
21. Varma DD, Cugati S, Lee AW, Chen CS. A review of central retinal artery occlusion: clinical presentation and management. *Eye*. 2013 June;27(6):688-697.
22. Mac Grory B, Schrag M, Poli S, et al. Structural and Functional Imaging of the Retina in Central Retinal Artery Occlusion – Current Approaches and Future Directions. *J Stroke Cerebrovasc Dis*. 2021 July;30(7):105828.
23. Dattilo M, Newman NJ, Biousse V. Acute retinal arterial ischemia. *Ann Eye Sci*. 2018;3:28.
24. Oettmeier R, Reuter U. The Procaine-Base-Infusion: a Review after twenty Years of Use. *J Med - Clin Res Rev*. 2017 Dec 30;1(3):1-8.
25. Mac Grory B, Nackenoff A, Poli S, et al. Intravenous Fibrinolysis for Central Retinal Artery Occlusion: A Cohort Study and Updated Patient-Level Meta-Analysis. *Stroke*. 2020 July;51(7):2018-2025.
26. Préterre C, Gaultier A, Obadia M, et al. Intravenous alteplase versus oral aspirin for acute central retinal artery occlusion within 4-5 h of severe vision loss (THEIA): a multicentre, double-dummy, patient-blinded and assessor-blinded, randomised, controlled, phase 3 trial. *Lancet Neurol*. 2025 Nov;24(11):909-919. doi: 10.1016/S1474-4422(25)00308-4
27. Jubran H, Baumgartner P, Jurado EA, et al. Safety of intravenous thrombolysis in central retinal artery occlusion patients with concomitant acute cerebral infarctions. *J Neurol Sci*. 2025 Apr;471:123441.
28. Correction to *Lancet Neurol* 2021; 20: 193-120. *Lancet Neurol*. 2021 May;20(5):e4.
29. Dufouil C, Beiser A, McLure LA, et al. Revised Framingham Stroke Risk Profile to Reflect Temporal Trends. *Circulation*. 2017 Mar 21;135(12):1145-1159.
30. Kleindorfer DO, Towfighi A, Chaturvedi S, et al. 2021 Guideline for the Prevention of Stroke in Patients With Stroke and Transient Ischemic Attack: A Guideline From the American Heart Association/American Stroke Association. *Stroke* [Internet]. 2021 July [cited 2025 Oct 17];52(7). Available from: <https://www.ahajournals.org/doi/10.1161/STR.0000000000000375>
31. Schrag M, Youn T, Schindler J, Kirshner H, Greer D. Intravenous Fibrinolytic Therapy in Central Retinal Artery Occlusion: A Patient-Level Meta-analysis. *JAMA Neurol*. 2015 Oct;72(10):1148-54. doi: 10.1001/jamaneurol.2015.1578
32. Schumacher M, Schmidt D, Jurklics B, et al. EAGLE-Study Group. Central retinal artery occlusion: local intra-arterial fibrinolysis versus conservative treatment, a multicenter randomized trial. *Ophthalmology*. 2010 Jul;117(7):1367-75.e1. doi: 10.1016/j.ophtha.2010.03.061
33. Correction to: 2021 Guideline for the Prevention of Stroke in Patients With Stroke and Transient Ischemic Attack: A Guideline From the American Heart Association/American Stroke Association. *Stroke* [Internet]. 2021 July [cited 2025 Oct 17];52(7). Available from: <https://www.ahajournals.org/doi/10.1161/STR.0000000000000383>
34. Ministerstvo zdravotnictví České republiky. Metodický pokyn – Péče o pacienty s akutní cévní mozkovou příhodou 2021 [Internet]. Praha; 2021. Available from: <https://mzd.gov.cz/metodicky-pokyn-pece-o-pacienty-s-akutni-cevni-mozkovou-prihodou-2021/>
35. Boehringer Ingelheim International GmbH. Actilyse 1 mg/ml – Souhrn údajů o přípravku. sp. zn. SUKLS74208/2024. Ingelheim am Rhein: Boehringer Ingelheim; 2024
36. Berge E, Whiteley W, Audebert H, et al. European Stroke Organisation (ESO) guidelines on intravenous thrombolysis for acute ischaemic stroke. *Eur Stroke J*. 2021 Mar;6(1):I-LXII. Epub 2021 Feb 19. doi: 10.1177/2396987321989865