

CASE REPORT

M, Michalec, E. Vlková, V. Matušková,
D. Vysloužilová, L. Michalcová

Department of Ophthalmology, Faculty of Medicine, Masaryk University and University Hospital Brno
Head: kliniky prof. MUDr. E. Vlková, CSc.

Diagnostic Pitfalls of Pseudo-Foster Kennedy Syndrome – A Case Report

SUMMARY

To the outpatient facility of the Department of Ophthalmology, Faculty Hospital Brno, Czech Republic, E.U., was in June 2013 referred a 24 years old man with the suspicion of Foster Kennedy syndrome. On the fundus examinations, the findings were in correlation with the symptoms of this syndrome: slightly pale optic disc of the right eye and edema with the anterior extension of the optic nerve head of the left eye. The perimetric examination revealed bilateral visual fields defects, mainly in the nasal parts of the visual fields which is not typical for this syndrome. The native magnetic resonance imaging (MRI) examination was negative. Due to the suspicion of pathologic finding in the visual pathway area, the blood levels of pituitary gland hormones were examined and revealed elevated prolactin levels. In the indicated MRI examination with contrast, in the revised reading, a suspicious microadenoma of the pituitary gland was detected. Due to the atypical changes in the perimetric examinations, other possible causes of visual fields defects as coincidence of multiple, each other independent pathologies (neuritis or neuropathy of the optic nerve, neuromyelitis optica (Devic disease), Leber's hereditary optic neuritis (LHON) etc.) to exclude or to confirm the Pseudo-Foster Kennedy syndrome were taken into account. The patient is regularly followed up at our outpatient facility as well as at the outpatient facility of the Department of Neurosurgery, where, until now, the follow up only was recommended. The diagnosis of this case was, until now, set as Pseudo-Foster Kennedy syndrome, with unclarified cause of the clinical findings.

Key words: Pseudo-Foster Kennedy syndrome, papilledema, prolactinoma, microadenoma.

Čes. a slov. Oftal., 70, 2014, No. 6, p. 242–247

OBJECTIVE

The objective of the study is to provide an illustration of a case of a patient sent to our clinic with suspicion of Foster Kennedy Syndrome. The study points to the necessity and significance of inter-disciplinary co-operation upon differential diagnostics of this rare pathognomonic manifestation.

CASE REPORT

A 24 year old male patient was referred to our clinic due to defocused vision in the left eye which had persisted for one week. Central visual acuity (CVA) in both eyes was 0.9 (correction did not improve) and intraocular pressure 14 torr bilaterally. Upon examination on a slit lamp, the finding was physiological in the anterior segment of both eyes. A pale, bordered papilla was identified on the fundus of the right eye (fig. 1), and an edema of the papilla in the left eye (fig. 2). A relatively afferent pupillary defect (RAPD)

was described in the right eye. A perimetric examination demonstrated the presence of absolute scotomas in the nasal part of the visual field, reaching from the periphery to the central part in the right eye (fig. 3). In the left eye absolute scotomas were present throughout the entire range of the nasal lower quadrant, extending into the temporal lower quadrant (fig. 4). The patient did not state any other complaints in his anamnesis, and did not suffer headache. The patient was subsequently sent to the outpatient neurological clinic, where he was hospitalised for further treatment.

An acute magnetic resonance imaging (MRI) examination of the brain was performed at the neurological clinic, as well as lumbar puncture and sampling of aquaporin antibodies in order to exclude the possibility of neuromyelitis optica. The result of MRI was negative. Upon sampling of the cerebrospinal fluid, no effluent pressure was measured. The biochemical analysis of the fluid was negative, and the result of the sample of aquaporin

antibodies was not yet available at the time of discharge of the patient from hospital. Due to the negative neurological finding, the patient was placed in the care of an ophthalmologist.

In the ocular anamnesis, the patient additionally stated contusion of the left eyeball by a marble at the age of twelve years and contusion of the right eye by a tennis ball at the age of fifteen years, with short-term hospitalisation at the paediatric department of ophthalmology in Brno.

Following the negative neurological conclusion, in the differential diagnostics we considered drusen papillas with partial atrophy of the optic nerve, a combination of the effect of drusen papillas and the condition following contusion of the right eye with accentuation of atrophy of the optic nerve, benign intracranial hypertension, optochiasmatic perineuritis, neuromyelitis optica (Devic's disease), Leber's hereditary optic neuropathy or toxic damage to the optic nerves.

The conducted haematological examination and biochemical examina-

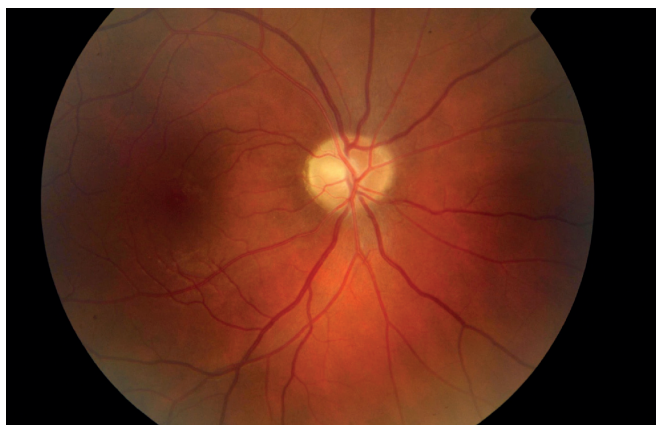


Fig. 1 Fundus of right eye (7/2013) – pale papilla of optic nerve.

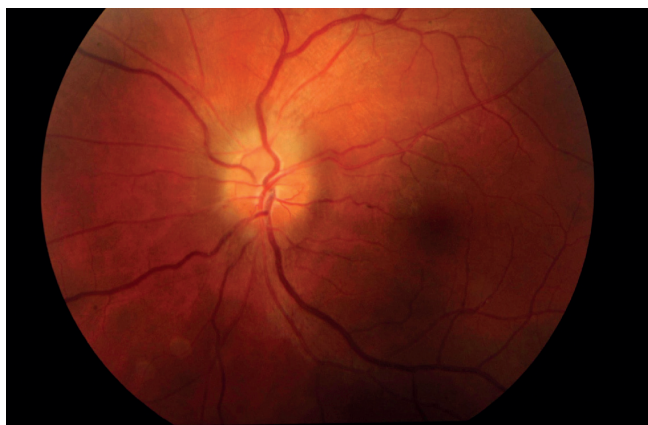

Fig. 2 Fundus of left eye (7/2013) – edema of papilla of optic nerve.

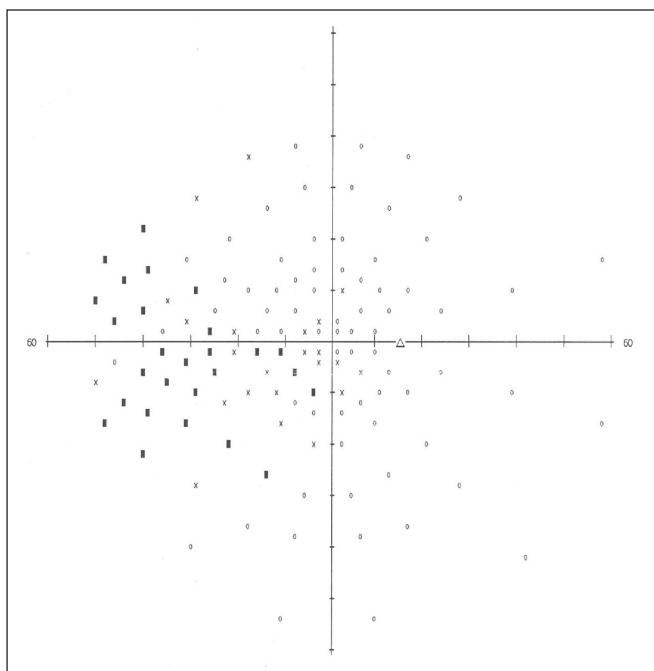


Fig. 3 Perimeter of right eye (7/2013) – before commencement of treatment.

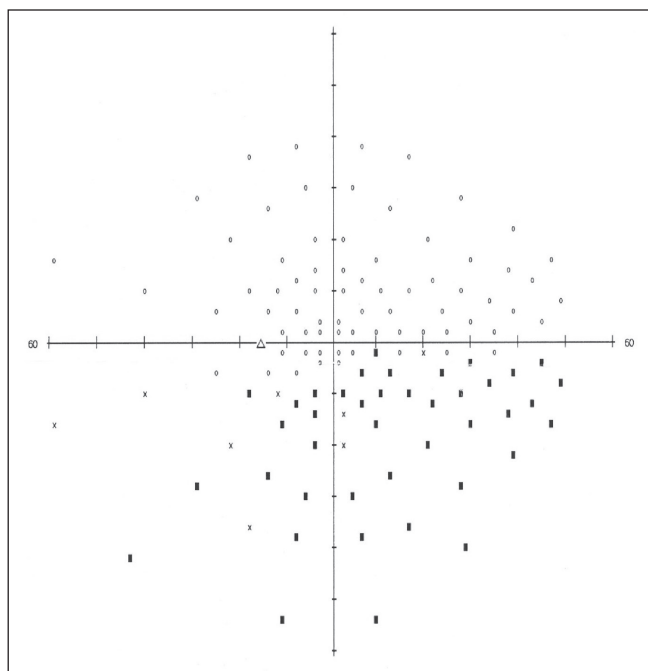


Fig. 4 Perimeter of left eye (7/2013) – before commencement of treatment.

tion of serum and urine were without any pathological finding. An ultrasound examination of the eyeballs demonstrated the presence of edema of the papilla of the optic nerve in the left eye. Visual evoked potentials showed a reduced function of the visual pathway in the sense of a reduction of the number of functional nerve fibres in the right eye, and borderline function of the visual pathway in the left eye, entirely without manifestations of neuritis in the electro-physiological image. An analysis of the thickness of the retinal nerve fibre layers (RNFL) by means of a GDx examination (Nidek GDx VCC) demonstrated a decline in thickness of the nerve fibres in the upper and lower quadrant to beneath the physiological norm in the right eye. In the left eye the thickness of the

RNFL was within the normal referential range, however the result was not valid due to the presence of infiltration of the disc of the optic nerve. Contrast and colour sensitivity were within the norm in both eyes.

Due to the uncertainty of the finding, a targeted sample was taken in order to determine the level of hypophyseal hormones in the blood, which repeatedly demonstrated an increased value of the value of prolactin. A MRI examination of the head using a contrast substance was required in order to demonstrate a hypophyseal microadenoma.

A neurosurgical consultancy recommended a conservative procedure with a control MRI examination of the head at an interval of 1 month, whilst endocrinologists recommended per-

oral treatment of hyperprolactinaemia by Dostinex (cabergoline) 0.5 mg tablet 1x per week. Due to the presence of infiltration of the disc in the left eye as a consequence of assumed intracranial hypertension, we administered Diluran (acetazolamide) during hospitalisation in a dose of 1-1/2-1/2 tablets.

The patient remained treated at our outpatient clinic with Diluran 1/2 tablet 2x per day and potassium supplement per os.

After 9 months the finding in the MRI of the brain is stable, and as a result the neurosurgeon continues to recommend a conservative approach with regular checks of the perimeter, brain MRI and level of prolactin. Upon regular follow-up examinations at our outpatient clinic there is a stable picture of

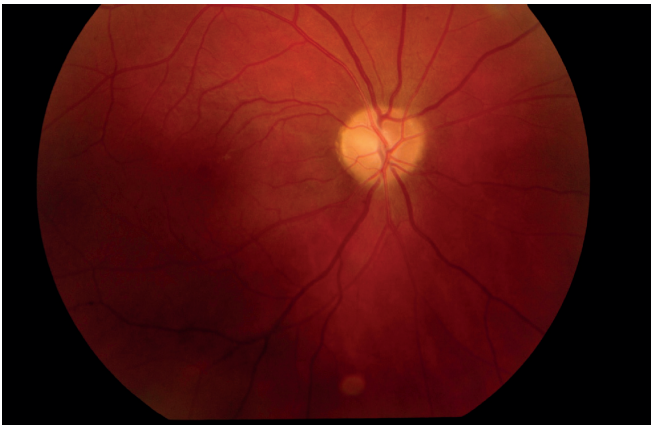

Fig. 5 Fundus of right eye (4/2014) – pale papilla of optic nerve, stable condition.

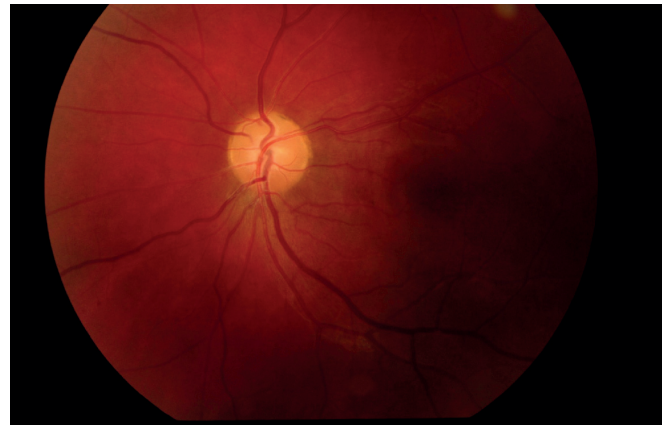

Fig. 6 Fundus of left eye (4/2014) – bordered and pale papilla of optic nerve, without edema.

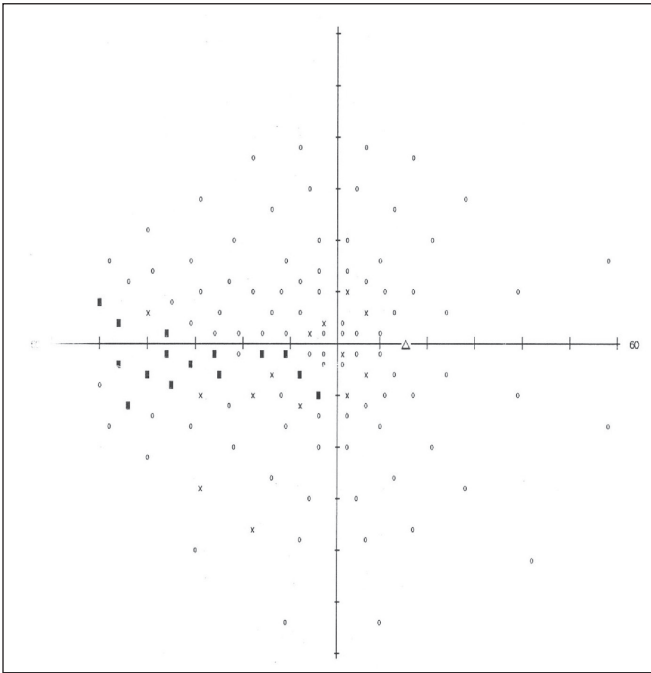


Fig. 7 Perimeter of right eye (4/2014), evident decline in number and extent of scotomas in comparison with previous finding.

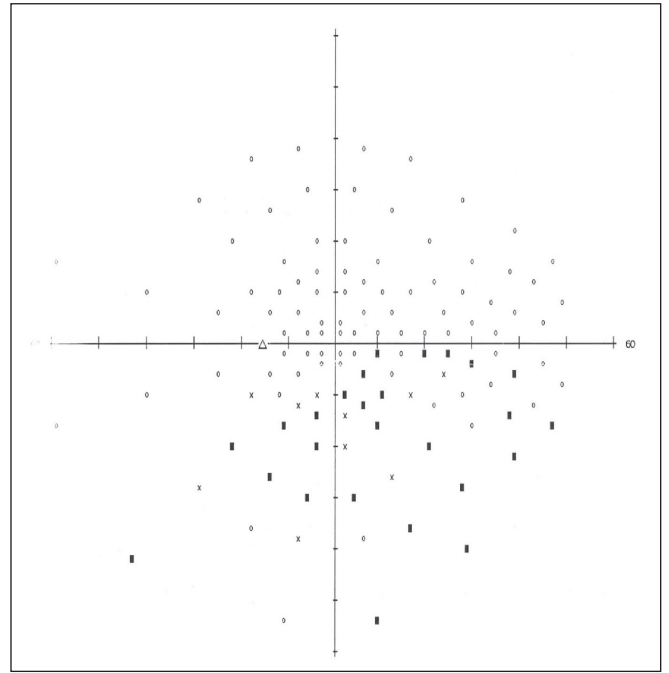


Fig. 8 Perimeter of right eye (4/2014), slight decline in number of absolute scotomas, extent of visual field practically the same as in the previous examination.

a pale bordered papilla in the right eye (fig. 5) and a regression of the edema of the papilla of the optic nerve in the left eye (fig. 6). In comparison with the original finding, the perimetric finding shows a slight decrease in the number of absolute and relative scotomas in the visual field of both eyes, without further progression of the number or extent of scotomas (fig. 7, 8). Central visual acuity in the patient has improved to 1.0 in both eyes. The improvement of visual acuity and the regression of the edema of the papilla of the optic nerve is most probably a manifestation of the decline in intracranial pressure due to the influence of anti-edematous therapy. Subjectively the patient feels well, and states no undesirable effects

from systematic therapy. The patient is regularly observed at our outpatient clinic, repeated examinations of the perimeter indicate a stable condition. In future a neurological examination with lumbar puncture and measurement of effluent pressures is planned.

DISCUSSION

Foster Kennedy Syndrome was first described by the British neurologist Sir William Gowers in 1893. In 1911, the Irish-American neurologist Robert Foster Kennedy published a similar study on this phenomenon (5), in which he described typical manifestations such as atrophy of the optic nerve in one eye with central scotoma, edema of the pa-

pilla of the other eye and anosmia as a consequence of compression of the olfactory nerve on the side of the atrophy of the optic nerve. The cause is tumours of the frontal lobe and suprasellar tumours. A variant of Foster Kennedy Syndrome is Lillie's syndrome with central scotoma on the side of the tumour and a bilateral image of edema of the papilla (9). If the presence of malignant or benign expansive processes explaining the clinical picture is not confirmed, this more commonly represents an incidence of "Pseudo-Foster Kennedy Syndrome". Previously, the origin of the clinical picture was most frequently explained by vascular or ischemic changes on the papillas of the optic nerves (12). Diagnostic uncertainties are not

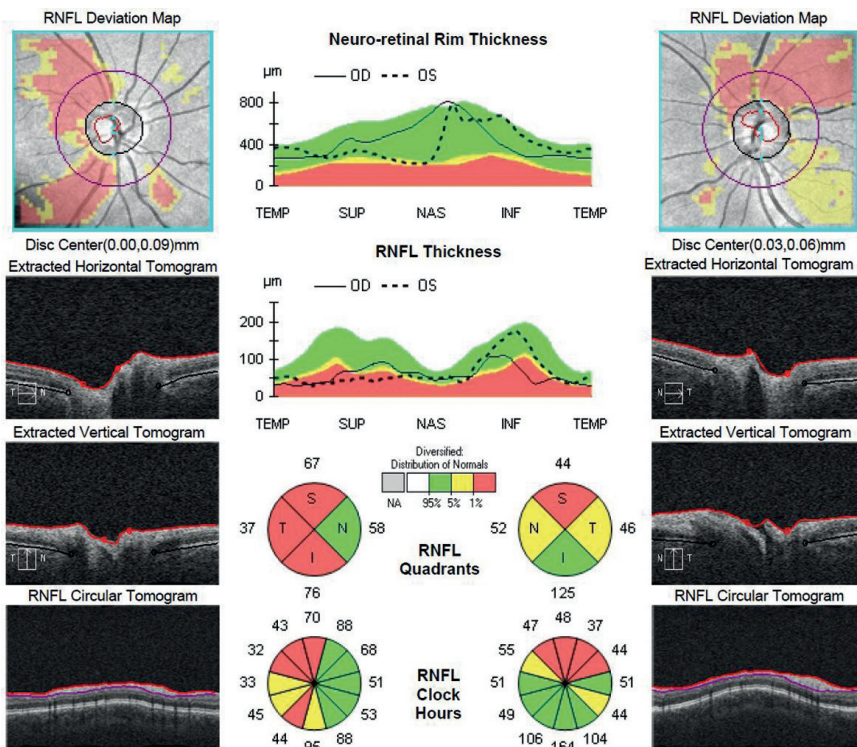


Fig. 9 OCT of papillas of optic nerves in both eyes with clear decrease in thickness of RNFL.

uncommon. In the literature, cases of pseudo-Foster Kennedy Syndrome as a consequence of idiopathic intracranial hypertension (15) or anterior ischemic neuropathy of the optic nerve (AION) are described in combination with frontoparietal malignant glioma (11) or sellar meningioma growing into the optical channel (2).

In the case of pressure lesions of the pregeniculate part of the visual pathways as causes of the incidence of an image of Foster Kennedy Syndrome, in the first place we consider a tumour etiology. The cause of atrophy of the optic nerve is pressure on the optic nerve by close contact with an expansive process. The cause of edema of the optic nerve in the second eye is explained by means of a secondary increase of intracranial pressure through a blockade of the flow of cerebrospinal fluid as a consequence of further growth of the tumour. Increased pressure by means of the edema of the papilla is not manifested upon an already atrophic nerve. Defects in the visual field of both eyes originate most frequently due to the presence of tumour tissues in close proximity to the chiasma. These are mainly hypophyseal adenomas and meningiomas from the coating of the central nervous system (CNS). In rare cases there are slow-growing craniopharyngiomas ensuing from a Rathke's cleft cyst.

The most common expansive processes in the region of the chiasma include hypophyseal adenomas, which are classified according to secretion activity. Prolactinomas are most commonly secretory adenomas (35%), followed by non-functional adenomas (endocrine inactive) (25%), adenomas with hypersecretion of the somatotrophic (15%) and corticotrophic (15%) hormone. In rare cases, adenomas are found with overproduction of thyroid stimulating, luteinising and follicle stimulating hormones. Occasionally adenomas with mixed secretion of two or more hormones also occur (6). Other publications place non-functional adenomas (42.5%) in first place, followed by hormonally active adenomas (41.3%). In the case of a hypophyseal adenoma there is mostly a typical picture and development of bitemporal hemianopsia. The blind spot begins in the upper temporal quadrant, mostly with fully preserved CVA. Upon further progression the blind spot spreads to the temporal lower quadrant up to an image of complete bitemporal hemianopsia, respecting the vertical meridian. CVA remains satisfactory, though in most cases there is a more pronounced deterioration of CVA in one eye. After temporary stabilisation of the perimeter with an image of bitemporal hemianopsia, upon a further growth of the tumour the blind spot encroaches into

the lower nasal quadrant, where CVA is now severely impaired (13).

In the differential diagnostics we must also reckon with atypical blind spots of the visual field. These include monocular asymmetrical tractional hormonal hemianopsia, in rare cases also concentric constriction of the visual field and binasal hemianopsia (13). The cause of atypical perimeters can perhaps be explained by an atypical growth of the tumour and anatomic variations in the region of the chiasma. Prolactinoma is the most frequently occurring hormonally active hypophyseal adenoma with a pathological increase in the level of prolactin, known as "hyperprolactinaemia". The prevalence is estimated at 500 cases per million of the population and the incidence at 2.7/100000 per year. As many as 70% of prolactinomas consist of microprolactinomas (size up to 10 mm), which are 20x more frequent in women, the remainder consist of macroprolactinomas (size of 10 mm and more), with equal incidence in both sexes (14).

Hyperprolactinaemia is manifested as hypogonadism (in women infertility, menstrual disorder, amenorrhea, in men a less pronounced decline in libido and potency, and infertility), gactorrhea, in the case of larger dimensions sometimes also hypopituitarism and diabetes insipidus. Ocular manifestations as a result of expansion of prolactinoma include a reduction of CVA, defects of the visual field, diplopia etc. (17).

In addition to laboratory examinations, the diagnosis of prolactinoma relies upon the use of display methods. At present we have computer tomography (CT) and nuclear magnetic resonance imaging (MRI) available. MRI examination is more precise and generally more beneficial (7). It frequently occurs that in the case of hypophyseal adenoma, the most demonstrable illustration may be of the 3rd ventricle of the brain by means of a contrast substance (16). The method of selection, though not routinely used, is the radioisotope examination SPECT (single photon emission computerised tomography) (7).

The first choice of therapy for hyperprolactinaemia is medicamentous treatment using dopamine agonists (terguride, bromocriptine, cabergoline) (1). Cabergoline has an inhibiting effect on lactotrophic cells of the hypophysis, which is manifested in a reduction of the overall production of prolactin. An advantage of its use is administration once to twice per week, and its effect frequently even upon resistance to another preparation (17). In

the treatment of intracranial hypertension, the pharmaceutical of first choice is acetazolamide, a carboanhydrase inhibitor which reduces the formation of cerebrospinal fluid (CSF). If there is no improvement, it is necessary to create a lumbar peritoneal shunt (3). Surgical and radiation treatment of prolactins is indicated in cases where medicamentous therapy is not tolerated or there is resistance to this therapy. The surgical procedure is indicated by the neurosurgeon according to the size and position of the expansion. An alternative is external radiation by Leksell gamma knife or fractionated external beam radiation (linear accelerator) (17).

The case of our patient with microadenoma is similar to other cases described in the literature (3, 8). The diagnosis of the cause of the finding on the papillas with a defective perimeter was complicated. Although in the differential diagnosis the first probability is an intracranial tumour, it is necessary also to consider a random occurrence of a number of isolated pathologies, which are not primarily mutually linked. Ultrasound examination of both eyeballs excluded the presence of superficial or deep drusen papillas as the possible cause of the image of edema of the papilla or atypical defects of the visual field. Although atrophy of the optic nerve could be the result of contusion of the eyeball in the past, neither the subjective deterioration of CVA in the eye with atrophy of the optic nerve persisting for only one week nor the finding of edema of the papilla in the other eye corresponded to this. Good CVA in both eyes did not testify to hereditary atrophy of the optic nerve (Leber's hereditary atrophy or Kjer's optic atrophy), in addition it practically excludes toxic neuropathy (following the use of methanol). Although ischemic neuropathy would explain the defect in the lower half of the visual field respecting the horizontal meridian in the left eye, in addition to which the patient is a smoker, neither the age nor the overall good condition of the patient supports a conclusion of vascular etiology. The examination of visually evoked potentials performed at the beginning of the examination practically excluded the acute phase of neuritis of the optic nerve, and

the examination of the visual functions (colour and contrast sensitivity) also did not testify to neuritis of the demyelinating type. The negative personal anamnesis does not testify to the occurrence of symptomatically ongoing neuritis in the past. Although sub-clinically repeated ongoing attacks of neuritis are possible, without at least one clinical manifestation the attacks are improbable. Earlier concentrically constricted visual field is typical of infectious perineuritis, and the negative personal anamnesis also does not suggest this etiology. Infiltration or edema of the papilla in the left eye could be a symptom of excess pressure in the subarachnoid cavity. Unfortunately, the absence of measurement of effluent pressures upon lumbar puncture prevented any assessment of the influence of intracranial hypertension, including the idiopathic form. The finding of defects in the visual field of both eyes indicated the possibility of a chiasmatic lesion. The character of the bilateral defects in the lower quadrants of the visual field could correspond to craniopharyngioma, however, the MRI image was negative. The examination of aquaporin antibodies was negative, which together with the clinical picture excludes the possibility of neuromyelitis optica (Devic's disease). The presence of oligoclonal bands typical of multiple sclerosis (MS) was not demonstrated.

A diagnostic shift was brought about by the examination of the level of hypophyseal hormones, in which hyperprolactinaemia was repeatedly demonstrated. The subsequently targeted MRI with contrast confirmed hypophyseal microadenoma. With regard to its size, however, this cannot cause the pressure lesion of the visual pathway (additionally upward pressure on the uncrossed fibres), and as a result the present defects of the perimeter in our patient cannot be explained by means of this pathology. Furthermore, it is improbable that microadenoma would cause intracranial hypertension. The presence of this lesion therefore appears to be a chance finding.

Following the administration of acetazolamide (Diluran) in a dose of 1-1/2-1/2 tablets during hospitalisation, our pati-

ent's clinical condition improved which could be a manifestation of the regression of intracranial hypertension. There was a progressive regression of edema of the papilla of the optic nerve in the left eye. However, the perimetric finding improved only slightly in both eyes. Although the extent of the scotomas was reduced, absolute scotomas remained present. The presence of an atrophic papilla is a manifestation of chronic damage and permanent changes to the optic nerve. Analysis of the RNFL using OCT demonstrated the presence of a pronounced depletion of nerve fibres in the region of the optic nerve. In the right eye the largest decrease in thickness of the RNFL is in the temporal region, which corresponds with the defects of the perimeter in the nasal part of the visual field. A similar situation exists in the left eye: reduction of the thickness of the RNFL around the optic nerve in the upper section corresponds with the defects in the lower temporal and mainly lower nasal quadrant (fig. 9). Pharmacological therapy of prolactinoma was successful in our patient, during treatment there was a reduction in the level of prolactin, which is in accordance with the available literature (1). Should conservative therapy of prolactinoma fail in the case of our patient, it is possible to consider a surgical intervention.

CONCLUSION

We concluded the case as pseudo-Foster Kennedy Syndrome, but the cause of the atypical finding remains unclear. For correct diagnosis of an image of Foster Kennedy Syndrome it is necessary to ensure close inter-disciplinary co-operation of an ophthalmologist, neurologist and endocrinologist. An irreplaceable role is played by modern display methods such as magnetic resonance imaging with a contrast substance. A negative native MRI image is not always necessarily sufficient. Today upon sampling of cerebrospinal fluid, effluent pressures should always be measured in order to assess the relations within the subarachnoid cavity, which is important for the final determination of the diagnosis.

LITERATURE

1. **Diblík, P., Dohnalová, P., Marek, J. et al.:** Oční nálezy u prolaktinomů. *Čes a Slov Oftal*, 56; 2000: 235–239.
2. **Gelwan, M.J., Seidman, M., Kuper-smith, M.J.:** Pseudopseudo- Foster Kennedy syndrome. *J Clin Neuroophthalmol*, 1988; 8(1): 49–52.
3. **Jamjoom, B.A., Sharab, M.A., Nasser, T.A. et al.:** Pseudotumor cerebri and prolactin secreting pituitary adenoma. Association or coincidence?. *Neurosciences (Riyadh)*, 2011; 15(3): 200-203.
4. **Jirásková, N.:** Idiopatická intrakraniální hypertenze (pseudotumor mozku). *Čes a Slov Oftal*, 56; 2000: 262–265.
5. **Kennedy, R.F.:** Retrobulbar neuritis as an exact diagnostic sign of certain tumors and abscesses in the frontal

- lobe. American Journal of the Medical Sciences, Thorofare, N.J., 1911; 142: 355-368.
6. **Kraus, H. a kol.:** Kompendium očního lékařství. Praha, Grada Publishing, 1997, 213–214.
 7. **Kršek, M.:** Hyperprolaktinémie a prolaktinomy. Interní medicína pro praxi, 2002; 11: 530–536.
 8. **Kumar, K.V.S.H., Gaur, S., Manoj, S. et al.:** Microprolactinoma with visual field defect: an unsuspected etiology. Indian J Endocrinol Metab, 2013; 17 (1): 122–124.
 9. **Kurz, J.:** Ophthalmoneurologická diagnostika. Praha, Státní zdravotnické nakladatelství, 1956, 805.
 10. **Lešták, J., Vladyková, J., Houšťava, L.:** Útlakové léze chiasmatické krajiny z pohledu oftalmologa. Čes a Slov Oftal, 51; 1995: 165–170.
 11. **Limaye, S.R., Adler, J.:** Pseudo-Foster Kennedy syndrome in a patient with anterior ischemic optic neuropathy and a nonbasal glioma. J Clin Neuroophthalmol, 1990; 10 (3): 188-192.
 12. **Otradovec, J.:** Klinická neurooftalmologie. Praha, Grada publishing, 2003, 176–179.
 13. **Otradovec, J.:** Oční příznaky hypofyzárních nádorů. Čes Oftal, 48; 1992: 450–463.
 14. **Stárka, L. (ed.).:** Endokrinologie – lékařské repetitorium, Praha, Triton, 2010, 76–82.
 15. **Torun, N., Sharpe, J.A.:** Pseudotumor cerebri mimicking Foster Kennedy syndrome. Neuro-ophthalmology, 1996; 16 (1): 55–57.
 16. **Vladyková, J.:** Některé neurooftalmologické aspekty při tumorech chiasmatické krajiny. Čes Oftal, 43; 1987: 26–30.
 17. **Weiss, V., Marek, J.:** Hyperprolaktinémie. Doporučené postupy pro praktické lékaře, Česká lékařská společnost JEP, Praha, 2001: 1–6.